This is a digital copy of a book that was preserved for generations on library shelves before it was carefully scanned by Google as part of a project to make the world's books discoverable online.

It has survived long enough for the copyright to expire and the book to enter the public domain. A public domain book is one that was never subject to copyright or whose legal copyright term has expired. Whether a book is in the public domain may vary country to country. Public domain books are our gateways to the past, representing a wealth of history, culture and knowledge that's often difficult to discover.

Marks, notations and other marginalia present in the original volume will appear in this file - a reminder of this book's long journey from the publisher to a library and finally to you.

Usage guidelines

Google is proud to partner with libraries to digitize public domain materials and make them widely accessible. Public domain books belong to the public and we are merely their custodians. Nevertheless, this work is expensive, so in order to keep providing this resource, we have taken steps to prevent abuse by commercial parties, including placing technical restrictions on automated querying.

We also ask that you:

+ *Make non-commercial use of the files* We designed Google Book Search for use by individuals, and we request that you use these files for personal, non-commercial purposes.
+ *Refrain from automated querying* Do not send automated queries of any sort to Google's system: If you are conducting research on machine translation, optical character recognition or other areas where access to a large amount of text is helpful, please contact us. We encourage the use of public domain materials for these purposes and may be able to help.
+ *Maintain attribution* The Google "watermark" you see on each file is essential for informing people about this project and helping them find additional materials through Google Book Search. Please do not remove it.
+ *Keep it legal* Whatever your use, remember that you are responsible for ensuring that what you are doing is legal. Do not assume that just because we believe a book is in the public domain for users in the United States, that the work is also in the public domain for users in other countries. Whether a book is still in copyright varies from country to country, and we can't offer guidance on whether any specific use of any specific book is allowed. Please do not assume that a book's appearance in Google Book Search means it can be used in any manner anywhere in the world. Copyright infringement liability can be quite severe.

About Google Book Search

Google's mission is to organize the world's information and to make it universally accessible and useful. Google Book Search helps readers discover the world's books while helping authors and publishers reach new audiences. You can search through the full text of this book on the web at `http://books.google.com/`

B 3 9015 00215 623 3
University of Michigan – BUHR

Digitized by Google



THE GIFT OF

Society

Digitized by Google

610.5
R89
M52t

Digitized by Google

Digitized by Google

Digitized by Google

Digitized by Google

TRANSACTIONS

OF THE

MEDICO-CHIRURGICAL SOCIETY OF GLASGOW.

VOLUME II.

SESSIONS 1897-98, 1898-99.

EDITED BY

WILLIAM R. JACK, M.D.,
EDITORIAL SECRETARY TO THE SOCIETY.

GLASGOW:
ALEX. MACDOUGALL, 68 MITCHELL STREET.
1900.

Digitized by Google

GLASGOW:
PRINTED BY ALEX. MACDOUGALL.

Digitized by Google

LIST OF ILLUSTRATIONS.

—o—

	PAGE
Spastic Paraplegia,	52
Do. do.,	53
Micro-photograph of Glio-myxoma of Brain, *To face*	68
Do. do. do., ,,	68
Sites of Trephining for Tapping the Lateral Cerebral Ventricle,	79
Case of Myxœdema—Before Treatment,	128
Do. do., After Treatment,	129
Spinal Curvature and Congenital Osseous Deformities,	157
Do., showing Displacement of Heart to Right,	158
Skiagram showing Absence of Radius and Thumb,	159
Chronic Cardiac Disease Treated by the Schott Method (Diagrams),	168-174
Case of Cerebellar Abscess, Sites of Trephining in,	208
Do. do., at Time of Operation,	209
Do. do., after Recovery,	211
Nævoid Tumour of the Intestine Enclosed in a Double Intussusception,	216
Do. do., do.,	218
Do. do., do.,	219
Hypertrophy of Finger-nail,	253
Frontal Sinusitis,	302
Do.,	303
Chronic Prepatellar Bursitis,	322
Do. do.,	323
Thrombosis of Sigmoid Sinus,	330
Double Club Foot with Club Hand—Before Operation,	343
Do. do., After Operation,	344

Digitized by Google

OFFICE-BEARERS FOR SESSION 1897-98.

President, ... DR. GEO. S. MIDDLETON.

SECTION OF MEDICINE.

Vice-President, ... DR. ALEX. NAPIER.

Councillors, ... DR. MAITLAND RAMSAY AND DR. JOHN LOVE.

Secretary, ... DR. HINSHELWOOD.

SECTION OF SURGERY.

Vice-President, ... DR. NEWMAN.

Councillors, ... DR. JOHN BARLOW AND DR. ROBERT KENNEDY.

Secretary, ... DR. J. H. NICOLL.

SECTION OF PATHOLOGY.

Vice-President, ... DR. WALKER DOWNIE.

Councillors, ... DR. RUTHERFURD AND DR. W. K. HUNTER.

Secretary, ... DR. R. M. BUCHANAN.

SECTION OF OBSTETRICS.

Vice-President, ... DR. GEO. HALKET.

Councillors, ... DR. EDGAR AND DR. J. M. MUNRO KERR.

Secretary, ... DR. BALFOUR MARSHALL.

Treasurer, ... MR. HENRY E. CLARK.

General Secretary, ... DR. C. O. HAWTHORNE.

Digitized by Google

OFFICE-BEARERS FOR SESSION 1898-99.

President, ... DR. GEO. S. MIDDLETON.

SECTION OF MEDICINE.

Vice-President, ... DR. W. G. DUN.

Councillors, ... DR. JOHN LOVE AND DR. R. BARCLAY NESS.

Secretary, ... DR. HINSHELWOOD.

SECTION OF SURGERY.

Vice-President, ... DR. JOHN BARLOW.

Councillors, ... DR. ROBERT KENNEDY AND DR. RUTHERFURD.

Secretary, ... DR. J. H. NICOLL.

SECTION OF PATHOLOGY.

Vice-President, ... DR. WALKER DOWNIE.

Councillors, ... DR. WORKMAN AND DR. J. H. TEACHER.

Secretary, ... DR. R. M. BUCHANAN.

SECTION OF OBSTETRICS.

Vice-President, ... DR. GEORGE HALKET.

Councillors, . . DR. J. M. MUNRO KERR AND DR. J. K. KELLY.

Secretary, ... DR. BALFOUR MARSHALL.

Treasurer, ... MR. HENRY E. CLARK.

Editorial Secretary, ... DR. W. R. JACK.

General Secretary, ... DR. W. K. HUNTER.

Digitized by Google

Digitized by Google

TRANSACTIONS

OF THE

GLASGOW MEDICO-CHIRURGICAL SOCIETY.

—o—

SESSION 1897-98.

—o—

MEETING I.—1ST OCTOBER, 1897.

The President, DR. G. S. MIDDLETON, *in the Chair.*

SOME OBSERVATIONS ON THE DIFFICULTIES OF DIAGNOSIS IN ABDOMINAL DISEASE, WITH BRIEF ACCOUNTS OF ILLUSTRATIVE CASES.

BY DR. MIDDLETON.

GENTLEMEN,—My first duty is to thank you for the honour you have conferred on me in electing me President of this Society. When I look back upon the men who have, within my own recollection, occupied this chair, I feel considerable diffidence in taking it to-night. I do so, however, in the full confidence that the kindly feeling which has placed me here will be continued to me during my term of office, and will help me in the discharge of the duties of the chair, to the successful conduct of which no effort will be wanting on my own part.

One of your President's first duties—prescribed or sanctioned by use and wont—is to inaugurate his term of office with something in the form of an address. In selecting as the

Digitized by Google

subject of my remarks to-night the difficulties of diagnosis in abdominal disease, I have been guided chiefly by the fact that many cases have recently occurred in my wards which forcibly raised this question, but also by the belief that the question is one of great general interest. There is, indeed, a consensus of opinion in the profession that diseases of the abdomen are among the most difficult of diagnosis, especially in the case of tumours. Every now and again in general practice, and very frequently in hospital wards, abdominal cases are met with, the diagnosis of which remains for months, or even for ever, quite obscure.

The difficulties that we meet with may be divided into three groups:—

1. Difficulties arising on the part of the patient. It is often impossible to obtain a correct history of a case from the patient being ignorant, unobservant, or forgetful. We are very liable to be misled in this way, and I do not see that this source of fallacy can be altogether obviated. All we can do is to carefully cross-examine the patient, and weigh his credibility as well as we can.

2. Difficulties arising on the part of the physician. These are mainly of two kinds, either defective examination or an incorrect appreciation of some particular sign or symptom. I can recall many cases in which I have made these mistakes.

The most common and also the most striking example of defective examination that I can give you is that arising from failure to make a digital examination of the rectum, generally omitted from the fact that there are no signs suggestive of disease there, or, perhaps more frequently, because the signs that ought to suggest pelvic mischief are misinterpreted. I cannot insist too strongly on this point. Mistakes on my own part in the past have made me now make a rectal exploration a part of the routine examination of every obscure abdominal case. Within the past month I have seen several cases where this had not been done, and where the examination detected a hitherto unsuspected pelvic tumour, at once throwing light on the nature of the case.

So, also, mistakes frequently occur through failure to make *personal* examination of the alvine evacuations, &c.; through trusting to the reports of those in charge we may miss valuable aid which the discovery of blood, pus, &c., would give. Again, a case may present difficulties insuperable unless an examination is made under chloroform. The more we realise the necessity for thorough examination of all cases, the less frequent will be the errors arising from this cause.

Digitized by Google

3. The main difficulties, however, lie in the limitations that are imposed by nature on our means of examining the abdominal viscera, and in the nature of the abdominal contents themselves.

When we remember the various contents of the abdomen, it is not surprising that their diseases are often obscure. Of the solid glandular organs met with there is none whose functions are fully known to us, and only one whose secretion is presented to us in a pure state for examination. While the physiological functions of the kidney are fairly well established, and its pathological states are generally well known, the same can be said of none of the other solid viscera. The hollow viscera, the peritoneal cavity with its various pouches, the mesenteries, and the omentum, all at times give rise to trouble in diagnosis, partly because they are so much in juxtaposition with each other and with the solid organs, and partly because of the mobility of the various portions of the alimentary canal. Think, for example, of the various positions in which the pylorus may be found—to right or left of the middle line, above or below the level of the umbilicus. I am often met with the statement that a tumour under examination cannot be pyloric because of its position, when a wider knowledge of what is met with at *post-mortem* examinations would have prevented such an objection being raised. The same is true of all parts of the intestinal tract, the extent to which displacements may occur being very remarkable, and frequently illustrated in the cases of the appendix vermiformis and of the transverse colon.

Physical examination of the abdomen is all but limited to palpation and percussion, and, while much may be learned by these, a consideration of the facts above noted readily accounts for the difficulties met with in physical diagnosis.

In many cases we have to trust much to the patient's account of his illness, which, as we have already seen, is often unsatisfactory, but which, even when given correctly in all its details, is often most misleading. A symptom, for example, that is most commonly enquired for is pain. The more I see of abdominal diseases, the less trust I can put in this symptom as a help in diagnosis. We are all familiar with the varieties of pain described as characteristic, say, of peritonitis, of gall-stone, &c., but do we all recognise as fully the fact that we may have these conditions present without pain at all, or with pain referred to some distant part? Are we all aware, for example, that we may have a ruptured bowel, with escape of the intestinal contents into the peritoneum and secondary

Digitized by Google

peritonitis without pain, even though life has been maintained (with full consciousness) for hours or days? Some of the cases that I am to narrate to-night illustrate the little reliance that is to be placed on this symptom.

Apart, then, from our general knowledge of the typical features of the various visceral diseases, our diagnosis of the nature and seat of an obscure abdominal affection must depend upon our acquaintance with what one may call the vagaries of these disorders, and it is only from the records of cases whose diagnosis has been completed by operation or by *post-mortem* examination that such an acquaintance can be obtained. To illustrate all these vagaries in one paper is impossible; the varieties of appendicitis alone could not be discussed in such a space. Believing, however, that concrete examples of mistakes in diagnosis teach us more than abstract discussions of the difficulties, I would now ask your attention while I record a few of the cases that have puzzled me. In going over the material at my disposal for this purpose, I have had to make a selection, and I shall confine myself to-night to two classes of cases. I shall endeavour to lay them before you just as they struck us at the bedside, and then to show how the *post-mortem* examinations revealed conditions hitherto more or less unsuspected.

The three cases that I wish to bring before your notice first illustrate a not infrequent source of confusion, viz., that arising from the symptoms and physical signs leading to an erroneous conclusion that either a chief part, or the whole, of the disease is thoracic. There is nothing new in what I am directing attention to; but, while various special volumes on abdominal diseases have emphasised such occurrences, I do not think that their frequency and importance are sufficiently recognised in text-books and by the profession generally.

The first two of these cases are examples of the most common variety, viz., the simulation of pleural effusion.

CASE I.—*Purulent peritonitis—Large subhepatic abscess simulating pleural effusion—Collections of pus in pelvic cavity and in right and left iliac regions—Pus in gall-bladder—Pus in Fallopian tubes.*

A woman, 45 years of age, was admitted into my ward on 6th January, 1897, complaining of general weakness, sickness, vomiting, and diarrhœa. She stated that her illness had begun six weeks before with sudden pains in the abdomen, quickly

Digitized by Google

associated with vomiting and diarrhœa. The pain in a couple of days was "unbearable," and the vomiting was so urgent that "nothing would lie on her stomach." All the symptoms had abated under treatment.

Such was the statement of the case by the patient, who looked very ill. The cheeks and brow presented a brownish colour, but there was no pigmentation in the buccal mucous membrane or elsewhere abnormally, the skin generally and the lips being decidedly anæmic. She said she had lost a great deal of flesh, but she did not show great emaciation.

The abdomen was tympanitic all over, and some gurgling could be felt and heard on palpation, which elicited slight general tenderness. The hepatic dulness was normal, as also was the splenic. The abdomen was noted to be otherwise quite normal.

The percussion note in front of the right lung was of a somewhat dull tympanitic quality, and the respiratory murmur was rather weaker than on the left side. Behind, the percussion note on the right side was relatively dull from the angle of the scapula downwards, and the respiratory murmur was weaker than on the left side, while the vocal resonance was stronger, and the vocal fremitus about equal on the two sides. There were no râles anywhere; she said she had had no cough or difficulty of breathing, but speaking evidently caused her to be very short of breath.

Her general condition was bad. The pulse numbered over 130, and was small and easily compressible. The respirations numbered from 22 to 30. The temperature, on admission, was 99·6°, and it tended to vary from that to about 101°.

Two days later it was learned from the husband that the illness had begun with pain over the lower ribs on the right side, and that at a later date the pain had passed down into the abdomen; and also that she had had a slight cough, with a somewhat white tenacious spit. The diarrhœa of the onset had been easily controlled by medicine, but had again recurred a fortnight before admission, and evacuations had been passed in bed without notice. She had lost flesh greatly.

The case puzzled me. I had no personal evidence of abdominal disease, and the only abdominal symptom was diarrhœa. The oscillation of the temperatures rather suggested enteric, but there were no spots, the stools were not characteristic, and the abdomen was not distended. A rectal examination also failed to throw any light on the case.

Taking everything into account, it seemed that the most probable cause of her condition was something in the right

Digitized by Google

pleural cavity, probably an encysted empyema. On 9th January, therefore, an exploration of that cavity was made with trocar and cannula, but absolutely nothing came away, and I was as much in the dark as ever.

On 10th January, a letter was received from Dr. Blackwood, who kindly wrote giving us information as to her previous condition. On 1st December, 1896, he saw her suffering from sickness, abdominal pain, fever, and constipation. Enemata failed to give relief to the bowels, and tympanites came on about 13th December. On 15th December she had a severe rigor, after which the temperature, formerly about 102°, rose to over 104°. Under treatment the dangerous symptoms passed off about the 19th December, and up to the end of the month she improved still further, the tympanites disappearing. During January the temperature had risen two or three degrees every evening, and the bowels had become loose.

Dr. Blackwood regarded the case as one of peritonitis, having carefully excluded enteric fever.

Repeated examinations of the abdomen failed to detect anything abnormal except an indefinite sense of resistance on deep palpation above Poupart's ligament on the right side.

This patient showed no attempt at improvement. The temperatures ranged from 99° to 101° up to the 17th January, but after that date they were practically normal. Diarrhœa persisted, but vomiting was only occasional. On 9th January œdema was noted in the arms about the elbows, and it gradually affected both arms and both legs, but was never very excessive, and was always greater in the arms than in the legs. The urine contained but a trace of albumen, but it always deposited some black crystals of melanin or pyrocatechin, and was very acid. She was free from delirium up to the morning of her death, which took place on 22nd January.

I went to the *post-mortem* examination with no better diagnosis than that she had died of septic poisoning arising from some cause unknown.

The lungs and pleural cavities were found to be normal, but the abdomen was the seat of a purulent peritonitis. The intestines were firmly matted together and to the omentum, and there were several collections of pus. The largest was situated under the liver, but there were several foci of pus, especially in the right and left iliac regions and in the pelvis. The gall-bladder was greatly distended with pus and bile, and six small stones were found in the common bile-duct. There was no abscess within the liver, and no opening connecting

Digitized by Google

the interior of the gall-bladder with the subhepatic abscess. The uterine and vaginal walls were normal in appearance, but both Fallopian tubes were impervious to a bristle passed from the uterine cavity, and in their outer ends collections of pus were found. The appendix vermiformis was adherent, but there was no pus about it.

Now, even with the aid of the *post-mortem* examination, it is not clear where the disease originated. It may have commenced as a suppuration set up in the gall-bladder by the presence of stones, but in that case it is difficult to account for the other facts in the absence of any direct connection between the cavity of the gall-bladder and the subhepatic abscess. It is much more probable, I think, that the primary suppuration took place in the Fallopian tubes, probably as the result of gonorrhœal infection, and that septic infection followed.

In this case, an incorrect statement of the facts on the part of the patient and her husband, and the misleading nature of the physical signs (absence of those of peritonitis) when she came under my care, led to an incorrect diagnosis of effusion in the pleural cavity.

CASE II.—*Tumour of the right suprarenal capsule simulating pleural effusion—Thrombus of inferior vena cava—Thrombi in both branches of the pulmonary artery.*

A miner, 41 years of age, was admitted on 13th March, 1895, complaining of cough and spit, pain in the right side, and occasional swelling of the legs and feet.

Since the New Year he had been feeling out of sorts, with pain across the lumbar region and some cough and spit. Four weeks prior to admission he took to bed, largely on account of a sharp pain in the right side, aggravated by coughing and deep inspiration and also by lying on the left side. He had lost flesh and colour, being emaciated and pallid, but without any pigmentation of the skin. There was slight pitting on pressure over the right foot.

There was apparently evidence of pleural effusion on the right side, which, just below the nipples, was larger by half an inch than the left, and dull up to the sixth dorsal vertebra, the respiratory murmur being lost over the dull area. Further evidence of this supposed effusion was found in the facts that the hepatic dulness reached nearly to the umbilicus, and that the cardiac dulness in its lower part seemed displaced to the left.

The temperatures were normal or subnormal, and for a week or more he seemed to improve, and the effusion seemed to be disappearing, as friction became audible all over the dull

Digitized by Google

area behind. But, curiously enough, the right side continued larger than the left (at level of nipples, 18 inches to 17 inches, and 3 inches below the nipples, 19 inches to 17½ inches), and the lower border of the hepatic dulness remained at the level of the umbilicus.

The question of empyema was raised by the fact that there was a localised bulging in the right lateral region, and an exploratory puncture was thought of, but decided against, as it was finally concluded that the evidence of effusion was defective, while the liver was clearly much enlarged.

By the beginning of April there was well marked œdema of the right leg, and to a less extent of the left, without any evidence of thrombosis in the veins. There was then also tenderness over the dull area in the right lateral region, and more distinct bulging. Emaciation increased with great rapidity. From 28th March the temperature had oscillated a little, from about normal to about 100°, the absolute maximum recorded being 100·8° on 2nd April. From 4th April onwards, the temperatures were always subnormal. The abdomen became more swollen in the hepatic region, the right leg became very highly œdematous and painful, and the left more œdematous also. He died on 7th April. The course of the case gave rise to a diagnosis of malignant disease, probably of the liver, and involving the right pleura secondarily.

The examination after death found both lungs firmly adherent to the chest wall by old fibrous bands, and highly œdematous. On laying open the pulmonary artery in both lungs large adherent pale-yellow granular thrombi were found, perfectly occluding the lumina of several of their large branches. The vena cava superior was normal, as was also the heart, which was free from thrombi.

The stomach was greatly dilated, and contained a large quantity of dark coffee-ground fluid. Its mucous membrane was normal. The liver was pushed forwards and downwards, but did not seem to be greatly enlarged (50 oz.) On turning upwards its under surface a very large tumour was discovered, occupying the region of the right kidney. The posterior portion of the under surface of the liver was found to be adherent to the upper end of the tumour. Upon dissection the whole inferior vena cava was found to be occluded by thrombus, and the vessel was greatly distended thereby, so as to resemble a sausage. The thrombus extended into the left renal vein, and into the iliacs and femorals on both sides, but was evidently much older in the right femoral vein; the saphenous veins on both sides were also involved.

Digitized by Google

On removing the tumour, which was the size of a child's head, somewhat quadrate in shape, it was found to be situated between the lower surface of the liver and the upper end of the right kidney—*i.e.*, in the situation of the right suprarenal capsule. Both kidneys were quite healthy, and the left suprarenal capsule was normal. On cutting into the tumour, it was found to consist of rounded areas of yellowish, somewhat caseous, and broken-down-like tissue, interspersed with hæmorrhagic areas. It was kept for further dissection, but has unfortunately been mislaid, so that no further examination has been made.

Here, again, we find that a suspected pleural effusion did not exist; and that an apparent pleural friction had been caused, no doubt, by friction between the upper end of the tumour and the lower surface of the liver before the two became adherent. But another error in diagnosis was made, for there was no enlargement of the liver. That organ had been rotated on its long axis by the pressure of the tumour, so as to be depressed, and to give rise to the impression that it was much enlarged.

It is also worth noting that I failed to give due weight to his statement, that lying on his left side increased his pain. The pain of a pleurisy is increased by lying on the affected side; while the pain caused by an enlarged liver is generally increased by lying on the left side. This feature of his pain, therefore, should have made me suspect that the seat of the pain was below the diaphragm.

The third case is of a much more uncommon kind, the subdiaphragmatic disease having given rise to an erroneous diagnosis of pleuro-pneumonia and pericarditis.

CASE III.—*Perforation of latent gastric ulcer with subdiaphragmatic abscess simulating pleuro-pneumonia and pericarditis—Diaphragmatic pleurisy—Pelvic abscess.*

On 18th November, 1895, there was admitted to my female ward a domestic servant, 17 years of age, sent in by Dr. M'Pherson, Cambuslang, as "suffering from peritonitis and pleuro-pneumonia, the cause of the peritonitis being rather obscure." With this diagnosis I entirely concurred. The abdomen was distended, especially below and to the right of the umbilicus. There was tenderness in the epigastric, hypogastric, and umbilical areas, the epigastric and umbilical being most tender. There was impairment of the percussion note in the direction of dulness in the hypogastric and iliac regions, while quite a drum-like note was obtained over the rest of the

Digitized by Google

abdomen, especially in the epigastrium. The abdominal wall was nowhere absolutely rigid, but it was relaxed only in the flanks and in the epigastrium. Nothing was discovered on palpation, except that steady pressure tended to relieve the pain, which was no longer very acute. Over almost the lower half of the left lung behind there was relative dulness on percussion, with marked increase of vocal resonance, tubularity of the respiratory murmur, and a crepitus regarded as partly intra-pulmonary, though probably in part friction; in the left lateral region there was very coarse pleural friction, and only a very little intra-pulmonary râle; while over the lower part of the lung in front the signs were less marked.

The temperature was 103° F.; the pulse 122, regular and of rather high tension; and the respirations numbered 36 per minute, and were not very shallow. The face was flushed and anxious looking. Enquiry into the history did not discover any sufficient cause for her very serious condition.

Up till 10th November she had been in her usual health, that of an anæmic girl suffering from irregular menstruation. On that date she had a sudden sharp pain in the left side of short duration. She then remained well till the evening of 15th November, when the same kind of pain recurred in the left side, relieved by removing her stays.

On 16th November she was suddenly seized with severe pain in the upper part of the abdomen and in the left side.[1] She had to go to bed at once, and could scarcely breathe on account of pain.

[1] Dr. Peter A. Laird, who was then acting as assistant to Dr. M'Pherson, was good enough, some ten days later, to send me a note of his observations on this case, and it will be seen that his account differs considerably from that of the patient. "She had always been healthy up till 10th November, when she complained of an attack of acute pain in the belly, which, however, quickly passed off after a dose of castor oil, without leaving any symptoms behind. Although very anæmic, she was always able for her work, and is said to have never previously complained of indigestion or any pain about the stomach. From 10th November till the evening of the 15th November she was doing her work as usual. On the 15th November she had eaten a considerable amount of shortbread and other pastries (home made), and in the evening was suddenly seized with acute pain, which began in the left side and gradually extended over the whole abdomen. There does not appear to have been any collapse produced. Hot poultices were applied and castor oil administered. On this occasion the oil was vomited, and retching continued at intervals, usually most severe shortly after nourishment had been swallowed. More aperient medicine was administered on several occasions between the 15th November and the 17th November, but up till that date there had been no passage, even of flatus, and the vomiting still continued. The pain in the belly was somewhat spasmodic; that in the side was more constant.

"I was sent for on the morning of the 17th November, and found her

Digitized by Google

She had had to lie on her back with the knees drawn up. Poultices and turpentine fomentations gave her great relief. She had vomited repeatedly with much retching, the vomit consisting of curdled milk and bile. The bowels had not moved for several days till the day before admission, when there had been two motions under the influence of purgative medicines and five enemata.

The patient was evidently extremely ill. Nothing could be discovered to account for the apparent simultaneous involvement of the peritoneum, the pleura, and the lung. On the day after admission, and on the succeeding days, she had frequent loose yellow motions; but no spots were ever seen, and the diagnosis of enteric was never seriously entertained.

On 21st November it was noted that the *facies Hippocratica* was becoming more marked, and there were increasing signs of mischief in the right iliac region, dulness, and sense of resistance extending now to above the level of the umbilicus, while on the left side the sense of resistance was limited to an area extending for 2 inches only above Poupart's ligament. No complaint was made of pain on examining the abdomen, but she had had 40 minims of laudanum in the preceding sixteen or eighteen hours. There had been no vomiting. On the same date, while the signs of left basal pleuro-pneumonia persisted, I detected some dulness at the right base and a very extreme enlargement of the cardiac dulness, which reached almost to the left sterno-clavicular articulation, somewhat to the right of the middle line at the level of the fifth costal cartilage, and well to the left of the nipple line in the left lateral region, where it merged in the lateral dulness 1 inch above the level of the left nipple. The cardiac impulse

with a temperature of nearly 103° F. There was well-marked general and uniform distension of the abdomen. On light pressure there was very little tenderness; but on deep pressure the patient complained of pain, especially in the lower part of the belly. No induration could be felt in any part, and on percussion a tympanitic note was got over the whole abdomen. The abdominal respiratory movements were normal. The patient could extend her legs fully without any discomfort, and seemed to feel no inconvenience from the pressure of the bedclothes.

"There was nothing abnormal found about the heart, except the excited action resulting from the constitutional disturbance.

"Over the site of the continuous pain on the left side (*i. e.*, on a level with the base of the left lung) the breathing was harsh, and the respiratory murmur seemed prolonged. In addition there was an occasional crepitus heard, and at times the rasping nature of the sound suggested friction. Several large enemata were given, but no satisfactory motion was passed, and there was no diminution of the tympanites.

"On the 18th November the general symptoms had somewhat improved, but otherwise her condition was practically the same."

Digitized by Google

was felt from the first to the fifth left intercostal space, without apparent loss of strength in the normal situation of the apex. The sounds were sharper at the base than at the apex, and over the manubrium there was a suspicion of pericardial friction near a spot where, on admission, Dr. Howat had detected a rough systolic murmur of very limited distribution (which I had failed to corroborate).

The temperature varied generally between 102° F. and 103° F., seldom falling as low as the one, and only twice reaching above the other. There were no rigors or profuse sweatings.

The case was regarded as almost certainly a perityphlitis or appendicitis, with left pleuro-pneumonia, and with probably pericarditis, the whole suggesting some septic poison affecting chiefly the serous membranes. As the abdominal condition seemed the more urgent, she was transferred to a surgical ward. There, the evidences of thoracic disease being very marked, while the abdominal ones seemed to diminish, and her general condition being very bad, no operation was performed. The diarrhœa continued, the weakness increased, and she gradually sank and died on 25th November, the temperature having reached 104·4° shortly before the end.

The *post-mortem* examination revealed an unexpected condition of affairs. On opening the abdomen a large quantity of pus escaped from a cavity bounded above by the diaphragm and below by liver, stomach, pancreas, &c. This large abscess was due to the perforation of an ulcer in the anterior wall of the stomach, 1 inch below the lesser curvature, and a little nearer the pyloric than the cardiac end. On the upper surface of the left lobe of the liver and on the corresponding diaphragmatic surface there was a thick layer of fibrino-purulent exudation.

In the right iliac fossa and in the pelvis another large collection of pus was met with. Careful examination failed to discover any connection between the two abscesses, and there was nothing abnormal about the uterus or its appendages. The cæcum and the appendix were healthy. The intestines generally were matted together by recent peritonitis, but were healthy throughout.

The pus contained streptococci and a bacillus whose identity was unknown.

The pericardium was normal, but contained about 6 ounces of clear serum. The heart was normal.

Both lungs were collapsed, the left much more than the right. Both were forced upwards by the bulging of the

Digitized by Google

diaphragm, and were firmly adherent to the diaphragm from recent pleurisy. The left lung was distinctly œdematous.

I think you will agree with me that this was a case the complete diagnosis of which was scarcely likely to have been made. I do not think that it ever occurred to me that the origin of the trouble might be found in the rupture of a gastric ulcer, but that explanation had presented itself to Dr. M'Pherson.

Careful enquiry made during life, and again after the results of the *post-mortem* examination were known, failed to discover any history of symptoms that might have been indicative of gastric ulcer. It may well, therefore, be described as a case of latent ulcer, and I think we may infer from the history that the rupture took place in two stages, as it were—viz., first, on 10th November a slight oozing, sufficient to gradually set up some adhesions, and then, on 15th November, a more definite rupture leading to the large abscess which was found below the diaphragm.

Those of you who are interested in the diagnosis of subdiaphragmatic abscess caused by rupture of gastric ulcer will find the subject treated in a very interesting manner by Dr. Samuel Fenwick in his *Clinical Lectures on some Obscure Diseases of the Abdomen*, and you will there find that such an abscess frequently gives rise to signs suggestive of pleural effusion or of hydro-pneumo-thorax, the latter due to the escape of gas from the stomach. In this case, however, the signs never suggested a pleural effusion, but consolidation with dry pleurisy. Now, while the examination revealed recent adhesions between the pleural surfaces at the base of the lung and over the diaphragm, there was nothing there to cause the coarse friction so abundantly heard, and the collapsed condition of the lungs scarcely accounted for a tubular respiratory murmur. What we believed to have been pleural friction was in reality due to the rubbing of the roughened surfaces of the liver and the diaphragm, and I can account for the tubularity of the respiratory murmur only on the supposition that during life the lung condition must have resembled condensation from pressure, for there was certainly no pneumonic exudation.

Again, the heart and the pericardium practically were found in a normal state, and yet the signs during life were such as to raise the question of pericarditis with effusion. It is difficult to explain this. All that I can say is, that no doubt the physical signs we noted were due in some way to abnormal tension of the parts due to pressure from below the

Digitized by Google

diaphragm, and to displacement of the heart from the same cause—static and dynamic conditions the effects of which cannot be tested by the facts as observed at a *post-mortem* examination.

Other interesting points in this case are the occurrence of so much internal suppuration without rigors, profuse sweating, or marked oscillations of the temperature; the presence of an iliac and pelvic abscess without connection with the sub-diaphragmatic one, a metastasis which cannot be referred to absorption by the lymphatics, and scarcely even to septic poisoning, as it would appear that it was one of the early features of the case; the absence of collapse at the moment of rupture, and the duration of life after it, both no doubt due to adhesions having formed so as to limit the dispersion of the escaping contents of the stomach.

A point of minor interest is that this case illustrates the well-known fact that it is ulcers on the anterior wall of the stomach which are most likely to be latent, and which most commonly lead to rupture, the latter owing to the difficulty with which they form adhesions to the neighbouring parts.

Other varieties of thoracic disease are at times simulated by abdominal affections. Thus, I remember a case that was long treated as tubercular disease of the lung which proved, on *post-mortem* examination, to be a lung destroyed through the rupture into it of a perinephritic abscess through the diaphragm. Again, as I have already mentioned, Fenwick and others record cases of perigastric abscess giving rise to a mistaken diagnosis of hydro-pneumo-thorax, the gas escaping from the stomach into the abscess giving a well-marked Hippocratic succussion.

There are, no doubt, other sources of confusion to which I have not adverted, but the above are sufficient to show that mistaken diagnoses of this nature are liable to be of not infrequent occurrence. Let us hope that to be forewarned is to be forearmed.

I must now, in a word, remind you of the converse of these cases—viz., the many instances in which thoracic affections are ushered in with symptoms suggestive of abdominal disease. Thus, in many cases of basal pneumonia and diaphragmatic pleurisy, the initial symptoms are pain referred to the abdomen, severe and persistent vomiting, and sometimes collapse—the classical features of a peritonitis. In these cases, however, as a rule the diagnosis is in doubt only for a day or two—till the physical signs are fully established. In

Digitized by Google

abdominal cases, however, the mistaken diagnosis may be adhered to for weeks or months, nothing occurring to lead to its correction.

The second difficulty that I wish to speak of is that of determining whether an abdominal tumour is malignant or not. This question often arises, and I venture to think that we have all made mistakes, both in saying that a tumour was malignant when it was not, and in saying that it was not when it really was. The two following cases will show how easily a mistaken diagnosis may be made.

CASE IV.—*Jaundice from gall-stones, with greatly thickened omentum simulating malignant disease of the liver, apparently confirmed by discovery of a pelvic tumour.*

A woman, 56 years of age, was admitted on 14th August, 1897, suffering from severe vomiting, jaundice, and weakness. The jaundice was considerable, but an almost more striking feature was the sunken state of the eyes and the anxious expression of the face.

The abdomen was greatly distended, but there was some doubt as to whether there was much fluid present in the peritoneal cavity. The liver seemed to be enlarged downwards. The upper border could be made out by percussion to lie in the sixth intercostal space in the nipple line, but percussion failed to demarcate the lower border. On deep palpation in the epigastrium a large solid mass was felt, which could be traced almost down to the umbilicus. Its surface could not be accurately felt, and no defined lower border could be made out. Repeated examinations led to the conclusion that this was probably liver, but the possibility of its being omental was entertained. No nodules could be felt anywhere. The spleen could not be felt, but splenic, cardiac, and hepatic dulnesses coalesced. The urine was highly bile-stained, scanty, and contained a little albumen and numerous hyaline and granular and epithelial casts. The heart was normal.

There was very constant vomiting; the vomited matter was not abundant, but it was grumous in appearance, and gave the blood reaction with guaiac—confirmed by the discovery of blood corpuscles by the microscope.

The history bore that about the end of June she began to feel discomfort after food; later she had actual pain, and a few days later she had vomiting. Loss of flesh then occurred. She could not say when the jaundice had been first noted.

Digitized by Google

There was no history of tippling, and nothing specially to suggest that we were dealing with cirrhosis of the liver. Careful inquiry failed to discover any history of hepatic colic. Though she had had pain in the epigastrium and about the liver, she had evidently never had a severe paroxysm. We therefore excluded gall-stones as a cause of her disease. The woman's age and her appearance suggested malignant disease as the cause, and this seemed to be confirmed by the presence of blood, though in small quantity, in the vomited matter.

On 17th August, as no motion of the bowels had taken place, and as only a little fluid could be injected into the bowel, a digital examination of the rectum was made, and a hard mass was felt in the pelvis, apparently lying between the rectum and the uterus, and almost completely occluding the rectum. The finger could discover no involvement of the mucous membrane of the rectum or of the vagina, but the impression left by the hardness of the mass and by the presence of a small hard nodule near it, was that I was dealing with a considerable tumour, and that a malignant one.

No more complete proof of the malignant nature of the disease could have been looked for.

Vomiting persisted. She was unable to take any food. The bowels never moved. The urine averaged about 18 oz. daily. The temperature was generally normal or subnormal, the lowest record being 97·4° (on admission) and the highest 99·2°—the only occasion on which it reached above 98·6°. She was very sleepless, for which she got some opium. Gradually sinking, she died on 21st August.

Examination of the body showed that there was no enlargement of the liver. What we had taken for liver was omentum, which was drawn upwards and much thickened, so as to be mistaken for the liver when the body was opened. It felt to the hand like a hard cake. On section it cut with a feeling of density, but the naked eye could discover no malignant disease in it, and this was later confirmed by the microscope.

The jaundice was due to gall-stones in the common duct. The gall-bladder was contracted, its walls much thickened, and its cavity full of large gall-stones. It was adherent to the liver. Gall-stone, therefore, was the cause of the jaundice.

The pelvic tumour resolved itself into inflammatory thickening, with enlargement of some of the glands. The lower portion of the bowel, the uterus and vagina, and the bladder were matted together by old adhesions. The bowel was found to be twisted together into an **S** shape, and so compressed by thickened tissues and so distorted as to

Digitized by Google

be all but completely obstructed. Microscopic examination proved what the naked-eye could not tell—that there was no malignant disease. There was no history of any old-standing pelvic mischief. She had had eleven children and two miscarriages, but she gave no account of any uterine or other disease of the pelvic organs. The source of the pelvic disease is therefore still unknown.

CASE V.—*Gall-stones with enlargement of gall-bladder and of liver—Obstruction of pylorus with dilatation of the stomach—Simulation of malignant disease.*

A man, 55 years of age, was admitted on 14th October, 1893, complaining of pain in the right side, jaundice, cough, and shortness of breath.

The pain in the right side began three months before admission, had never entirely ceased, and had occurred at times in severe paroxysms of a few minutes' duration. The pain had never shot down towards the umbilicus, but it did shoot through to his back.

Jaundice was only of ten days' duration, and was deepening in colour.

There had been obstinate vomiting for three weeks.

For three years he had suffered from winter cough and shortness of breath, and these were troubling him considerably at the time of his admission.

He had been losing flesh for a year.

The liver proved to be considerably enlarged. In the nipple line the upper border of dulness was found 1 inch below the nipple, while palpation discovered the lower border 7 inches below that. In the parasternal line the measurement was 8 inches, there being a projection from below the border of the liver of a pyriform shape, and with the feeling of an enlarged gall-bladder. The examination elicited considerable tenderness over the whole hepatic area, but especially over this enlarged gall-bladder. There was no irregularity of the surface of the liver. The spleen was not enlarged. There was well-marked evidence of dilated stomach, and on several occasions sarcinæ were found in the coffee-grounds vomit and in the washings of the stomach.

The patient showed no tendency to improvement. He could not take food; the bowels were very constipated. The temperature only twice reached above 99·2°, and the maximum was 100°.

He was gradually losing ground, when, on 30th October, he became suddenly comatose, and died.

Digitized by Google

This was regarded as a case of malignant disease. While the history of pain was quite consistent with a hepatic colic, and the distended gall-bladder suggested an impacted gall-stone, other facts tended to the diagnosis above named. Jaundice had not immediately followed on the painful attacks, but was only of ten days' duration; the liver was much enlarged; and there was a greatly distended stomach. This latter fact at once suggested a primary cancer of the pylorus, and the occasional coffee-grounds appearance of the vomit tended to support that view, even though the presence of blood-corpuscles was not recognised by the microscope.

The examination of the body failed to discover any malignant disease anywhere.

The stomach was greatly distended owing to a tight stricture of the pylorus, due to the latter being dragged up and adherent to the gall-bladder, and not to any disease of its mucous membrane. The omentum, the duodenum, and the pylorus were all adherent to the gall-bladder, which was very tense. On strong compression of the gall-bladder, a fluid, apparently a mixture of bile and pus, flowed from the hepatic papilla in the duodenum. In the gall-bladder, two rounded stones about the size of small hazel-nuts were found, not facetted, and there was none impacted in the duct, and no others were found in the intestines. The walls of the gall-bladder were thickened and rigid, and its internal surface resembled that of an atheromatous aorta. The liver was enlarged, weighing 88 oz. The pancreas was normal. Nothing was found in the brain to account for the coma.

I presume that in this case the primary fact was the presence of gall-stones; that these had somehow set up irritation and suppuration in the gall-bladder; and that the inflammation had extended outwards, causing the adhesions that were so marked, and that led to the signs that supported the mistaken diagnosis. It is to be specially noted that there was no impacted gall-stone. The jaundice was due to constriction of the gall-ducts from the matting of the parts.

These, gentlemen, are the cases that I have selected as illustrative, and I would like to draw your attention to one feature common to them all—viz., the fact that without the *post-mortem* examination the diagnosis in every instance would still remain uncertain. I do not say that I made the most of the clinical facts at my disposal. It is quite probable that a critical survey of the detailed reports of the cases would show that in at least some of them I omitted to give proper

Digitized by Google

weight to some sign or symptom that I had observed, and which, perhaps, ought to have led me to a correct diagnosis. I bring the cases before you, however, as cases observed with much more detail than is generally possible in private practice; and I feel sure that many of you must be able to recall cases more or less like some of them, in which, however, you had not the advantage of permission to examine the body after death. I hope that records such as these may tend not only to throw some light on past obscure cases, but also, by showing what various pathological conditions may be met with, to be of some help in the diagnosis of cases that may yet come before you.

MEETING II.—5TH NOVEMBER, 1897.

The President, DR. G. S. MIDDLETON, *in the Chair.*

I.—CASES OF EXCISION OF MENINGO-ENCEPHALOCELE.

BY DR. NICOLL.

J. P., æt. 2 years, sent to me in August, 1896, by Dr. Gorman, of Rutherglen. The child, at that time æt. 10 months, had a pulsating sessile meningo-encephalocele measuring across 3 inches in one direction and 3½ inches in the other, and situated in the middle line near the vertex. This I excised in September, 1896. The specimen here shows a meningeal sac largely occupied by brain matter, the fluid having escaped. The child, as you see, fourteen months after operation, is in perfect health, and the aperture in the skull all but completely closed by bone.

L. F., æt. 1 year and 10 months, sent by Dr. Blakeley, of Kirkintilloch, in August, 1896. At that time the child, æt. 8 months, had a pulsating sessile meningo-encephalocele in the middle line below the posterior fontanelle, which measured 5 inches in circumference and 3¾ inches across. In August, 1896, I excised this. The specimen shows a meningeal sac partly occupied by brain matter, the fluid having escaped. The child, fourteen months after the operation, is in every way well, and, as you may see, the aperture in the skull is completely closed by bone.

Digitized by Google

In addition to these two cases of meningo-encephalocele, I have removed meningoceles or encephaloceles from four cases. Of these I hope to show several, if not all, to the Society at a future meeting.

The method of operating in all has been as follows:—By an elliptical incision, skin flaps are shaped and raised from the base. The base—or neck where the sac is pedunculated—is isolated, and then divided in such a way as to leave flaps of dura mater to cover the stump. The stump of brain matter is then divided, bleeding arrested, and the dura mater sutured. From the bony margins of the skull aperture, small portions of bone are separated by chisel or knife, and turned over on to the sutured dura mater. The skin flaps are then sutured.

This bone grafting secures, what these cases show, more or less perfect closure of the skull. The longitudinal sinus may give trouble. In the first case shown I had difficulty in avoiding it, and in a case which I hope to show the Society, I had to divide it.

II.—CASES OF SPINA BIFIDA TREATED BY OPEN OPERATION.

By DR. NICOLL.

It is not my purpose to-night to submit statistics on the comparative merits of open operation and injection. I have now treated a number of cases by open operation. Some of these I have already shown here and in other societies. To make the comparison of value, however, one must wait till the cases have been under observation for a considerable time, and I, therefore, do not yet submit a tabulated statement. From such experience as I have had, however, it appears to me that there can be no doubt whatever as to the absolute superiority of open operation over injection, both in the matter of mortality and as regards prospect of cure locally.

B. S., æt. 3 years, sent to me two years and three months ago by Dr. A. Sloan. The child had then a spina bifida in the lumbar region of the size of a small orange. At that date I excised the greater part of the sac after opening it, and dissecting off its interior several cords of nervous tissue, which I returned into the spinal canal.

The child, as you may see, is, two years and two months after operation, in perfect health, and the gap in the spinal canal firmly closed by what feels like tough fibrous tissue under a sound skin scar.

Digitized by Google

Baby H., æt. 2 years, was operated on by me at the Children's Hospital in July, 1896. At that time the child, æt. 8 months, had a spina bifida in the lower cervical region of the size of a hen's egg. This I excised, and it forms the specimen I have here.

The child was to have been here to-night, but unfortunately it has developed whooping-cough. I hope, however, to show it at a future meeting of the Society.

Specimen from the case of the child of a doctor in the West of Scotland. The patient had a spina bifida in the lower dorsal region which measured across the summit 7¾ inches by 6½ inches. This I excised in February, 1896. The child, now æt. 2 years and 7 months, is, one year and eight months after operation, in perfect health, the spinal gap being firmly closed by fibrous tissue and sound skin.

The specimen, as you may see, includes the greater part of the sac, with the ellipse of skin removed over the summit. A number of cords of nervous tissue were dissected from the interior of the sac and placed in the spinal canal.

In none of these cases is there any paralysis of legs, bladder, or bowel.

Method of operating in cases where there is much nerve tissue present.—In two cases operated on during the past six months (one of which, possibly both, I hope at a future meeting to show the Society), where nerve cords were large and numerous, I adopted the following plan in dealing with the sac:—

The operation in its early stages proceeded on the usual lines—(*a*) flaps of skin; (*b*) flaps of mesoblastic tissues (ligaments, fasciæ, and muscles; (*c*) isolation of the neck, or base, of the sac; (*d*) opening of the sac and inspection of interior. After that, in place of dissecting the nerve cords off the interior of the sac, with the risk of damage to them and subsequent paralysis, I simply cut the sac into ribbons by incisions running parallel with, and between, the nervous cords. The emptied and slashed sac was then placed in the spinal canal, the mesoblastic flaps sutured over it, and finally the skin flaps sutured over all.

In looking into the literature of the subject I find that Mayo Robson, of Leeds, makes reference to having in several cases *excised portions* of the sac which lay between nerve elements. In the writings of several authors also, particularly, so far as I have seen, of those of the French school, the meso-

Digitized by Google

blastic flaps are said to contain the elements of bone—derived from the rudimentary and undeveloped bases of the laminæ. In no case on which I have as yet operated have I been able to find or include such bony elements in the flaps; nor in any of my cases has bone developed in the flaps, even after the lapse of several years. The case of B. S. shown to-night, two years and two months after operation, illustrates this, as well as cases I have formerly shown.

Dr. T. K. Dalziel, after congratulating Dr. Nicoll on his results, in which he had had a success certainly not to be anticipated ten years ago, stated that he believed with Dr. Nicoll that the open method was the safest and the most scientific. He asked what amount of nerve strands was present in the case of spina bifida (to which Dr. Nicoll replied that one or two small strands were found; these were dissected and dropped back). He thought Dr. Nicoll's later method preferable to attempted dissection. He himself had not employed it, but had sometimes, after puncturing it, dropped back the whole sac.

Mr. H. E. Clark said that, whether treated by injection or left to nature, many of these cases were quite hopeless, and bound to terminate fatally. Morton's method was sometimes successful, but very often it was not so. In the open operation one could distinguish between nerve strands and other tissues. The case of spina bifida shown was not perfectly satisfactory, as cases seated low down often underwent spontaneous cure. He had experienced difficulty in those cases where the skin was very much thinned and inseparable from the wall of the sac, so that flaps could not be formed. He was struck with the cases of encephalocele, one in particular being seated farther forward than is usual. He noted that brain matter as well as membrane had been removed, which encouraged one to more active measures in connection with the removal of cerebral tumours. He asked what Dr. Nicoll would do in the difficult cases to which he had referred.

Dr. Nicoll said that he recalled two operations by injection done in the Western Infirmary on the same day some years ago. One died on the table; the other ten minutes after removal. In reply to an observation of Mr. Clark's, he stated that no bony formation had taken place in his cases of spina bifida, although he had been careful to raise mesoblastic flaps, according to the French teaching. In the different cases of spina bifida to which Mr. Clark had referred, he took away

Digitized by Google

the skin along with the dome of the sac. The encephalocele mentioned by Mr. Clark was seated very far forward, and he had found it difficult to get it clear of the longitudinal sinus.

III.—CASE OF LIGATURE OF A CEREBRAL ARTERY.

By DR. NICOLL.

Mrs. S., æt. 62, was sent into the Western Infirmary by Dr. Bell Todd on 9th October, 1896.

History (as obtained from her two sons, her daughter, and a neighbour).—Always excitable, and latterly much addicted to drink. One month previously had suddenly in her house turned giddy and, after staggering for a few minutes, fallen unconscious. Was thought to be drunk, and was placed in bed. For several days, however, remained more or less unconscious. Then gradually recovered, but for three weeks was in a dazed and stupid condition, and "could not talk properly" (aphasia?). After that appeared quite well for a week.

Four days before admittance, while going out, she again suddenly turned giddy, and was found by a neighbour leaning against the wall of the entry. She was with difficulty got into her house and put to bed—by that time nearly unconscious. For three days remained more or less unconscious, and on the fourth day an acute epileptiform seizure occurred very suddenly.

Dr. Bell Todd, who was hastily summoned, recognised the condition as one requiring immediate operation, and sent her at once into the Infirmary. Being on duty at the time in Professor Macewen's wards, I happened to see her on admittance.

Her condition was as follows:—Unconscious, but could be partially roused. Pupils equal, moderately dilated, and sluggish in reaction. No optic neuritis. At intervals of a few minutes there occurred violent epileptiform seizures. Each seizure began with a turning of the eyes and head to the right, followed by twitching of the right side of the head and neck. This was almost at once followed by violent twitching of the right arm and of the right lower limb. During the most severe seizures the left side of the body also became involved.

The head was shaved, and the patient was prepared for operation, which took place about an hour and a quarter after admittance.

Digitized by Google

Over the motor area I removed successive portions of the skull to the extent of about 5 square inches in all. A large clot lay on the surface of the brain, and there was also smart fresh hæmorrhage from the lower and anterior part of the exposed area. After removing the clot I tied the middle meningeal in the dura mater. The hæmorrhage still continuing I removed a further portion of bone in the direction from which it proceeded, and exposed a cavity in the cerebral cortex of about the size of a pigeon's egg. This was lined by greyish shreddy material resembling partially bleached old blood-clot. From the lower side of this cavity an artery was spouting across the cavity. This I tied with a fine ligature.

All the bone removed was replaced with the exception of the part immediately over the cavity. The wound healed rapidly, the bone uniting firmly. For several weeks she remained stupid and irritable, and markedly aphasic. She ultimately was dismissed well.

At present she is well in every way except in so far as that there is a gap in the skull of about 1 inch square, and near it an area of skull, corresponding with that removed in the operation, which is irregular and flattened.

During the past year she has been deserted by her family, and has been drinking and working as a charwoman by turns. Most unfortunately she has spent the past two days in a state of intoxication; and when, after tracing her through two model lodging-houses, I found her to-day, she absolutely declined to implement her promise and appear here to-night.

Remarks.—The artery tied appeared to be the ascending frontal branch of the middle cerebral. As to the nature of the cavity into which it was bleeding, it seems an open question whether (*a*) it may have been an aneurysm which partially ruptured on the occasion of her first attack of giddiness, and finally ruptured a month later, or (*b*) was produced by tearing of the brain by hæmorrhage from the ruptured artery. In either case the shreddy material on its walls appeared of much earlier date than the large clot on the brain surface, suggesting a date of origin probably contemporaneous with the date of the attack of giddiness one month before admittance. The large soft black clot on the brain surface, on the other hand, seemed of recent origin, and in all likelihood originated at the time of the second attack of giddiness four days before admittance. Whatever the exact explanation, the rupture would seem to have been spontaneous. No evidence of fracture could be found, nor did the shaven

Digitized by Google

scalp reveal any bruising. The history also bears out this opinion.

Dr. Newman asked if the artery was atheromatous, *Mr. Clark* if the bone had been removed by trephine, and *Dr. Middleton* whether there was anything to show that the cavity contained old clot, such as the presence of blood crystals. Dr. Newman added that it was difficult to say what was the nature of the lower clot. He asked if there were no indication of syphilis, aneurysm, or atheroma in the exposed vessels.

Dr. Todd had seen the patient in the first emergency, and sent her into the Western Infirmary. She then had epileptiform fits at intervals of about twenty minutes.

Dr. Nicoll, in reply, stated that he had found no evidence of syphilis, aneurysm, or atheroma.

IV.—TWO CASES OF RESECTION OF MEDIAN NERVE FOR FALSE NEUROMA.

BY DR. NICOLL.

L. C., æt. 9, sent to me by Dr. J. Wylie Nicol. In July, 1896, the patient fell and cut her right wrist on a piece of glass. The wound healed readily. During the autumn months of 1896, however, her mother noticed that she frequently dropped things held in the right hand, and in December her teacher sent her home from school with the report that she could not hold her pen. In January she came into Dr. Nicol's hands, and was by him kindly sent to me as an interesting case requiring operation.

At that time there was a keloid punctured scar of about 1¼ inch situated transversely just above the annular ligament. There was complete anæsthesia in the whole median area in the hand. There was some muscular atrophy in the thenar eminence. The index and middle fingers were covered with recurrent bullæ with serous contents, and there was marked atrophy of the pulp of the index finger. In March I cut down and dissected the nerve free from the surrounding scar. It presented a dense swelling of irregular shape, pigmented blue, and of the size of a horse-bean.

No improvement followed, and, therefore, nine weeks later, I resected 1¼ inch of the nerve, including the neuroma, and sutured the ends.

The specimen is the portion excised. The neuroma is purely fibrous tissue, and the pigmentation is due to particles

Digitized by Google

of dirt with which the nerve had been tattooed at the time of the injury.

At this date, five months after resection, *sensation* is perfect, and the atrophy of the pulp of the index finger has completely disappeared. The *muscular atrophy*, however, has as yet improved but little despite the constant use of battery and massage.

J. H., æt. 39, sent to me in August, 1896, by Dr. Macdonald, of Kilmarnock. In May, 1896, he had wounded himself with a chisel just above the annular ligament of the left wrist. The wound healed well, but after the dressings were dispensed with he discovered anæsthesia of the forefinger. Shortly after this he for the first time consulted Dr. Macdonald, who sent him to me.

His condition at that time was as follows:—Anæsthesia, apparently complete, of the whole median area in the hand; bullæ on index and middle fingers; marked atrophy of thenar muscles.

On 16th August I exposed the nerve, and found a small dense fibrous mass in which the trunk lost itself and became indefinable. This fibrous mass was not very clearly demarcated from the surrounding scar in the tissues. Having dissected it clear, I removed it by dividing the trunk above and below and suturing the ends.

The specimen measures 1½ inch. The patient healed by primary intention. *Sensation*, which began to return during the second week, was soon perfect, and *muscular atrophy* gradually disappeared.

At present the muscles are in perfect condition, there are no bullæ on the fingers, and sensation is fairly good. During the past two months, however, sensation has slightly but perceptibly deteriorated.

Remarks.—These two cases form a contrast illustrating the striking lack of uniformity frequently observed in the results of operations for the restoration of nerve function. The cases were almost identical, and the treatment similar, yet in the one there is early and apparently permanent perfect restoration of sensory and trophic functions, while motor function is restored very slowly and but imperfectly, and in the other motor, sensory and trophic functions are rapidly and completely restored, and remain perfect for nearly a year, when sensation shows evidence of distinct deterioration.

Many factors contribute to this lack of certainty in result,

Digitized by Google

Certain of these—viz., the nature of the affection which produced the loss of function, the time which has elapsed between the loss of function and the operation, the mode of healing of the operation wound, the condition of the scar left, and the treatment applied to the muscles—are well enough known, and need not be here discussed.

Dr. Kennedy said that the results of resection depended on the time elapsing between the accident and the operation. In the first case there had been a year's interval, and after so long a time there was no hope of restoring the muscles, although sensation should return very soon if the wound remained aseptic. The second case was unusual, the muscular power being re-established, and sensation disappearing for a second time after its re-establishment. He thought this was due to the contraction of the cicatrix giving rise to pressure on the nerve.

Mr. Clark emphasised the necessity of suture of the nerve at the time of the injury. This was often neglected, so that healing took place with impaired function of the nerve. It should be possible to suture either the median or ulnar nerve, if completely, or even if incompletely, cut across. In the case of the hand it was especially necessary to secure primary suture both of nerves and tendons, as secondary resection and suture were always followed by a certain amount of failure. In Dr. Nicoll's second case there was tenderness over the palm of the hand, probably due to a secondary neuritis, which might account for the recurring loss of sensation.

V.—CASES OF EXCISION OF THE APPENDIX.

By DR. NICOLL.

Cases of excision of the vermiform appendix are now comparatively common, and it almost requires an apology on the part of a surgeon who brings such cases before the Society. While this is so, there are certain points, both in diagnosis and treatment, on which the records of cases as they occur may be expected to shed fuller light.

The following are the briefest notes of some cases which have passed through my hands during the last six months, the specimens from which I have here:—

CASE I.—Mrs. L., æt. 40, seen in consultation with Dr. Provan on 18th June, at that time between four and five months pregnant. Had been ill for two weeks with the usual symptoms

Digitized by Google

of acute appendicitis—temperatue, 103°; acute abdominal pain, chiefly in cæcal region; abdomen hard, with fulness and acute tenderness in cæcal region; rigors, vomiting, constipation, emaciation, and copious sweating.

Patient was on that day conveyed in an ambulance car to the M'Alpine Home. Enemata and milk diet for two days relieved the patient greatly, and the temperature sank to normal. The fulness and tenderness in the cæcal region remained.

Five days after first seeing the patient I operated, and found an abscess containing about an ounce of pus surrounding an appendix with an ulcerated perforation. The abscess was emptied, and the appendix, which forms the specimen, excised.

The patient made a perfect recovery, and Dr. Provan is now in daily expectation of her confinement.

CASE II.—Miss F., æt. 19, seen in consultation with Drs. West and Hanson on 15th July. Patient had been ill for two weeks with somewhat vague symptoms of acute abdominal mischief, but had for a few days presented evidence of abscess developing in the cæcal region.

On that day she was removed to the M'Alpine Home. For two days enemata and milk diet were given, and the temperature fell from 103° to 99·5°.

Four days after admittance I operated, and found a partially gangrenous appendix enclosed in an abscess cavity of irregular shape, very thick walls, and with thin fœtid pus. The proximal part of the excised appendix forms the specimen. The distal part was blackish-grey, soft and gangrenous, and adherent to the wall of the colon just above the caput cæcum. This gangrenous part I picked off the wall of the colon in small pieces. The abscess cavity was packed with gauze, and the parietal wound partially sutured.

For a week the patient did only fairly well, the pulse being rapid and sickness recurring nearly every day. On the eighth day after operation the packing was (for the third time) removed, and was found soaked with fæces which, after withdrawal of the packing, continued to flow from the wound. The cavity was packed with gauze moistened with carbolic solution. On the following day I removed all sutures, opened up the cavity, and found a perforation of the colon at the former site of adhesion of the gangrenous appendix. This I closed by two rows of Lembert suture, and again packed the cavity.

The patient made a perfect recovery, and is now well.

Digitized by Google

CASE III.—Miss H., æt. 22, seen on 6th August in consultation with Dr. Hanson, with temperature of 104°, and all the local symptoms of acute appendicitis.

The following day I operated, and found the appendix free from abscess, adhesions, or perforation. It was of bright red colour, rough on the surface from exudation, and tumid and tense, thus contrasting strongly with the bluish, shining, soft neighbouring coils of intestine. I excised it, and it forms the specimen. Its walls are thick from inflammatory exudation.

The patient made a rapid and complete recovery.

CASE IV.—Master C., æt. 15, seen in consultation with Dr. Edward M'Millan on 10th March, suffering from symptoms of subacute appendicitis. The temperature was 100·5°, and local resistance and tenderness were considerable. He had had at least two similar attacks previously.

On 30th April, in the Crosshill Nursing Home, I operated. The appendix was more or less cyst-like, being constricted towards its base. It was redder than the neighbouring intestine, and was embedded in soft adhesions. It was excised, and the patient made a rapid recovery. The specimen shows thickening of the walls by inflammatory exudation and dilatation of the distal parts by mucous contents, produced by a stricture of the lumen about half an inch from the junction of the cæcum.

Remarks.—The facts of these cases illustrate the great difficulty in deciding whether a given case be perforative, and therefore urgently requiring operative interference within at most a few days, or simply "catarrhal" or obstructive, and to be left as such with comparative safety permanently or for a time. Case III, for instance, had when seen a higher temperature and more acute symptoms than Cases I and II, though these were perforative and suppurative, while Case III was merely catarrhal.

Cases I and II also, under milk diet and enemata, improved so much as to make perforation seem improbable; and yet, when operated on, they present not only perforation but abscess. The same thing has been noted in cases previously brought before the Society by myself and others.

Case II illustrates what Treves and others have observed —that perforation of the cæcum and colon may, and does, result from *within* from dysenteric, catarrhal, tubercular, or malignant ulceration, but that it may also occur from *without*

Digitized by Google

by the ulceration produced by the presence of a diseased appendix or the abscess resulting.

In Case I the right ovary formed part of the abscess wall. Its presence in that situation was revealed by the fact that protruding from its surface were two small cysts of the size of horse-beans. The ovary itself was, like the other parts of the abscess wall, covered by adherent fibrino-purulent material. These two small cysts were, on the other hand, quite free from all such coverings, and projected into the abscess cavity as glistening, tense, grape-like bodies.

CASE V.—Mr. B., æt. 38, had had for five months more or less pain in the right side of the abdomen and right groin, which at times became so severe as to lay him up for one or two days. In June, 1897, his right kidney had been exposed and explored for stone through a lumbar incision by another surgeon. In September he consulted me with symptoms of pain and tenderness in the cæcal region, which at times became acute and was accompanied by sickness and feverishness. The urine was normal. No enlargement of the kidney could be detected, but on bimanual examination *per rectum* a distinct mass could be felt in the neighbourhood of M'Burney's point.

On 19th September I operated and removed the appendix, which forms the specimen. It is notable for its very large size, forming, when removed, a cystic structure of ovoid shape, 5½ inches in length and 3 inches in circumference. Its contents were fæcal-stained mucus, and the neck presents a lumen too fine to admit an ordinary surgical probe. When exposed it presented evidence of inflammation, being red, and roughened, and partially enclosed in soft adhesions.

The patient has made a perfect recovery from the operation, and is quite free from pain.

In connection with this case may be placed the two following:—

CASE VI.—Mr. S., patient of Dr. Peden, consulted me a month ago with these symptoms of a years' duration:—Pain in right lumbar and iliac regions, extending into groin and scrotum. This is more or less constant, but at times becomes severe and accompanied by tendency to sickness. The urine contains a small quantity of albumen and a considerable amount of pus. No enlargement of the kidney can be detected, but there is tenderness in the renal region. The case is probably one of pyelitis of right kidney, and the patient is to

Digitized by Google

return in a few weeks for cystoscopic inspection of the ureteral orifices and probably subsequent nephrotomy.

The case is mentioned here on account of the fact that his symptoms led, five months ago, to the removal of his appendix by a surgeon whom he consulted.

CASE VII.—Mr. G. was seen by me, in consultation with Dr. G. Marshall, on 25th January, 1896. The previous evening he had taken a dose of laxative medicine. In the morning he felt sick and suffered from gripes, but had no motion. On reaching his office he had a severe attack of abdominal pain, which ended in faintness. During the forenoon he had several attempts at evacuation of the bowel, but without effect. In the afternoon he took a cab home and sent for Dr. Marshall.

When, at Dr. Marshall's request, I saw him late in the evening his temperature was 100°, and his pulse rapid but good. There was little tendency to sickness. The whole abdomen was distended and painful. The pain was most marked, however, in the right iliac region, where there was resistance and great tenderness on palpation over M'Burney's point. Large enemata had no effect, but opium relieved his pain.

The following day the general abdominal pain was less, but the local resistance and tenderness in the region of the appendix greater. Further enemata moved the bowels freely, and on the night of that day he felt better, the temperature was normal, and the local tenderness no greater. On the next day, in the morning he felt still better, and the local tenderness was diminishing. The urine to the naked eye appeared normal.

On the evening of the third day of his illness he passed the small uric acid calculus which forms the specimen, and gradually regained his normal healthy condition. At no time had he had any symptoms of urinary disturbance.

Remarks.—These three cases illustrate a difficulty in diagnosis by no means uncommon. Case V presented symptoms, caused by serious disease in the appendix, which led a competent surgeon to explore the right kidney for stone. Case VI presented symptoms which appear very clearly due to renal or urethral disease, but which led a competent surgeon to remove the appendix. Case VII presented symptoms, caused by urethral calculus, which might very well have led to the diagnosis and treatment of appendicitis.

Digitized by Google

VI.—COMPLETE ATROPHY OF THE DELTOID, WITH VICARIOUS RESTORATION OF FUNCTION.

BY DR. R. KENNEDY.

The patient, a man, aged 22 years, presented complete atrophy of the right deltoid, the result of injury to the circumflex nerve from subcoracoid dislocation of the shoulder-joint two and a half years previously. Eleven months elapsed after the dislocation before he was able to elevate his arm at the shoulder-joint to any appreciable degree. At the end of that time he was able to return to his work, and from that time, probably from the regular exercise secured at his work, the range of movement and power at the shoulder-joint rapidly improved, and now only careful inspection detects any abnormality.

At present the atrophy of the right deltoid is complete. There is no response to electrical stimuli; the acromion, coracoid, and head of the humerus are all prominent, and felt to be covered merely by skin and subcutaneous tissue; and there is no contraction of muscular tissue in the region of the deltoid when the patient raises his arm. Despite this condition, the patient can elevate his right arm as easily and completely as his left. Nearly all the movements performed by the deltoid are restored, but there are one or two, such as that performed in throwing a stone, which are defective.

The vicarious factors supplying the function of the deltoid are three in number:—

1. Hypertrophy of the supraspinatus. This is shown by a a striking tension and bulging over the supraspinous fossa during elevation of the arm. The extent to which this muscle elevates the arm was ascertained, by taking angular measurements between the scapula and arm, to be 30°.

2. Muscles rotating the scapula. This accounts for a considerable extent of the restoration of function. In complete elevation of the arm, the inferior angle of the scapula is in front of the lateral line, and the bone is placed almost horizontally. On the sound side during elevation of the arm to the maximum the inferior angle of the scapula travels through a distance of 2½ in., while on the affected side the distance travelled is 4½ in. This extreme rotation of the scapula is effected by the cervical portion of the trapezius and by the lower slips of the serratus magnus. Both are greatly hypertrophied, the former standing out in contraction as a bulky mass.

Digitized by Google

3. Torsion and curvature of the vertebral column. The application of the two former factors raises the arm almost, but not quite, to the normal height; but the arm is capable of being raised to the normal height, and this is effected by a slight torsion of the vertebral column to the right and lateral curvature to the left.

VII.—COMBINATION STETHOSCOPE.

BY DR. JONES.

Dr. Jones showed a combination stethoscope of his design, consisting of stethoscope, reflecting mirror, and ear speculum.

MEETING III.—26TH NOVEMBER, 1897.

The President, DR. G. S. MIDDLETON, *in the Chair.*

I.—REPEATED OPERATION FOR RECURRENT SARCOMA.

BY DR. DALZIEL.

Dr. Dalziel showed a patient on whom seven operations had been performed for sarcoma originating in the orbit and giving rise to secondary growths in the cheek, over the mastoid, in the upper lip, in the superior maxilla, and in the pterygoid processes. The whole of the orbital contents had been removed four years previously for primary sarcoma of the lachrymal gland. The bone of the outer and lower margins of the orbit had been removed and the part packed with chloride of zinc paste, which led to a further slough of tissue round the sphenoidal fissure. Three months later a nodule appeared in the cheek, and this was removed in a V-shaped portion of the entire tissues of the cheek. Six months later a growth appeared over the mastoid, and was freely removed together with the surface of that bone, to which it was adherent. A year afterwards a nodule appeared in the upper lip. Subsequently the left superior maxilla was removed with the soft palate and the pterygoid processes. Since the last operation, fifteen months ago, the patient had enjoyed excellent

Digitized by Google

health, and though suffering from the absence of the superior maxilla and an aperture in the cheek equal to a halfpenny in size, due to the removal of the soft parts, she yet leads a very useful and comfortable life. After the lapse of another six months, it was proposed to introduce an artificial patch of cheek. All the sarcomatous tissue removed was found to be of the small round-celled variety. There was no evidence of visceral lesions.

II.—SPECIMENS.

A. BY DR. WORKMAN.

1. *A specimen from a case of primary malignant disease of the liver.*—William H., a labourer, aged 51, admitted 18th August, 1897. The disease was diagnosed as cirrhosis of the liver.

Summary of Clinical History.—The patient complained of swelling of abdomen and legs of three months' duration.

Personal History.—Has always been a healthy man. No history of syphilis.

Present Illness.—The first thing noticed was swelling of the legs. He got cold through working in a draught. The abdomen began to swell, and he had pain in the back at the same time. No jaundice. No pain in the abdomen. He lost flesh considerably during the course of his illness. No definite history of alcoholism.

Condition on Admission.—Patient emaciated. The skin has a peculiar bronzed appearance; it appears in parts dark brown or almost olive-green. The mucous membrane of the lips is free from pigment. Heart and lungs normal. Abdomen is considerably distended, the umbilicus retracted. Percussion gives a dull note in both flanks, clear in front. A distinct thrill is obtained on combining palpation with percussion. No definite enlargement of the liver can be made out. The spleen is enlarged. The temperature is normal.

The abdomen was tapped on 17th September and 128 oz. of fluid withdrawn; again, on the 22nd, when 8 oz. were withdrawn; and on the 27th, when 338 oz. were taken away. The patient died on 3rd November, 1897, at 10 P.M.

Extract from Post-mortem Reports.—"The body is that of a greatly emaciated man, subcutaneous adipose tissue being almost entirely absent. *Post-mortem* rigidity passing off. The heart, except for some brown atrophy of its muscular tissue, and the absence of fat from its surface, presents healthy characters; the endocardium is bile-stained. The commencing

Digitized by Google

aorta is atheromatous, and shows calcareous patches. The lungs are somewhat œdematous.

"*Abdomen.*—On opening this cavity a large amount of bile-stained ascitic fluid escapes. The omentum and mesentery contain but little fat. The stomach is of fair size and normal in position, its mucous membrane is congested, but the organ is otherwise healthy. The duodenum is also quite healthy. The gall-bladder is large, and contains bile of light yellow colour, which escapes easily, on pressure, into the duodenum.

"The liver seems to be retracted upwards, and lies almost entirely above the level of the border of the ribs and costal cartilages. It is rough and nodulated in form, and very dense in consistence. A distinct tumour mass is found on its upper surface, closely adherent to the diaphragm, and about the size of a hen's egg. On cutting through this into the liver, the organ is seen to be infiltrated by tumour tissue, especially its left lobe. The right lobe also shows a few foci, and is distinctly the seat of a coarse or multilobular cirrhosis.

"The portal vein, as it passes to the liver, is greatly dilated and thrombosed, the thrombus being evidently in part tumour-formation within the vessel.

"The spleen is much enlarged and of very firm consistence, probably due to passive hyperæmia from obstruction of the portal vein. The hepatic and cystic ducts, as well as the common bile duct, are patent.

"The pancreas is atrophied and of firm consistence, but no tumour tissue can be found in it. The suprarenal bodies are healthy. The kidneys are congested, but otherwise they appear healthy. The intestine is carefully examined throughout, but except for moderate congestion it presents no abnormality. The urinary bladder is healthy; it contains deeply bile-stained urine.

"*Weights of Organs.*—Heart, 7½ oz.; right lung, 26 oz.; left lung, 18 oz.; liver, 51 oz.; spleen, 14 oz.; kidneys together, 10 oz."

From the tumour masses in the liver, and also from that in the portal vein, I prepared sections, after hardening in formol and then in alcohol, by embedding the tissue in celloidin. These I stained with Ehrlich's acid hæmatoxylin, and afterwards with a solution of acid fuchsin and picric acid, according to a method recommended by Van Gieson, and which I find very useful for demonstrating such tissues; then I cleared them with aniline oil, xylol, and pure xylol, and mounted them in canada balsam.

The sections show that the tumour consists of large epithe-

Digitized by Google

lioid cells with large oval nuclei; the cells are irregular in shape, and are arranged in columns and masses resembling gland structure.

The cells and nuclei of the masses in the liver itself are somewhat larger than those of the masses in the portal vein, but the arrangement is very similar.

In the liver the masses appear to compress and push to the side the ordinary lobular structures, and around and in the neighbourhood of them there appears to be great hyperplasia of the connective tissue of the portal areas, causing a very pronounced multilobular cirrhosis; in some parts there is also very considerable round-cell infiltration.

The masses in the dilated portal vein consist of rather smaller cells with smaller nuclei, the amount of connective tissue between the columns and masses is also less, so that here the tumour resembles a lympho-sarcoma. These masses come into very close relation to the vessel wall. No endothelium is to be seen separating them from the muscular coat of the vessel.

The masses in the liver itself have all the characters of an adeno-carcinoma, while the tumour tissue in the vein might be looked upon as an endothelioma taking origin from the lining wall of the vessel, or as a lympho-sarcoma bursting into it from the neighbouring connective tissue or the lymphatic glands in the fissure of the liver.

If the tumour is a primary cancer of the liver, it is hard to understand how it could make its way against the current and appear in the dilated vein outside the organ. If the tumour took origin either in the vein or in the tissues of the fissure, it is easy to understand how it would give rise to secondary nodules in the liver.

Along with the microscopic sections, Dr. Workman exhibited slices of the liver, which are preserved in glycerine and water, after fixing in formol and treating with alcohol and then with acetate of potash-glycerine. These retain very nearly the colour of the fresh organ, and show the structural appearances very beautifully to the naked eye.—(Royal Infirmary Pathological Reports, No. 1,751.)

Dr. Middleton asked what Dr. Workman meant by secondary cirrhosis.

Dr. Workman—A cirrhosis due to pressure and consequent interference with the functions of the organ—in other words, a proliferation of connective tissue due to the irritation caused by the tumour.

Digitized by Google

Dr. Middleton then said that the case recalled to him another, which had been diagnosed as a renal affection. Death had been supposed to be due to uræmia. A cirrhotic liver was discovered at the autopsy, and the portal vein was found to be occluded by an old plug.

2. *A specimen from a case of secondary malignant disease of the liver.*—George G., aged 65, who was occupied as a pitheadsman, admitted to the hospital on the 13th September, 1897, suffering from pain in the abdomen of ten weeks' duration. Patient had been a soldier, and was in South Africa; had not suffered from malaria, dysentery, syphilis, nor excessive alcoholism.

History of Illness.—Symptoms began ten weeks ago with pain in the abdomen, and he noticed that his abdomen was becoming swollen. He vomited everything he took; this vomiting lasted for six weeks; on several occasions he vomited blood. He had diarrhœa, the bowels acting five or six times daily; he frequently had blood in the motions, the blood being bright red in colour. The pain in his abdomen became worse, and patient stated that it had a gnawing character. Two weeks before admission his legs became swollen; he was short of breath, and could only lie on his right side; he had gradually been losing flesh.

Condition on Admission.—The patient was thin and emaciated; great œdema of legs; no jaundice; lungs normal; heart normal, there was a suspicion of a V.S. murmur heard over the apex. The abdomen was greatly distended, the liver was greatly enlarged and easily felt, as it extended fully 2 inches below the costal margin. The liver dulness in the nipple line was 8 inches broad. Spleen was enlarged and palpable. A small round mass could be felt about half an inch above and to the left of the umbilicus. There was some ascites. The temperature was normal; the urine acid, and it contained urates, but no albumen. On the 20th September, 1897, there was no improvement in the patient's condition. The liver was greatly enlarged, probably from malignant disease. No jaundice observed. The night before patient had become somewhat delirious. There was gnawing pain in the abdomen, aggravated by pressure; blood was several times observed in the motions. The patient died on the 23rd September, 1897.

Extract from Post-mortem Journal of 24th September, 1897.—"The body was that of a well-developed, but greatly emaciated man, with extreme general anasarca; the abdomen

Digitized by Google

especially contained a large amount of fluid, which was blood-stained. There was some jaundice, especially of the face. In the thorax the pericardium was seen to contain a small quantity of serum. The pleuræ also contained some fluid. The heart presented fairly healthy characters. The lungs were of small bulk, their bases being collapsed, while the anterior and upper portions were slightly emphysematous at the margins. The bronchi revealed signs of old and of recent bronchitis. On opening the abdomen the liver was found to be enormously enlarged; it extended considerably below the umbilicus. The enlarged organ was the seat of very extensive secondary cancer, being fully four times the usual size. On cutting into it the right lobe was found to consist almost entirely of cancerous tissue undergoing necrosis. The stomach was a little congested, and there was *post-mortem* digestion of its mucous membrane. The duodenum and the pancreas were healthy, as was also the spleen. There was a cancerous mass in the sigmoid flexure of the colon, annular in form, and almost surrounding the lumen of the bowel. The mucous surface was ulcerated, and the tumour presented all the characters of a columnar-celled epithelioma. The rectum and the bladder were healthy. The kidneys were slightly congested, but otherwise appeared healthy.

"*Weights of the Organs.*—Heart, 8½ oz.; right lung, 16½ oz.; left lung, 18 oz.; liver, 222 oz.; spleen, 2½ oz.; kidneys together, 9 oz."

A portion of the greatly enlarged liver had been fixed in formol, and then treated with alcohol, and afterwards with glycerine and acetate of potash. It is cut into two slices and mounted in glycerine and water for the museum; by this means the appearance of the fresh organ has been fairly preserved, and the large pale masses of malignant tissue, which in their centres are undergoing caseous degeneration, are very well shown, while around them the much congested liver tissue is seen retaining almost the natural colours. By this process bile-stained parts take on a greener tone than is natural in the fresh tissues.

Portions of the liver were cut by the celloidin method, and stained according to Van Gieson. These show well the columnar-celled type of the cancer, the cells being arranged so that they closely resemble the epithelium of the tubules of the intestine. The granular character of the degenerating tissue is also well seen, and around the tumour masses there has been considerable inflammatory change, which is evidenced by the presence of groups and masses of leucocytes. There

Digitized by Google

has also been much hyperplasia of the connective tissue, especially of the portal areas, so that a rather coarse cirrhosis is present.

In this case the portal vein was not involved in the disease, and both the naked eye and the microscopic appearances are very different from those of the last case (primary malignant disease). In this the disease is most distinctly a columnar-celled cancer secondary to the disease in the sigmoid flexure of the colon.—(Royal Infirmary Pathological Reports, No. 1,717.)

Dr. Adamson asked if the pancreas was involved.

Dr. Workman replied in the negative.

3. *A specimen from a case of hypertrophic cirrhosis of the liver.*—Robert S., shipmaster, aged 39, was admitted to the Royal Infirmary on the 11th October, 1897, and supposed to be suffering from malignant disease of the liver.

Summary of Clinical History.—The patient was admitted in a condition of extreme restlessness and semi-unconsciousness, with intense jaundice, œdema of the legs; breathing semi-stertorous, with a peculiar odour of the breath, and the pulse hardish and rapid. The urine drawn off contained bile and albumen, specific gravity, 1012; urea, 1·4 per cent.

He had three fits, tonic and clonic, lasting from two to eight minutes. Temperature, 98·4°. On 13th October there was great hepatic enlargement of peculiar conformation. Projection downwards of the right lobe with depression in an angular direction from the middle line outwards and downwards. Jaundice not so deep as in obstruction. Urine passed in bed. Stools without bile. Bowels acted nineteeen times on the 12th October. Pilocarpine and hot baths were given, which were followed by relief temporarily, and even by some degree of mental coherence. Stated that jaundice had existed for a month, and pointed to a painful part midway between the umbilicus and the xyphoid cartilage and slightly to the right. No primary seat of malignant disease made out, no hiccough, and no vomiting. On the 15th of October the stools were still white. Patient becoming drowsy. The urine practically free from bile. Temperature, 100·6°. A large enema was given (there had been hiccough and vomiting) on the 14th October. The patient died at 11·20 A.M. on the 16th October, 1897. The *post-mortem* examination was made on the morning of the 17th October, 1897.

External Appearances.—A well-developed and well-nourished body, with extreme jaundice of the skin and conjunctivæ.

Digitized by Google

The pupils were contracted and equal. *Post-mortem* rigidity was pronounced. On opening the thorax the pericardium contained between two and three ounces of clear but deeply bile-stained serum. The heart was perfectly healthy in its characters, but the tissues were deeply bile-stained. The lungs were not adherent to the chest wall, and the pleuræ only contained a little bile-stained fluid. The lungs were slightly emphysematous along their anterior borders, but otherwise quite healthy. On opening the abdomen a very moderate ascites was found, not more than 1½ pint of fluid being present in the peritoneum, but this fluid was blood-stained and contained about two ounces of soft blood clot. This hæmorrhage appeared to be due to capillary extravasation, as there was very considerable congestion of the small veins behind the peritoneum and in the root of the mesentery. The stomach showed great passive hyperæmia of its mucous and submucous tissue; it contained a small quantity of fluid which lay in the cardiac end, while the rest of the organ was distended with gas. The mucous membrane of the cardiac end was greatly softened by *post-mortem* digestion. The spleen was enlarged and deeply congested. The pancreas was large and somewhat congested, while the adipose tissue in its neighbourhood, and to some extent also between the acini, showed patches of opaque yellow colour evidently due to fat necrosis. The liver was enormously enlarged and of firm consistence. Its surface and the cut surface, when section was made, had the appearance of yellow granite, this mottled appearance being evidently due to cirrhosis, which was chiefly of the monolobular variety. The surface was much smoother than that of the ordinary "hob-nailed" liver. The right lobe was much more hypertrophied than the left. The gall-bladder was of fair size, and contained a considerable quantity of brownish-yellow fluid bile which escaped readily, on pressure, into the duodenum by the papilla. The kidneys were large, deeply congested, and much stained by bile pigment; otherwise they appeared healthy. The intestinal mucous membrane was much congested; the jejunum and ileum contained some bile-stained material, but the fæces in the colon, which were very small in amount, were only of a pale yellow colour.

Weights of Organs.—Heart, 11 oz.; right lung, 26 oz.; liver, 153 oz.; spleen, 11 oz.; kidneys together, 20 oz.

Dr. Workman showed slices of the liver, mounted in glycerine and water, which had been fixed in formol, but these did not retain the natural colours, probably because they had been kept too short a time in the formol and the alcohol had acted

Digitized by Google

too strongly. Sections were exhibited under the microscopes which had been stained by Van Gieson's method; these showed well the great hyperplasia of the connective tissue in the portal areas, with very numerous and probably newly formed bile-ducts, in some of which inspissated bile might be seen. There was considerable fatty change in the cells of the lobules, especially in those of the outer zone, and in many parts the portal areas were infiltrated with leucocytes.

The study of the various forms of cirrhosis of the liver is of the greatest interest. The latest paper on the subject is the one by Dr. Herman Heineke in Ziegler's *Beiträge zur Pathologischen Anatomie*, vol. xxii, part 2, 1897. In this paper the author concludes that in addition to the forms of interstitial hepatitis due to obstruction of the ducts by gall-stones, tumours, &c., there is another form in which the great ducts are free, and which arises from a chronic inflammation of the medium sized and small ducts, with destruction of their epithelium, and with excessive growth of connective tissue in their neighbourhood. This form he calls "primary biliary cirrhosis," and he states that it is characterised by hypertrophy of the liver, swelling of the spleen, and comparative absence of ascites; the illness is accompanied by fever.

The case of Robert S. appears to me to have been one of this kind, as the small amount of fluid in the abdomen was very remarkable when considered along with the extreme disease of the liver and the enlargement of the spleen. Though much trust cannot be placed in the absence of a history of alcoholism, the appearance of the liver was so different from those cases in which alcoholism is usually found to be a cause that I am inclined to believe that this lesion has been produced in a different way.—(Royal Infirmary Pathological Reports, No. 1,733.)

Dr. Middleton said that he was not quite convinced that the case was not alcoholic. He noted that the fluid in the peritoneal cavity was blood-stained, and also that blood-clot was present. He would be interested to find out from Dr. Workman in what cases hæmorrhage might occur into the abdominal cavity. He recalled the case of a patient with ascites, who was twice tapped, the fluid in each case being hæmorrhagic. He seemed to be gradually sinking, but was ultimately discharged quite well. The speaker had concluded that there had been some temporary interference with the portal circulation, of such a nature as to be capable of removal.

Dr. Workman replied that in his case the condition of the

Digitized by Google

vessels was due to the obstruction to the portal circulation and the pressure on the vena cava produced by the enlarged liver. Hæmorrhage of this kind, which was caused by diapedesis, was rare in the abdomen.

B. BY DR. DALZIEL.

Dr. Dalziel showed a specimen of congenital cyst of the mesentery removed, together with a portion of intestine, from a child 3 years old.

The patient, D. B., æt. 3, was admitted to the Royal Hospital for Sick Children on 16th November, suffering from intestinal obstruction of six days' duration. Dr. W. G. Dun had advised early operation, but the parents refused consent, and only brought the patient to hospital when it seemed *in extremis.*

On admission the patient was pale, with drawn features and cold extremities. The abdomen was distended and tympanitic throughout. No tumour could be detected. Pulse was 126, small, and thready. Immediate laparotomy was performed, and a large cyst of the mesentery exposed, covered, however, by distended coils of intestine.

The cyst, originating in the mesentery close to the bowel, had bulged on either side of it, and embraced a section of the bowel about 2½ inches in length. The tumour had rotated three complete turns, and so twisted the intestine as to lead to complete obstruction. Twenty ounces of fluid rich in cholesterine crystals was withdrawn from the cyst, which, with the included intestine, was removed, a Murphy's button being used to unite the divided intestine. The bowels moved a few hours after the operation, and so far the child had made good progress towards recovery, there being no abdominal distension.

The cyst was shown, and also some of the fluid contents.

Dr. Dalziel discussed the etiology of the cyst, which seemed to be rather unusual, in so far as it contained enormous quantities of cholesterine, had firm well-defined fibrous walls lined with endothelium, and had evidently originated in immediate contact with the intestine—about the middle of the jejunum. It did not seem to correspond with any of the usually described cysts—the blood cyst, serous or simple cyst—and the suggestion was advanced that it might be of the nature of a hydrocele, from the inclusion of a peritoneal fold during the development of the intestine.

Digitized by Google

Dr. Dun said that he had seen the case on the Saturday previous to operation, which took place early on Tuesday morning. He was told there had been no motion since the previous Wednesday. Large enemata were unsuccessful, as only a small quantity entered the bowel. He then passed the fluid in through a large gum-elastic catheter, by which more was introduced, but a large part of it returned stained with fæces. He advised removal to hospital, but the parents objected. The same treatment was carried out on the Monday, and on Tuesday morning the patient was sent into hospital. The abdomen was distended, but not tender, and no tumour could be made out. There was severe intermittent pain, and he had suspected volvulus. He referred to Frænzel's paper on mesenteric cysts, in which it is stated that out of ninety tumours of the mesentery, thirty were cystic. The author emphasises the symptoms of paroxysmal pain and constipation. The cyst may not be accessible to examination by the abdomen until after the constipation is relieved. No such condition is noticed in the paper as occurred in this case. The cholesterine cyst is not mentioned.

Dr. Workman had no personal experience of mesenteric cysts. It was remarkable that there was a peculiar tendency to twisting in all tumours attached to the bowel. He did not know why the twist should always be in the same direction.

Mr. H. E. Clark knew of a specimen in the museum of the Royal Infirmary which had been operated upon for obstruction. The tumour, which was fairly large, was not identified as a cyst until it was dissected out *post-mortem.*

Dr. J. H. Nicoll asked whether the bowel was washed out, and whether sutures were used in addition to the button. Supposing it to be an ordinary serous cyst, he suggested that the cholesterine might be explained by the presence of chyle in the intestine on the one hand, and fat in the mesentery on the other.

Dr. Dalziel replied that the cyst was situated about the middle of the small intestine. He thanked Mr. Clark for his reference, and stated that he had not washed out the obstructed bowel above, but had pushed back the intestinal contents and clamped the bowel above and below. He had had difficulty in uniting the dilated bowel above with the undilated bowel below. He had placed two rows of continuous fine silk sutures outside the button, invaginating the bowel upwards, and pulling its thick hypertrophied portion over the button.

Digitized by Google

C. BY DR. E. A. GIBSON.

Dr. E. A. Gibson showed a specimen of dermoid cyst of the ovary removed *per vaginam.*

Mrs. M'C., æt. 27. The patient began to menstruate at 16, and was married at 19. She has had three children, the youngest ten months ago. Instruments were used with the first and last delivery. No abortion. Menstruation always regular and normal. No leucorrhœa.

At last confinement she was a long time under $CHCl_3$, and the nurse told her that the doctor said there was an "obstruction," and had considerable difficulty in delivering her, having to put on the forceps four times. She asked the doctor during her convalescence about this, but he informed her that she was "all right." Shortly after the birth she began to suffer from severe pain in the back, also from feeling of weight in the pelvis and from "bearing down." These pains at first were intermittent, but have now become constant, and their severity has increased. She consulted Dr. M'Gregor, Ayr, who diagnosed an ovarian tumour, and sent her to me with the view to operation.

I saw her on 9th August, and examined her under $CHCl_3$, when her condition was as follows:—Uterus normal in position. There is a freely movable tumour the size of an orange occupying Douglas' pouch; it can be felt to have a short pedicle which passes to the right. On the left side the ovary is felt to be normal in size and position.

On 14th August, assisted by Dr. Edington, Dr. Galt giving $CHCl_3$, I operated by vaginal section. Douglas' pouch having been opened, the tumour was seized by a toothed volsellum, and delivered into the vagina. An oily-looking fluid exuded through the opening made by the volsellum, and the tumour being thus reduced in size a ligature was passed round the pedicle with ease. The ligature was tied with a Staffordshire knot and the tumour removed. The left ovary was found to be normal. The vaginal vault was sutured with catgut sutures, and the vagina loosely packed with CHI_3 gauze.

The tumour on removal was the size of a large orange and perfectly smooth, except that at one end is seen the fimbriated extremity of the Fallopian tube. On opening the tumour it is found to contain a quantity of pultaceous material and light brown hair (the patient's hair is black); the hair is short, and is coiled into a ball. Amongst the hair is a tooth, which is triangular in shape and is devoid of enamel. One of

Digitized by Google

its angles shows the so-called "caries." The inside of the tumour has a quantity of hair growing to it, and at the upper and outer end there is a pseudo-mamma about the size of a garden bean.

The patient made an excellent recovery, and went home on the 7th September.

MEETING IV.—6TH DECEMBER, 1897.

The President, DR. G. S. MIDDLETON, *in the Chair.*

I.—CASE OF "MALADIE DES TICS."

BY DR. W. R. JACK.

Dr. W. R. Jack showed a case of the *maladie des tics,* on which he read the following notes:—

The case which I wish to demonstrate to you to-night is an example of a condition not in itself excessively rare, but in connection with which little has been written in England. It belongs to the class of cases known in this country as "habit-spasm," and the reason why I have chosen the French name for the disease in the title of my paper is that it differs in some important respects from habit-spasm as usually described. *Maladie des tics* is a name used in France and Germany to indicate a distinct and special group of symptoms, of which convulsive tic is only one, and usually the earliest. The disease so designated has a more or less definite etiology, definite symptoms, and a definite mode of progress. Its main symptoms are these:—Involuntary movements of one muscle or muscle-group, or of several; involuntary exclamations or ejaculations; coprolalia, or the involuntary use of disgusting or obscene words; echolalia and echokinesis, or the involuntary repetition of words spoken, or gestures made, by others; and "fixed ideas," the domination of the intellect by one special thought, recognised by the patient to be unhealthy, and so to be distinguished from the fixed ideas of the insane. The disease is progressive, as a rule, but the progress is slow, and may be arrested at any point for years, or even for life. The term "habit-spasm," on the other hand, as used by Gowers and others, connotes none of these latter symptoms, and the expression "convulsive tic," as used in this country, indicates, as a

Digitized by Google

rule, merely a primary spasm of the muscles supplied by the facial nerve. With these preliminary remarks, I may read you the history of this case, and then introduce the patient.

N. K., a boy of 16, was admitted to Dr. Middleton's wards on 14th October, complaining of jerking movements of the head and arms of four years' duration.

His family history is good, no tendency to nervous affections being discoverable. His father and mother are healthy, and spring from healthy families. They had thirteen children, of whom six died in infancy. The remaining six are healthy. His friends state that the onset of the present illness was due to a fright. During a thunderstorm he was chased by a man from under a tree where he was standing, and came home in a state of terror. He was noticed to be "shivering" a good deal that night. But his father, in a subsequent interview, states that the illness preceded this fright by several weeks, and followed a fall on the back of his head, which he got while fighting with another boy. This gave rise to a transitory swelling, and confined him to bed for a few days. There was no headache, but he vomited several times during the first day or two, after which the vomiting ceased. About a fortnight or three weeks after the fall, slight twitching of the eyelids and movements of the head were noted. These gradually increased in severity, and became associated with similar jerking movements of the arms and shoulders, and also of the facial muscles. Seven months ago some improvement was noted in the condition of the arms, but not in other parts. When his father watched or cautioned him, the movements were less marked, but whenever observation was withdrawn, they became so much the more violent for the previous attempt at control. No pain accompanied them. Excitement increased their intensity, and they were evidently worse when he was with other boys. Although his sleep is restless, and he sometimes moans a good deal during the night, the spastic movements are arrested by sleep. They do not at all interfere with voluntary actions. Speech and deglutition are unaffected. There has been no impairment of intelligence, nor of the organs of special sense. The pupils respond normally to stimuli, and nystagmus is absent. He has had no headache, sickness, or vomiting, save in the first few days. There is no anæsthesia, paralysis, or paresis. Ataxia is absent, although the knee-jerks cannot be elicited. The bladder and rectum are perfectly controlled.

When I first saw him, as he lay in bed, he would remain

Digitized by Google

perfectly quiet for a short space of time, when suddenly the head would be jerked smartly backwards several times in succession, the movements being clonic, but without any regular rhythm. At other times the head might be brought forwards or inclined to the side. Spastic movements of the eyelids and of the zygomatici were also present, and a peculiar ejaculatory sound was noted in connection with the spasm of the mouth. The arms and hands were also the seat of spastic movements, and to a less degree the legs.

[The patient was here introduced, and it was shown that the spastic movements did not in any way interfere with voluntary movements. He could write, take his food, and walk in a perfectly normal manner. The movements were shown to be distinct from those of chorea, as the tongue could be held out quite quietly, and the food could be carried to the mouth, or objects held in the hand, with no tremor or jerking movements.]

With this case I wish to contrast the second, who is the subject of convulsive tic, as understood in England. I saw her yesterday for the first time, and was unable to do more than make a brief examination. The note of her history which follows concerns, therefore, only her present illness:—

Mrs. C., æt. 59, was sent from the Royal Infirmary Dispensary to see Dr. Middleton on 11th November, on account of a facial spasm of two years' duration. She attributes it to a blow above the right eyebrow, giving rise to swelling, a few days after which the eye began to wink.

She is now the subject of marked blepharospasm, but there is also very distinct twitching of the right facial muscles, which occurs, according to her statement, about once in every quarter of an hour. It gives rise to marked contortion of the face, and, though usually clonic, sometimes becomes almost tonic. Under excitement it gets worse, and a cold air blowing upon the face will also set it up. It ceases during sleep. There is no interference with speech or deglutition. The tongue, when protruded during an attack, is deflected to the right side, but not in the intervals. There is no paralysis of the palate. Hearing and sight are unaffected. Nystagmus is absent. There has been no loss of power in the arms or legs, but she experiences a feeling of weakness in them. She suffers from left frontal headache, worse during the attack, and from giddiness. She states that the eye became affected some time before the mouth, and that in the last twelve months the symptoms have increased in severity. I am

Digitized by Google

given to understand that the great organs of the body are unaffected.

[The patient was here introduced to the meeting.]

The two patients present, as you will see, many points of contrast. In the one the onset of the malady dates from the age of 12, in the other from that of 57. In the one the spasm of the face is bilateral, in the other unilateral. In the one the spasm is more or less generalised, in the other it is confined to the domain of a single nerve. And in the case of the *maladie des tics*, you have the peculiar ejaculatory sound which is absent in the other.

It is to Gilles de la Tourette, in a paper written in 1885, which I regret that I have not been able to find, that we owe the first definite description of this malady, and to another Frenchman, Guinon, whose papers may be found in the *Dictionnaire Encyclopédique des Sciences Médicales*, 1887, and in the *Revue de Medécine*, 1886 and 1887, a complete account of its various symptoms. The subject has also attracted the attention of German writers, among others Jolly, in the *Charité-Annalen* of Berlin, and for a brief but graphic description I may mention Oppenheim, in his *Text-Book of Nervous Diseases*, 1894.

In the time at my disposal I can give you but a brief account of the symptoms and the progress of the disease. It begins, as a rule, in childhood, as do the "habit-spasms" of English writers, but it is to be distinguished from them in this, that while, according to Gowers, habit-spasm tends to recovery within a few months or years, the *maladie des tics* tends to ingravescence. Convulsive tic, by which I mean a primary spasm occurring in the area of the facial nerve, is a disease of later life. The earliest symptom of the malady is generally a simple tic, usually affecting the muscles of the face, and particularly the orbicularis palpebrarum. After a time, other tics become associated with the first; the muscles of the lips are involved, or those of the neck, causing such nutatory movements as were seen in this case. As the variety of the movements increases, so does the number of attacks. The spastic movements may spread to the arms, and much more seldom to the legs. There follow (I give them in the order which, according to Guinon, represents their relative frequency, but not necessarily in the order of incidence) involuntary exclamations and coprolalia, next the *idées fixes*, and last echolalia or echokinesis. In the earlier stages of the malady, and indeed throughout, the spastic affection,

Digitized by Google

whether of the motor area or of the ideational, is to some extent under the control of the sufferer. By an effort of will, he can for a time restrain its manifestations. But he pays for his effort, both in an increased access of the spasm when it is finally relaxed, and in a feeling of oppression during its continuance. In the later stages, when those changes that must excite the observation of the most careless have become pronounced, despondency and even suicidal tendencies may make their appearance. Such cases, however, are in a small minority. The malady progresses slowly, and in many instances the graver symptoms do not appear. The order of their appearance is variable; fixed ideas, for instance, though usually a late, may be an early symptom. Patients labouring under this disease usually become increasingly irritable and excitable. As it progresses, although the intelligence is absolutely unimpaired, the power of concentrated attention is diminished or lost, so that in advanced cases a patient may even be unable to read, the effort to fix the attention at once leading to a violent access of spasms.

With regard to diagnosis, certain forms of hysterical spasms may closely simulate the *maladie des tics*, and in these cases one may also have involuntary ejaculations or even echolalia. But the presence of other hysterical stigmata, tenderness over one or more of the well-known points, localised anæsthesia or paralysis, or hemianæsthesia, and the contraction of the visual fields, will dispel confusion.

Chorea, again, presents a certain similarity. But the movements of tic do not interfere with voluntary acts. You have seen that this boy can hold his tongue out steadily for some time, he writes without a tremor, he carries his food to his mouth and never past it, and so on. The disease known as electric chorea, or Dubini's disease, besides being chiefly confined to Lombardy, is of relatively short duration, and almost invariably fatal. It is also attended with wasting. Hemichorea and athetosis can be at once excluded, and in organic affections, central or peripheral, involving a nerve supplying the face or neck, the symptoms are uniform.

The prognosis *quoad vitam* is, of course, good, except in the later stages, when mental despondency may give rise to suicidal tendencies. But not much hope of recovery can be held out. There may be recessions of the affection, lasting for a considerable time, but they are usually followed by a further development of the disease.

The most prominent factor in the etiology is heredity, not direct, but of a general nervous instability. Insanity is

Digitized by Google

frequently to be discovered in the family history. The onset of the affection is very often attributed to a shock or fright, and sometimes to a blow. In the case before us, careful inquiry into the family history has failed to elicit any evidence of a neuropathic tendency.

The malady has no pathology, in the sense of any recognisable structural change. Guinon points out that the malady is due to the loss of the inhibitory power of the will, and that the fixed idea is to be regarded as a spasm of ideation, comparable to the muscular spasm. It is probably to be explained by a loss of connection in the various association fibres. Impulses no longer travel to the ideational centre except along one route; and similarly with the motor centre, the inhibitory association fibres are thrown out of connection. Echolalia he explains by supposing that the ideational centre being inactive, auditory suggestion is transmitted direct to the motor centre as if along a reflex arc, and so in echokinesis, where the path is directly from the visual to the motor centre.

In conclusion, the treatment of such cases is not hopeful. It is important that as little attention as possible should be paid to them. Drugs have little or no effect upon the condition, although where the paroxysms are very violent, a large dose of chloral may procure some hours of rest. The application of electricity is not of much avail, but Oppenheim has seen improvement under a mild course of hydrotherapy, and he lays stress upon the isolation of the patient.

Dr. Alex. Robertson said that the spasm of the muscles of the neck was somewhat similar to that of spasmodic torticollis, but in these cases the spasm was not so widely diffused. The repetition of words, and the fixed ideas, which had been described, were interesting, as tending to connect the condition with insanity. The discussion at Moscow had shown a considerable variety of view on the subject of the *idée fixe*, but, in view of the multiplicity of nerve connections, there was no need to be at a loss for a theory. The inhibition theory did not seem to him entirely satisfactory. He was accustomed, when a portion of the nervous system was thrown out of action, to compare it with the result of disconnecting part of a large system of machinery, the other parts of which might continue their work in a perfectly regular fashion.

Dr. J. Lindsay Steven recalled the case of a man whom he used to see upon the street, stopping every now and then to measure or to touch objects lying upon the pavement, such as pieces of paper, and so on.

Digitized by Google

Dr. Wallace Anderson also remembered the man, but stated that he was insane. The pathology of the condition was hypothetical, but he thought it less a want of inhibition than an auto-stimulus. The action of the bromides in epilepsy would seem to point to their usefulness in these cases.

Dr. T. K. Monro asked if there were any further distinctions between this condition and habit-spasm. He had seen cases of the latter which had persisted. He remembered one in which there was improvement under mixed bromides.

Dr. Dun was surprised that Dr. Robertson had not seen more cases in asylums. Habit-spasm was not so hopeless as had been suggested. He remembered two similar cases in a mother and son, in both of which recovery took place.

Dr. Middleton pointed out that the case had been sent into his wards as one of chorea.

Dr. Jack replied.

II.—CASE OF SPASTIC PARAPLEGIA IN A BOY WITH A PECULIAR GAIT, AND PROBABLY DUE TO A PROGRESSIVE MYOPATHY.

By DR. J. LINDSAY STEVEN.

I have ventured to call the affection from which this boy is suffering spastic paraplegia, although I am by no means sure that it fulfils the requirements of the clinical condition ordinarily designated by this term. While the rigid condition of his lower limbs, and his stiff, deliberate, and very peculiar manner of walk are suggestive of a spastic paraplegia, the entire absence of knee-jerks and ankle clonus, and the tendency to deformities of the feet and trunk, rather indicate that the site of the disease may be primarily in the muscles themselves. Of the peculiarities of the case, however, you will be in a better position to judge after I have related the clinical history and shown you the patient.

The lad is a message-boy, aged 15 years. Three years ago he first complained of a pain and stiffness in the left knee-joint, which interfered with his walking properly. For the next two years the difficulty of locomotion went on increasing, occasional attacks of pain in the left knee-joint being also experienced. About a year ago he first observed a deformity occurring in the left foot—in fact, the development of a condition of talipes equino-varus. During the three years that his power of walking has been interfered with, he has frequently suffered from headaches; and he attributes his illness in the first instance to cold contracted while going about a great deal with his bare feet.

Digitized by Google

As regards his previous history, the following points are of some importance. At the age of 5 years he suffered from "croup and diphtheria," for which he was treated in the Sick Children's Hospital, where tracheotomy was performed. No

FIG. 1.

Shows attitude of boy on 6th March, 1898, when he attempted to stand with his legs tolerably close together. The position of the arms shown in the photograph gives a good idea of the manner in which they were held during walking, ready to grasp any object capable of giving support. Without support it was practically impossible for him to stand in the position photographed. (*Photo. by Mr. John Garroway.*)

paralysis followed this attack. He has also suffered from chicken-pox and other infectious maladies.

The family history throws no light upon the case. His father is alive and well. His mother has developed a tubercular disease of the knee-joint during the last six months.

Digitized by Google

Three sisters and one brother younger than the patient are in good health. Three of the family died in early infancy.

This is the second time that the lad has been under my care, he having been admitted to Ward 7 for the first time on

FIG. 2.

Shows marked lordosis, and the necessity for support in standing (6th March, 1898).
(*Photo. by Mr. John Garroway.*)

the 24th July, 1896. During a residence of several months at this time, the following observations as to his condition were put upon record:—His walking was peculiar. In progression he swung the legs outwards and forwards, as if in addition to the need for carrying the limbs forward there was also a necessity

Digitized by Google

to overcome a spastic tendency to adduction of the thighs. He brought his heels to the ground first, but not with any undue force. Both in standing and walking he required to dispose his feet in such a way as to secure a broad base. No patellar reflex or ankle clonus could be made out; the superficial reflexes were normal. There was marked stiffness of the lower extremities upon any attempt at passive motion; but he never experienced spontaneous spasmodic contractures of the lower limbs. No actual paralysis of the leg or thigh muscles, which were of good volume and consistence, could be made out. He was able to stand steadily with his feet close together, but when he did this his attitude was awkward, owing to his knees overlapping. If he attempted to stoop without bending his knees he fell forward upon his face. His general nutrition and development were good. He was and is very intelligent, and reads well. There was no facial paralysis or difficulty of speech. The senses of pain, touch, and temperature were quite normal. The organs of the chest and abdomen were healthy. The functions of the bladder and rectum have all along been normal.

In the month of September, 1896, it was noted that the rigidity and hardness of the muscles of the lower limbs were more marked than before, and when he stood with his eyes closed he was noticed to sway slightly. There was no nystagmus, no squint, no diplopia. In walking he now held his arms out from the body, partly to balance himself, partly to be ready to clutch any object suitable for support. The manner of holding the arms suggested an attitude seen in some cases of disseminated sclerosis. It was also observed that there seemed to be a very slight degree of inco-ordination of the upper limbs, although this did not interfere with his writing very well. Very definite high arching of the instep was at this time noted, so that sometimes he seemed to be walking only on the heel and the toes.

In October, 1896, while at the Convalescent Home, he suffered from an attack of pain and swelling in the left knee-joint, which, however, soon passed off, leaving the other phenomena as recorded.

The boy was readmitted on the 28th October, 1897. His difficulty of walking was very greatly increased. In moving about it was necessary for him to lay hold of any object within reach capable of supporting him as he laboriously dragged his limbs along. By a swinging motion of the body he dragged the legs forward, carrying them well out from the trunk, so that he occasionally had the appearance of attempting

Digitized by Google

to take a very long step. The toes reached the ground first, and he often landed on their dorsal aspect so that they became doubled up under the foot. The left leg, as has been the case all along, was still the worst. The muscles of the legs showed no atrophy, and were firm and rigid. The foot could not be passively flexed upon the leg beyond a right angle. No ankle clonus and no patellar tendon reflex could be elicited. These features of the case are still well seen when I ask the boy to walk across the room; in addition, certain deformities have become developed. There is a marked condition of talipes equino-varus of the left foot. Lordosis is now very pronounced, as well as a degree of lateral curvature of the spine, the convexity being towards the right (Figs. 1 and 2, pp. 52 and 53). Dr. T. K. Monro has made a very careful investigation of the state of the cranial nerves, of which his summary is as follows:—"There is slight nystagmus, only noticed on extreme deviation of the eyes. The right pupil is very slightly larger than the left, otherwise everything is normal."[1]

There is no atrophy of the muscles of the arms, and the

[1] Detailed note of the condition of the cranial nerves by Dr. T. K. Monro:—

9th to 11th November, 1897.—I. Smell preserved.

II. O.E. (both eyes alike).—Discs not very well defined but quite healthy. Some fibre bundles extend along some of the vessels from the discs. Remaining parts of fundi normal. V.A. = $\frac{18}{6}$ in each eye.

III, IV, and VI. There is no external ocular palsy, and patient never has diplopia. There are slight horizontal nystagmoid movements of the eyeballs when these are rotated far from the mid-position; but spontaneous nystagmus is not observed.

Pupils.—The left pupil is medium-sized, the right very slightly larger. Each contracts directly and consensually to light, and contracts when the visual axes converge in attempts at accommodation. Accommodation itself is good. Each pupil appears to dilate on stimulation of the skin of the neck; but a little doubt is introduced by the free spontaneous movements or unrest of the pupil.

Motor.—The masticatory muscles are strong—the masseter, temporal, external and internal pterygoids being all ascertained to act on both sides.

Sensory.—There is no pain, and no defect of sensation (finger-touch, contact of pin-point, heat, and cold) in the face.

Taste is preserved in (i) palate and fauces, (ii) posterior part of tongue, and (iii) anterior part of tongue.

VII. Facial muscles are normal.

VIII. Hearing, so far as can be tested in a noisy ward, is well preserved. Rinne's experiment positive on each side.

IX, X, and XI (medullary portion). There is no evidence of disturbance of the functions of these nerves. Respiration (taken every three hours for the past two days) has varied from 16 to 24, and the pulse from 74 to 100. The temperature during the same time has been 97·6° to 99·2°. The

Digitized by Google

slight inco-ordination previously noted has not become worse. No fibrillary tremors have at any time been observed.

The case is in many respects peculiar, and I have had considerable difficulty in arriving at an opinion as to its true nature. Three conditions presented themselves to me for consideration:—

1. Infantile spastic paraplegia due to degenerative lesions or defective development of the lateral columns of the spinal cord. The entire absence of the knee-jerks and of ankle clonus, as well as of any tendency to spasm of the legs, soon led me to set this consideration aside.

2. Friedreich's hereditary ataxy was next taken into account. The age of the patient and the absence of the deep reflexes were, on the whole, in favour of this view as to the nature of the complaint. It soon became so evident that the difficulty of locomotion was due to a muscular disability rather than to a disorder of co-ordination that this diagnosis was also departed from.

3. A progressive muscular dystrophy or myopathy seems to me to be the only diagnosis left. In children there are chiefly two varieties of this disorder met with—viz., pseudo-hypertrophic paralysis and simple idiopathic muscular atrophy; the latter form, however, according to Gowers, rarely begins in early childhood. Of neither of these forms can the present case be regarded as a perfectly typical example. Of pseudo-hypertrophic paralysis I have now seen several examples of a characteristic kind, and certainly this boy has never struck me as being at all like them. The absence of a family tendency so far as we can ascertain, the commencement of the disease in the left lower limb, in which the disability has all along been most marked, and the mode of walking, all seem to me to place the case in a category different from that of ordinary Duchenne's paralysis. That it is not an ordinary case of simple idiopathic muscular atrophy, either of the "juvenile" or "facio-scapulo-humeral type," the definite absence of any distinct wasting of the muscles seems to indicate. The marked muscular disability, the absence of the deep reflexes, the acquired talipes equinus, and the gradual development of lordosis and lateral curvature of the spine, with the unimpaired sensory and intellectual faculties, all seem to indicate the

soft palate is actively moved. There is no coughing, choking, or difficulty in deglutition.

XI (spinal portion). Sterno-mastoids and trapezii strong.

XII. Tongue normal.

Summary.—Slight nystagmus, only on extreme deviation of the eyes. Right pupil very slightly larger than left. Otherwise everything normal.

Digitized by Google

propriety of classing the case as an undefined member of the general group of muscular dystrophies.

Last session, along with Dr. Monro, I presented a series of cases of muscular atrophy to the Society, an account of which will be found in vol. i of the *Transactions* at p. 249. With Case 3 of this group the present one might with profit be compared, although in many respects they seem to be essentially different in clinical details.

The lad has been treated by tonics, massage, and electricity, without material change in his condition.

III.—CASE OF TOXÆMIC JAUNDICE.

By Dr. J. Lindsay Steven.

Dr. J. Lindsay Steven read the history and showed specimens from a case of toxæmic jaundice.

The details of this case are of interest as affording a clinical illustration of a true toxæmic jaundice without obstruction, except in the finer bile-ducts within the liver itself. During life the patient presented many of the features of acute yellow atrophy of the liver, and the whole duration of the disease was two or three weeks. Microscopic sections of the liver, prepared by Dr. Walter K. Hunter, were shown, which clearly demonstrated the blocking up of many of the capillary bile-ducts by inspissated bile. There were also numerous small circular ulcers in the colon.

Dr. Middleton, in discussing the first case, said that he had in his wards two cases somewhat resembling this. The one was a case of Friedreich's disease; the other, in which the atrophy was similar to that in this case, was undoubtedly a muscular dystrophy. This case was probably of the same nature, and had arisen from some congenital defect not manifested for some years after birth.

Dr. Robertson said that the case did not correspond with any example of Friedreich's disease that he had seen. He did not know that any more reasonable view than Dr. Middleton's could be entertained.

Dr. W. K. Hunter, on the second subject, remarked that the case was of interest on account of its seeming connection with pernicious anæmia, but on staining for iron in the liver no deposit of free pigment could be found. If any iron were present, it must have been intimately bound up in the crystalline form. If toxæmic jaundice and pernicious anæmia

Digitized by Google

were both due to poisons absorbed from the alimentary tract and passing into the portal circulation, then these poisons must have different actions, for in this case there was no liberation of iron albuminate.

Dr. Middleton was surprised that there had been no head symptoms, as these were very common in such cases. The case would throw light upon the obscure forms of non-obstructive jaundice.

MEETING V.—14TH JANUARY, 1898.

The President, DR. G. S. MIDDLETON, *in the Chair.*

I.—CASE OF PERMANENT DEFECT OF THE CONJUGATE MOVEMENT OF THE EYES TO THE LEFT SIDE, WITH PARESIS OF THE LEFT MIDFACIAL MUSCLES, APPARENTLY FROM A LESION INVOLVING THE NUCLEUS OF THE SIXTH NERVE.

BY DR. T. K. MONRO.

This patient, æt. 46, consulted me at the Royal Infirmary Dispensary in 1893, not about herself, but about her child, and the peculiar movements of her eyes at once attracted attention. They could not maintain the forward gaze for any length of time, but while she was quietly talking about her children, and indeed under almost all circumstances, they would deviate strongly to the right and somewhat downwards —say several times in a minute—and then regain the mid-position.

She has had trouble with her eyes almost from birth. After patient was born, her mother was ill for six weeks, and as the father was away from home at the time, it is supposed that the eyes were neglected. When she was 6 weeks old, her father returned, and thought she was not seeing so well as she ought to. He consulted Dr. Mackenzie about her when she was 2 months old. This defect of sight was due, patient says, to the presence of "specks" on both eyes. The speck cleared finally off the left eye when she was 7 years old; that on the right still remains. She had measles, followed immediately by a "nervous fever" when aged about 7 years. (This "nervous fever" was on one occasion styled "enteric;" and on further inquiry, it appeared that the doctor thought it a kind of enteric fever with nervous symptoms.) Both the

Digitized by Google

impairment of vision and the rolling of the eyes were worse after the fever, but it was after the fever that the speck cleared off the left eye. It is probable that she had a mild attack of scarlet fever at 11. When she was about 17, a doctor operated on her left eye at the inner side. He wished to operate on the right eye afterwards (the patient says at the *inner* side), but was not allowed. His purpose was to "straighten" the eyes, and "keep them from rolling so much." The one operation is said to have done a little good, but not much. The eyes have rolled as long as patient can remember, and she has no idea when they lost the power of rolling to the left.

A brief examination is (or for a long time was) enough to make patient lose control of the ocular movements. For instance, at the outset she may be able for a little while to look directly forwards, but as she tries to turn her eyes in different directions, they tend more and more to deviate to the right, and may become fixed in that position, and so the facts arrived at—and of these only a small selection are mentioned here—represent the result of a great many examinations carried out at different times at the hospital or at patient's residence.

Visual acuteness is very defective. One note says she counts fingers with the right eye at 1 foot, and with the left at 2 feet, but there is little doubt she can do better than that. Attempts to read seem to cause pain in the eyes, and when she does try it, she depends chiefly on her left eye, and holds the book close to her face. In childhood she required large type.

There is a considerable leucoma in the lower part of the right cornea; the iris is adherent to this, and the pupil is small and deformed. Uveal pigment seen in some quantity along the circumference of the right pupil may be taken as evidence of a past iritis. There is slight convergent strabismus.

Spontaneous nystagmus is seen in each eye whether uncovered by itself or along with its fellow. The movements are of small extent, tremulous, not confined to one plane, and not more rapid in one direction than the other. As a rule, the eyes cannot be moved to the left of the mid-position, but palsy is not absolute, and they may at times get beyond the mid-position. It may be impossible for a time to get the eyes out of the position of strong deviation to the right.

The power of lateral movement of the eyes usually found may be summed up thus:—When the left eye is covered, the right eye can be rotated further inwards than when both are

Digitized by Google

uncovered. When the right eye is covered, the left can scarcely be moved out of the position of extreme inward rotation. When both are uncovered, the left eye can be rotated outwards about as far as the mid-position, and the right eye to or even beyond the mid-position.

As to the power of convergence, it is not possible to speak very definitely; and it must be borne in mind that patient has probably not for many years possessed binocular vision. More than once it has been thought that slight convergence did take place on an attempt to look at a near object, and on one such occasion (November, 1897) the left pupil contracted a very little at the same time. On the other hand absence of convergence and of the associated pupillary contraction has been noted (*e. g.*, April, 1895).

The upward movement of both eyes is deficient, though not lost, and ptosis is associated with the deficiency of upward rotation.

The naso-labial furrow is well marked on the right side of the face, but is not so distinct on the left side, particularly at its upper part. The mouth is slightly drawn to the right side, and this difference between the two sides is still better seen when patient is asked to show her teeth. There is no difference between the upper facial muscles on the two sides. Electrical examination, moreover, shows that the zygomatici respond rather less readily to both faradism and galvanism on the left side than on the right; the polar reactions not being altered. This is consistent with the theory of a slight chronic or old standing lesion of the lower segment (nucleus or nerve fibres).

The palsy of the left external rectus, the great defect of the conjugate movement of the two eyes to the left, the much more extensive inward movement of the right eye when acting alone than when acting conjugately, and the paresis of the left mid-facial muscles, would be accounted for by a lesion destroying the left sixth nucleus and damaging a few fibres of the seventh nerve as they wind round the sixth nucleus, in close apposition to it, before emerging from the pons.

The lesion that may give rise to paralysis of the conjugate movement of the eyes may be a tumour, or hæmorrhage, or softening. The history of this case gives us little information, for the family appear never to have attended to the character of the ocular movements. If the lesion was a tumour, it was never large, and has long been stationary. It is quite possible that it was vascular (obstructive) and associated with one or other of the fevers from which patient suffered in her early

Digitized by Google

years. Hæmorrhage may be excluded on the ground of age, assuming, of course, that the condition has been present from early life.[1]

The weakness of the upward movement of the two eyes with slight double ptosis might be accounted for on the theory of a lesion involving part of each oculo-motor nucleus. It is more likely, however, that owing to the presence of the leucoma over the lower part of the cornea, patient has long since learned to associate a downward rotation with the various other movements of the eyes so as to see, as it were, over the top of the opacity.

Repeated attempts were made at first to examine the fundus, but without success; in the case of the left eye, on account of the extreme deviation, and in the case of the right, on account especially of the leucoma and the fixation of the iris.

It may be added that apart from the eyes and face, patient is healthy. She speaks intelligently, and answers questions promptly and in a lucid manner. The head can be turned quite freely to either side, and there is no spasm or weakness about the trunk or limbs. Nothing abnormal has been noted with regard to movement, sensation, co-ordination, or the knee-jerks. Patient has two children. She never had a miscarriage, or rheumatism, or chorea, and the heart when examined some time ago was normal.

This case has now been under observation for more than four years, and the condition has been in the main a stationary one. Such change as has taken place, however, has been in the direction of improvement. In autumn, 1895, patient and her brother agreed that she could see farther to the left than before, and it was found that the left eye could, while the right was covered, reach the mid-position. But in December, 1896, it was noted that the eyes could not get to the left of the mid-position, they were constantly deviating to the right, and while patient was dressing her child, she kept her head turned to the left.

Dr. Rowan said he would like to know the results of ophthalmoscopic examination. If the internal rectus had been cut, it might account for much in the position of the patient's eyes. Was the case getting worse or remaining stationary?

[1] Dr. John Love suggested at the meeting that the cause may have been polio-encephalitis occurring in association with one of the fevers from which patient suffered, a hypothesis which is perhaps as reasonable as either of those adduced above.—T. K. M.

Digitized by Google

Dr. Ernest Thomson asked if it was certain that the case was not congenital.

Dr. Alex. Robertson said that the affection of the face supported the theory of an internal lesion. He thought it settled that an apoplectic lesion in front of the middle convolutions might induce conjugate deviation of both eyes.

Dr. Monro replied that he was unable to say that the case was not congenital, but it was at least possible that there was a lesion of the nucleus of the sixth nerve, which was not likely to be congenital. The vision was very defective. Ophthalmoscopic examination was impossible in the left eye from the strong inward rotation, in the right from the large leucoma. The condition had been stationary up to 1895. There was then a slight seeming improvement, followed by a return to the old state.

II.—A CASE OF "WORD" WITHOUT "LETTER" BLINDNESS.

BY DR. HINSHELWOOD.

Dr. Hinshelwood's paper will be found in the *Lancet* of 12th February, 1898.

Dr. Alex. Robertson said that the case was one of an uncommon kind. He was not surprised at the difficulty in recognising words while letters could still be recognised. Letters were more fundamental, and therefore made a deeper impression on the brain, so that a lesion might efface the impressions of words while leaving those of letters. He thought it a pity to increase the number of centres if an explanation referring the symptoms to the same centre would suffice.

Dr. T. K. Monro said that either theory would account for the facts, but Dr. Hinshelwood's would only be demonstrated when a converse case was found—namely, a patient able to read words but not letters.

Dr. Love said that, contrary to Déjerine's statement, cases had been shown where word and letter blindness were complete, and the patients yet wrote fluently. This might even occur where those centres were much destroyed, as in patients given to writing the impression might be revived from the kinæsthetic memory. Cases such as Dr. Monro referred to were already on record. A recent supporter of Dr. Robertson's view was to be found in Horsley, who considered, with regard to the motor area, that motor memory, muscular sense, &c., were represented at different levels in the same area.

Digitized by Google

Dr. Middleton said that Dr. Hinshelwood's view was the most common with regard to various centres. But this inability to read words and not letters might be explained on a theory similar to Broadbent's motor theory. This might perhaps be taken with Dr. Robertson's explanation.

Dr. Hinshelwood, in reply, said that the view taken by Dr. Robertson and Dr. Middleton was the old view of Broadbent. From his own case and from others the fact of the increased complexity of the centres was no objection to his theory. Localisation was as yet in its infancy, and careful study of each centre, as in the case of the visual centre, would show that it was made up of a number of distinct areas with distinct functions. The first case which had startled him was that of a Frenchman who consulted him about temporary attacks of aphasia, went home, and died shortly afterwards. The patient's wife wrote to him, stating that before his death she had had to speak in English to her husband in order to be intelligible. On the old theory it ought to have been French, as more deeply graven on the brain. The only explanation was that the memories of different languages were accumulated and retained in different parts of the brain. At the moment he could only refer to one case such as Dr. Monro desired.

III.—SPECIMEN OF BRAIN TUMOUR.

BY DR. J. LINDSAY STEVEN AND DR. T. K. MONRO.

Dr. J. Lindsay Steven and Dr. T. K. Monro showed a specimen of brain tumour.

The case of cerebral tumour, specimens from which we desire now to demonstrate, is of interest from several points of view. The multiple nature of the tumour is a point of the greatest importance in reference to treatment. You will see in the specimen that we have one large growth occupying an extensive area of the left hemisphere, and a smaller nodule in the right. Although it is obvious that anything in the nature of a radical surgical operation for removal of the growth was out of the question, treatment by the trephine might have been of great service for the relief of pain by lowering intra-cranial pressure. Before, however, further referring to the specimen, the following notes of clinical history, carefully compiled by Dr. T. K. Monro, may be submitted for your consideration:—

Mrs. A., 23, housewife, was sent into Dr. J. Lindsay Steven's

Digitized by Google

wards on the 18th August, 1897, by Dr. Burges. He had seen her on the night of the 14th inst., on account of severe bilious vomiting, with some loss of power in the hands and inability to express herself properly in language. On the 15th and 16th, patient seemed rather better, but at 9 P.M. on the 17th Dr. Burges found her semi-comatose, with some rigidity of the right arm. The left pupil was slightly smaller than the right. Three ounces of urine—apparently the whole secretion since morning—were drawn off by catheter, and were found to contain a considerable quantity of albumen. Patient struggled and cried "gi' me, gi' me," and occasionally screamed aloud. It was noticed that the tongue had been bitten.

Some further information was obtained from relatives at the time of admission. Patient had been vomiting since the 9th inst. She had been subject to headache for many years, but recently this had become much more severe. Her speech was first affected about fourteen days before admission, but became so much worse a week later that her husband could not understand her. Loss of power in the right hand was believed to date from the 14th. Patient became unconscious at 3 P.M. on the 17th.

She had measles and whooping-cough in childhood, and had for some time been subject to bronchitis. She never had scarlet fever, rheumatism, or chorea. She was the mother of two children, the younger of whom (æt. 16 months) she had been nursing until the 14th. There was no history of convulsions before the present illness began, or of œdema in pregnancy, or of deafness, or of discharge from the ears.

The following is from the note made on admission:—Patient is practically unable to express herself intelligibly. Consciousness is in great measure, though not altogether, restored, and patient spontaneously calls attention to the condition of her tongue, which has blood upon it, and has evidently been injured by the teeth. She complains of severe headache in the lower frontal region. She executes some movements she is told to perform, but not all. The tongue, when protruded, deviates strongly to the right side, but there is no conspicuous difference between the two sides of the face. The right arm lies flaccid in the posture of rest. The right leg can be raised from the bed when extended, but patient appears unable to flex the knee. The knee-jerk is well marked on both sides, but there is no ankle-clonus. A trace of each plantar reflex is preserved, but the abdominal and epigastric reflexes are absent on both sides. There is a fairly well-marked *tache*

Digitized by Google

cérébrale. The pupils are moderately sized or slightly large, and equal. Each contracts directly and consensually to light. There is no loss of power or deviation of head or eyes to the right side.

The heart is not obviously enlarged, and its sounds are normal. Slight wheezing anteriorly is the only noteworthy point in the physical examination of the lungs. The feet are free from œdema.

19th August, 1897.—Patient is fairly sensible this morning. She vomited a good deal yesterday and during the night. She is conscious of the prick of a pin on the upper and lower limbs. Temperature last night, 99°; this morning, 97·4°. The urine contains abundant albumen and large numbers of fatty casts. It is high coloured, and deposits abundant urates. Reaction, acid; specific gravity, 1030. The headache to-day is much less severe. She says that formerly the pain was in the right eye.

The albuminuria rapidly disappeared, and by the 25th August its absence was noted.

7th September.—Patient, though certainly better than on admission, has improved very slowly since the first two or three days of her residence. From time to time she has had frequent attacks of vomiting. She scarcely speaks, though this is perhaps due to lack of will as much as to lack of power. She is extremely emotional, and always low-spirited, so that she weeps with almost no provocation. There is slight weakness of the tongue and face on the right side. The right upper limb is completely powerless, and is all flaccid except the fingers, which are partly flexed. The maximum girth of the right calf is $10\frac{7}{8}$ inches; of the left, $11\frac{1}{8}$ inches. There is no trophic lesion of the skin. Patient does not now complain of headache. Sensation is now found to be defective on the palsied side. When the skin of the arm or leg is struck smartly with a pin point, patient indicates that she is conscious of an impression, yet the pin can actually be pushed through the skin of the fore-arm or leg without any evidence of pain being called forth.

On 10th September, a moderate degree of bilateral optic neuritis was observed. There were no hæmorrhages, and the macular regions were normal.

From this time onwards, the principal symptoms, in addition to the right hemiplegia and aphasia (which now appeared to include word-deafness) and the optic neuritis, were these—exophthalmos without enlargement of the thyroid; vomiting and screaming at intervals; a considerable degree of blindness

Digitized by Google

though the pupils still contracted to light; increasing weakness of the left upper limb with paresis of the left leg; obstinate constipation; evacuation of most of the urine into the bed; lethargy and obscuration of consciousness; flaccidity of the limbs; exaggeration of the left knee-jerk, the right being normal; or, at another time, the left normal and the right in excess, both plantar reflexes being preserved; absence of abdominal and epigastric reflexes on both sides; retraction of abdominal wall; *tache cérébrale* and subnormal temperature.

The cry alluded to was sudden and loud, and for some days was uttered very frequently. When patient was watched at such times, the appearance of her features was such as to suggest that the scream may have been elicited by an exacerbation of great pain in the head; latterly she became much quieter under the influence of morphia.

On 20th September, at 3·15 P.M., patient had a convulsive seizure, in which there was twitching of the left side of the face and left arm; in the evening, her temperature was 100°. As late as the 23rd September—the day of her death—it was noted that taste and hearing, and reflex contraction and dilatation of the pupils, were preserved, and that there had been no strabismus. At this period the temperature tended to rise in the mornings. About 6 P.M. on the 23rd, her lips became blue, and Cheyne-Stokes respiration set in shortly before death at midnight. The temperature rose from the afternoon up to the end, when it was 106° (in the axilla).

The following is an account of the autopsy, permission to open the cranium having been obtained with the greatest difficulty by Dr. J. Lindsay Steven, who performed the *post-mortem* examination, on the 25th September, 1897 :—

Summary of Post-mortem Examination.—Glio-myxoma cerebri, two tumours—large one involving left internal capsule, and smaller the right supra-marginal and ascending parietal convolutions.

The dura mater presents normal appearances, and the longitudinal sinus contains a small quantity of loose *post-mortem* clot. There is no undue adhesion between the dura and the bone. On exposing the convolutions considerable engorgement of the vessels of the soft membranes is discovered. It is also at once apparent that there is great flatness of the convolutions of the left hemisphere, with considerable dryness of their surface. This contrasts strikingly with the moist and non-compressed condition of the convolutions of the anterior portion of the right hemisphere. It is noted that the posterior

Digitized by Google

portion of the right surface is drier than the anterior. The structures at the base of the brain present perfectly healthly appearances, and in particular it is noted that there is no trace of exudation either here or in the convexity. On cutting into the left hemisphere its substance is found to be occupied by a very large gliomatous tumour, consisting of a comparatively loose fibrous-looking network, the interstices of which are filled with a thin gelatinous fluid, which slowly drains away after a little. Anteriorly, the greatest length of this tumour is 4 inches, and vertically, a little less. It occupies practically the whole of the upper portion of the internal capsule; and the greater part of the left corona radiata, the lenticular nucleus, and the outer portion of the optic thalamus are completely destroyed by the tumour. The floor of the left lateral ventricle and the caudate nucleus do not seem to have been encroached upon. The fornix and other structures occupying the middle part of the ganglia on the right side are perfectly healthy. On cutting into the right hemisphere, a smaller tumour of the same nature, and about the size of a walnut, is found immediately beneath the grey matter of the supramarginal convolution. The anterior margin of this nodule rests upon and involves the substance of the middle portion of the ascending parietal convolution.

Further examination of the body is not allowed.

Microscopic examination of the tumour by Dr. Charles Workman:—

"Sections have been prepared by embedding a portion of the very soft pliable part of the tumour together with the firmer brain tissue in its neighbourhood from the region of the corpus striatum in celloidin. These have been stained, some with Ehrlich's acid hæmatoxylin, others by Mallory's method, and they show that the tumour is primarily a glioma, which shades gradually into the normal brain tissue, not being encapsuled nor showing any definite line of demarcation. The cells of Deiter are in great numbers, and beautifully demonstrated in the sections stained by Mallory's method. In the meshwork there are large numbers of round cells with much granular protoplasm, and for the most part with single rounded nuclei. These cells appear to lie almost quite loose in the stroma. The soft pliable part has the appearance of a myxomatous degeneration of the tumour, the connective tissue and cells of Deiter being widely separated, and the spaces being filled with clear fluid in which are seen similar cells to those described in the meshwork of the denser part. These round

Digitized by Google

cells are very various in size, many of them being large like mononuclear leucocytes."

The accompanying micro-photographs, by Mr. Archd. Young, M.B., B.Sc., have been prepared from two of Dr. Workman's sections, and afford a very good idea of the histological appearances of the growth.

Dr. Middleton asked how long the patient lived from the commencement of the symptoms, and was told thirty-eight days.

Dr. Alex. Robertson said that the diagnosis was sufficiently clear. There was one point which he wished to make in connection with tumours of the brain. The patient had complained much of headache, and at the *post-mortem* the convolutions had been found much flattened. Should we not more often trephine, simply to relieve suffering, though not to cure? The operation often did give great relief.

Dr. J. Lindsay Steven said that in Dr. Pringle's ward there was some time ago a patient with all the symptoms of intracranial tumour, whose skull had been trephined nine months ago over the seat of pain. Great relief followed, and lasted for six months, when the symptoms returned. The patient was sent to Dr. Steven, and by him to Dr. Pringle. Trephining was again done. No tumour was found, but the pain was greatly relieved.

MEETING VI.—4TH FEBRUARY, 1898.

The President, DR. G. S. MIDDLETON, *in the Chair.*

I.—CASE OF DISLOCATION OF THE LENS OF OVER TWENTY YEARS' STANDING.

BY DR. ROWAN.

Dr. Rowan showed a patient with dislocation of the lens of over twenty years' standing, and read the following notes:—

J. S., æt. 48, glassblower, was admitted to the Glasgow Royal Infirmary in February, 1895, complaining of cough, spit, slight hoarseness, and pain in the left side. On admission,

Digitized by Google

FIG. 1.—*High power.* Shows well the delicate fibrous meshwork, with the round mononuclear cells lying loose in the stroma. A number of Deiter's cells are also shown. (*Photo. by Archd. Young, M.B., B.Sc.*)

FIG. 2.—*High power.* Shows section of one of the blood-vessels of the tumour, with its perivascular lymphatic sheath infiltrated with leucocytes.

Digitized by Google

[illegible] size, many of them [illegible]

[illegible] graphs by Mr. A[illegible]nd. Y[illegible] two of Dr Wood's [illegible] of the [illegible]cal

FIG. 1.—*High Power.* Shows well the delicate fibrous meshwork, with the round mononuclear cells lying loose in the stroma. A number of Deiter's cells are also shown. (*Photo. by Arnold Young, M.B., B.Sc.*)

[illegible] was told twenty-eight

[illegible] diagnosis was [illegible] The [illegible] be wished to make in con- [illegible] the pain he had complained [illegible] *post mortem* the conversations [illegible] and much [illegible] we not more often [illegible] supply to [illegible] such not to cure? Th[illegible] [illegible]ffen d[illegible] [illegible]at [illegible]f.

[illegible] said that in Dr. Pringle's ward there [illegible] all the symptoms of in[illegible] skull had been trepanned nine months [illegible] pain. Great relief followed, and lasted [illegible] the symptoms returned. The patient [illegible] him to Dr Pringle. Trepanning [illegible] was found but the pain was [illegible]

MEETING VI.—4TH FEBRUARY, 1898.

FIG. 2.—*Low Power.* Shows section of one of the blood-vessels of the tumour, with its perivascular lymphatic sheath infiltrated with leucocytes.

[illegible] OF THE LENS OF OVER TWENTY [illegible]ARS' STANDING.

By Dr. R[illegible]wan.

[illegible] patient with dislocation of the lens of [illegible]ing, and read the following notes:—

[illegible]lower, was admitted to the Glasgow [illegible]ruary, 1895, complaining of cough [illegible] and pain in the left side. On admission,

Digitized by Google

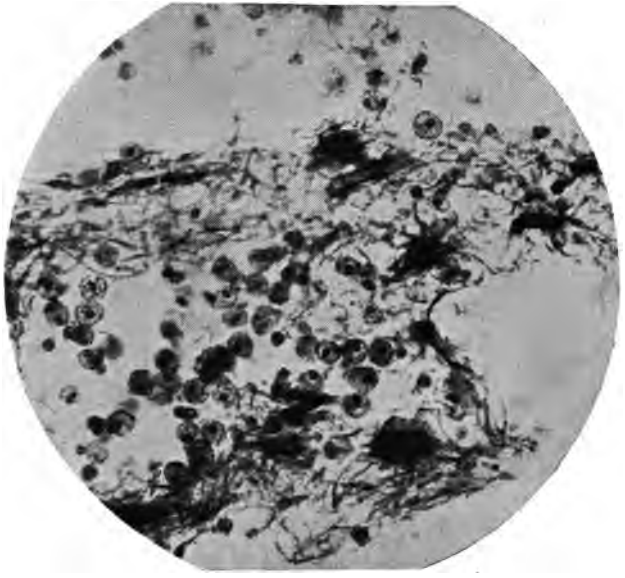

FIG. 1.

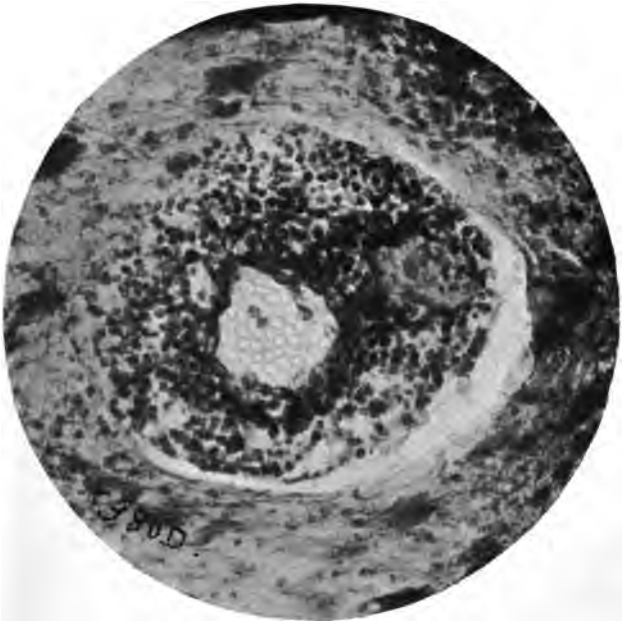

FIG. 2.

Digitized by Google

Digitized by Google

among others, the question of aneurysm was raised, and this at first sight seemed supported by the condition of the pupils, as they were unequal, the left being the larger. I do not think it is necessary to go any further into the patient's general condition, which I may say in passing is one of chronic bronchitis with laryngitis. I bring him before you to-night simply on account of his eyes.

I shall first briefly give you the notes I made on his right eye in February, 1895—*i.e.*, three years ago:—

R.V. = $\frac{1}{8}$ (roughly).
c. + 3D. sph. = J. 2 (with difficulty) at 18 cm.

Eye movements normal.

Pupil reacts to light and accommodation, though somewhat sluggishly.

Ophthalmoscopic Examination.—Pupil dilates somewhat irregularly under homatropine. No adhesions.

Fundus practically normal.

L.V. = $\frac{1}{6}$ (roughly).
c. + 3D. sph. = J. 1 at 18 cm.

Eye movements normal.

Pupil dilated and fixed, reacting neither to light or accommodation. Iris tremulous at nasal side.

This is the eye to which I wish to draw your attention.

Twenty years ago patient was struck on this eye with a raw potato. He consulted no doctor, but applied poultices. He was blind with this eye for three weeks, most probably due to hæmorrhage; but gradually sight returned, though for some years he saw dark streaks, especially when looking into a bright fire, so much so that he sometimes covered it when looking into the furnace. These streaks have long since disappeared. His only trouble now is, when looking into a bright fire he does not see as clearly as he would like. At no other time does he find his eyesight in any way deficient.

This, he states, is the better eye, and he always uses it alone for reading. About this there can be no doubt, for he has removed the right lens from his spectacle frame, as he found the two eyes confused him. On careful questioning, it appears he relies chiefly on his right (the uninjured) eye when at work, but on this point it is very difficult to be certain.

Digitized by Google

Ophthalmoscopic Examination.—The lens is dislocated backwards and to the temporal side. With a high plus glass slight lenticular opacities are seen passing from the upper and temporal side downwards and inwards, also a slight opacity more central. The dark edge of the dislocated lens is seen on the nasal side. The pupil is widely dilated, and by looking between the edge of the lens and the iris with a + 10 D. behind the mirror of the ophthalmoscope some vessels can be distinctly seen on the fundus. This proves the eye to be emmetropic or nearly so.

Ophthalmoscopic examination through the dislocated lens reveals a practically normal fundus. The lenticular opacities are too slight to interfere in any way with the examination. On covering the right eye monocular diplopia is easily demonstrated. A pencil held to the right side is seen with a shadow accompanying it; when held to the left side two pencils are seen; when held centrally and up there is a shadow; and when held centrally and down the pencil is seen as one distinctly. This latter circumstance agrees well with the fact of his using this eye for reading.

Patient was readmitted in December, 1897, when I found a considerable change in this eye. The lenticular opacity was increased, the lens being all hazy, and it seemed more movable than formerly.

Pupil as at former note.

Patient has not been able to read with this eye for over three months.

I again examined him on 25th January, 1898, and on this occasion for the first time had the advantage of a dark room, as formerly I had to examine him as he lay in bed in the ward, which could not be darkened.

While the eyes move well in all directions, there is a tendency now for the left to roll outwards. This is especially noticed when making his eyes converge. After converging for a certain distance the left ceases to do so, and rolls out. This is due probably to the deficiency of sight. There is no corneal astigmatism. Tension normal.

L.V. now = hand movements at temporal side at a distance of 15 cm.; at this distance he counts fingers (?)

He says he got a drop of tar in this eye in July, and that since then it has been gradually getting dark. Since this darkness came on—*i.e.*, about four months ago—he has confused things in artificial light though not in daylight. Thus, when the lamps are lit he sees three objects. This interfered

Digitized by Google

with his work so much that when artificial light was used he covered this eye. Here we have an example of ordinary diplopia plus monocular diplopia.

Part of his work as a labourer (he had to give up his trade about three years ago on account of his general health, not on account of his eyesight) was to lift pipes. This he and another did by putting sticks in. He could do this till about five months ago, when he found he often missed the end of the pipe, putting his stick on the outside instead of in the inside.

About eleven weeks ago it appeared to him as if he were looking through drops of oil, and the sun had the appearance of a rainbow.

Ophthalmoscopic examination shows a large retinal detachment downwards and outwards, seen indistinctly through the hazy lens.

I also examined the right eye on 25th January, 1898, and found eye movements normal, tension normal, 3 D. corneal astigmatism by Javal's astigmometer.

R.V. $= \frac{6}{24}$ (letters).

c. + 2D. cyl. ax. vert. $= \frac{6}{12}$, not improved further by cylinder or spherical.

$= \text{J. } 14.$

$$\text{c.} - \frac{+\ 3\text{D. sph.}}{+\ 2\text{D. cyl. ax. vert.}} = \text{J. 1 at 20 cm. (with difficulty).}$$

Under homatropine the pupil dilates somewhat irregularly; optic disc pale, especially on the temporal side; vessels somewhat small; some pigmentary disturbance at the periphery.

He does not, and says he never did, use tobacco. No specific history made out.

Some points of interest in this case seem to me to be the importance of ophthalmoscopic examination in many, if not in all, medical cases, the apparent support given to the theory of aneurysm by the condition of the pupils being negatived on ophthalmoscopic examination.

Then one wonders why he preferred his injured eye for reading; and what about accommodation? The lens being displaced backwards would have a certain amount of its refractive power reduced—*i.e.*, in proportion to the amount of the displacement. Would this be compensated for, or more than compensated for, by the lens becoming more convex, being free from the suspensory ligament? One must bear in

Digitized by Google

mind, also, that all assistance to accommodation by contraction of the iris was lost.

I regret I had not an opportunity of testing the refraction carefully when I first saw the patient.

Then, again, how has the retina now become detached? There is the history of some tar getting into the eye, but this or any other external ascertainable fact does not seem sufficient to account for the detachment. Of course, the persistent hard cough may have affected an eye already weakened.

He has also lately been troubled with giddiness, sickness, and vomiting; but whether this is of a cerebral origin or not it is at present impossible to say. Has the dislocated lens anything to do with the detachment? And if so, why now after nearly twenty-five years, and not formerly? If one had removed the lens and detachment followed, one would have been inclined to blame the operation. One reason, I think, why he used the left (the injured eye) for reading is the amount of astigmatism in the right, as on correcting this his vision is greatly improved in that eye.

It seems to me that this case has a bearing on the operation of needling the lens for high myopia, as an important question there is—What effect, if any, has the removal of the lens on retinal detachment?

Here we have a displaced lens remaining clear for over twenty years, and detachment only now coming on.

I hope to be able to follow out the case further, but bring it now before the Society as I think in its present condition it may possibly be of some interest to the members.

In conclusion, I have much pleasure in acknowledging my indebtedness to our President, Dr. Middleton, for his kindness in placing the case and his ward journals at my disposal.

Dr. Middleton emphasised the fact that the inequality of the pupils had led at one time to the suggestion of aneurysm as the cause of the laryngeal affection.

Mr. H. E. Clark said it was interesting to find that the lens could remain so long dislocated without undergoing any change, and that the patient could read with the affected eye. Extensive changes were evidently now taking place. The iris was usually tremulous when the support of the lens was lost, as it was in this case on one side. The case was a warning that it was advisable not to remove every dislocated lens.

Dr. Rowan, in reply, said that operation would not be justifiable in such a case.

Digitized by Google

II.—SPECIMEN FROM A CASE OF CHRONIC RENAL DISEASE, ILLUSTRATIVE OF EXTREME HYPERTROPHY OF THE LEFT VENTRICLE.

BY DR. J. LINDSAY STEVEN.

Dr. J. Lindsay Steven showed a specimen from a case of chronic renal disease, illustrative of extreme hypertrophy of the left ventricle. The patient was a lad of 22, admitted to hospital with extreme dyspnœa. The urine was scanty and highly albuminous, and contained fatty and other casts. There was no dropsy. The lad had been a painter for nine years and a spirit salesman for some months. Both occupations might be regarded as factors in the etiology. The radial arteries were extremely rigid. *Post-mortem*, the usual changes were found in the kidneys, and a quite enormous thickening of the walls of the left ventricle was also observed.

III.—CASE OF SPLENIC LEUKÆMIA.

BY DR. J. LINDSAY STEVEN.

Dr. J. Lindsay Steven presented a patient suffering from splenic leukæmia.

A full report of this case, with a clinical commentary, will appear in the forthcoming volume of *International Clinics* (July, 1898). The patient was a Norwegian sailor, aged 18, who, previous to the onset of his leukæmia, had suffered twice from malarial fever, and once from yellow fever. The symptoms and physical signs were characteristic of the spleno-myelogenous type. Specimens of the blood, stained by Dr. W. K. Hunter, were also shown.

IV.—OLIVER'S NEW HÆMOGLOBINOMETER AND HÆMOCYTOMETER.

BY DR. HARRIS.

Dr. D. F. Harris described and demonstrated Oliver's new hæmoglobinometer and hæmocytometer.

The former, he said, was based upon the colour-matching principle of the tintometer, an instrument recently perfected by Lovibond, of Salisbury, for the matching of any colour whatever, and for estimating quantitatively the amount or degree of colour present in any substance, transparent or opaque. A known quantity of blood, received by a capillary pipette, is diluted with water until it fills the mixing cell in

Digitized by Google

which all the hæmoglobin is dissolved out. This cell has a dead white background of porcelain. The diluted blood is then "matched" by comparing it with the standard tints—glasses coloured so that the tints are perfectly non-fugitive—of which standard tints there are six grades of increasing depth of colour. Each grade has been "standardised"—*i.e.*, the percentage of hæmoglobin in the cell full of blood when the blood matches any particular standard tint is known, having been arrived at by chemical analysis of the blood when the standards were being prepared in the tintometer laboratories. The blood-cell and the standards to be compared with it are viewed through a long dark tube in a dark room, candle light being employed. The long tube has two circular apertures in the plate closing it below, so that one sees, on looking down, two brightly illuminated circular areas—the blood to be matched and the standard glass respectively. When the blood matches the standard tint marked 100 degrees it contains 15·5 per cent of oxy-hæmoglobin. Special advantages, besides the dead white background for the colours, are that the illuminant is of standard intensity and of constant chromatic constitution—two properties not to be always found in ordinary daylight.

The principle of the hæmocytometer is, that if one looks across a tube filled with water at, say, a candle-flame, one observes a row of minute images of the flame, due to the longitudinal fibrillations of the glass acting like a series of lenses. If, however, the liquid in the tube be, like blood, full of minute solid particles, one cannot see this row of images until the blood has been diluted down to a certain point. This point differs according to the corpuscular richness of the blood; and the tube has been standardised (by estimating the corpuscles by Gower's hæmocytometer) for the various degrees of dilution of blood at which one just sees the horizontal row of images. Hayem's fluid is used to dilute the blood. Leucocythæmia is the only condition vitiating the results in this instrument.

V.—PERFORATED GASTRIC ULCER.

By DR. R. O. ADAMSON.

Dr. Adamson read a paper on the symptoms of perforated gastric ulcer, with notes of two cases, which has been published *in extenso* in the *Scottish Medical and Surgical Journal* for April, 1898.

Digitized by Google

Dr. James Dunlop said that he was much interested in the paper, as within the last few days he had attended a case resembling in many details those related by Dr. Adamson. His patient presented a history of gastric ulcer followed by general peritonitis. Death followed twenty-two hours after the first signs of perforation. Consent for operation was given too late, as when it was obtained the patient was practically expiring. He wished to draw attention to one symptom—the splashing sound obtained by palpation of the abdomen.

Dr. Middleton had not had much experience of such cases. He could recollect one in which the perforation evidently took place while the patient was breakfasting. Death followed half an hour later. He referred to cases he had recorded in his presidential address, as showing how misleading the symptoms might be. He had no knowledge as to the value of testing for hydrochloric acid in the differential diagnosis of diseases of the stomach.

Dr. Adamson, in reply, said that he might refer to one more point—namely, the variety to be found in cases of perforation of the stomach.

MEETING VII.—16TH FEBRUARY, 1898.

The President, DR. G. S. MIDDLETON, *in the Chair.*

I.—ABDOMINAL SECTION FOR THE RELIEF OF PAIN.

BY DR. RENTON.

Dr. Renton read notes of cases of abdominal section for the relief of pain. His paper included:—

1. Four cases of tubercular peritonitis operated on by incision and drainage, with recovery.

2. An interesting case of adhesion of an unobliterated umbilical vein to the stomach, causing dyspepsia of six years' duration. The vein and adhesions were removed, and the patient obtained complete relief from her symptoms.

3. A case of gastrostomy by Albert's method, the patient being relieved for five months after the operation.

Digitized by Google

4. A case of abscess in the liver, and five cases of cholecystotomy, in four of which calculi were removed. In one case the number of calculi amounted to one hundred and fifty-seven. In the fifth the gall-bladder was drained. Two cases which presented all the symptoms of gall-stones were found to be due to adhesions between the gall-bladder and duodenum. These were separated, with the result that the pain was completely relieved.

5. A reference was made to cases of colotomy, and its early performance was urged as a means of delaying the progress of disease.

Dr. J. H. Nicoll asked whether Dr. Renton would prefer to turn out the intestines on to a sterilised towel, in the process of washing out the abdomen, or to keep them *in situ*. He had found that, if turned out, they were apt to become petechial. With regard to a case of tubercular peritonitis which had been mentioned, he asked whether Dr. Renton considered the large tubercular masses to be situated in the retro-peritoneal glands or in another part of the abdomen. He agreed that the tube described under the second section was probably a branch of the umbilical vein running to join the portal circulation.

Dr. M'Call Anderson, referring to the case of tubercular peritonitis, said that many of these cases recovered, whether treated medically or surgically. In many cases in which there was marked fluid effusion it might be best to open the abdomen, but in some even tapping was sufficient to effect a cure. He thought it might be well to try the effect of aspiration before proceeding to the severer measure. He asked whether, in the cases of adhesion between the gall-bladder and the duodenum, there had been any distinctive feature separating them clinically from cases of gall-stones. Had the jaundice set in gradually and become permanent, or had its onset been like that seen in an attack of gall-stones?

Dr. Walker Downie, who had been associated with Dr. Renton in the case of gastrostomy, said that it was typical of the majority of such cases. Early opening of the stomach had been recommended, but the patient deferred the operation until he was much emaciated. Marked improvement resulted, and some time after the operation he discovered that he was again able to swallow. He died, however, five months later, presenting the symptoms of malignant cachexia. If the operation were performed sufficiently early the patient might live in comparative comfort for a long time.

Digitized by Google

Mr. H. E. Clark asked, with reference to the second section, whether the structure supposed to be the umbilical vein was entirely intra-peritoneal, as the umbilical vein was extra-peritoneal. It was possible that the peritoneal covering might have been separated off. The operation used by Dr. Renton in colotomy was known as Allingham's, and the speaker had himself always used it. It could be done without stitching the intestinal tube to the abdominal wall, but in that case the glass rod might slip out and the bowel fall back into the abdomen. The operation was not useful in cases of imperforate anus, where the bowel had to be returned at a later date.

Dr. Renton, in reply, said that he disapproved of the method of turning out the intestines, although good results had been obtained in one or two cases of severe hæmorrhage. It was possible to dispense almost entirely with washing out in cases of tubercular peritonitis, but his practice was to wash out gently. He thought that in these cases both the glands and the mesentery were affected. It was curious that in this single instance tubercle should disappear as the result of a mere exposure to light. He agreed with Dr. M'Call Anderson that in certain cases tapping alone was sufficient to effect a cure, but it was impossible to be certain that the bowel was not adherent to the peritoneum at the place selected. He had found no distinctions between the symptoms of gall-stones and those of his cases of adhesions. They had occurred in his cases, as in those of gall-stones, in recurrent attacks. Although the umbilical vein was not as a rule intra-peritoneal, he did not know what other structure the tube he had described could represent. To avoid the possibility of slipping of the glass rod, he thought that colotomy cases should be kept slightly under the influence of morphia.

II.—SPECIMENS.

BY DR. RUTHERFURD.

Dr. Rutherfurd showed the following specimens:—

1. Intra-peritoneal rupture of bladder from a woman; sutured. The specimen is in the museum of the Royal Infirmary.

2. Sections of the common iliac artery at the seat of ligature, which had been performed six weeks previously by Crampton's posterior incision. This was a case of secondary hæmorrhage from the branches of the internal iliac, resulting

Digitized by Google

from acute osteomyelitis of the ilium. The common iliac was ligatured, and this operation was followed four days afterwards by amputation at the hip. The patient, a boy of 15, died from pyæmia.

3. The *débris* of an uratic calculus, weighing 60 grs., successfully removed by litholapaxy from a boy aged 6.

4. A lobulated lymphangeioma (hygioma) with highly vascular walls, removed from the lumbar region. It had simulated spina bifida. Photographs of the patient were shown. The specimen is in the museum of the Royal Infirmary.

Mr. H. E. Clark said that the second case was remarkable for the endurance with which many operative procedures had been undergone in association with chronic septic processes. He expressed his admiration for the success of the operation of ligature, the wound having healed by first intention. The case of rupture of the bladder was very interesting. To be effective, the operation should be as prompt as possible. Mr. Rutherfurd's difficulties had been those always experienced where a case is brought in late. It was unfortunate that such cases, should they die on the table, were often registered as deaths under chloroform, the true cause being the almost hopeless condition of the patient, and the operation a courageous attempt to save life in the last extremity.

MEETING VIII.—4TH MARCH, 1898.

The President, DR. G. S. MIDDLETON, *in the Chair.*

I.—CASE OF ACUTE SYMPTOMS OF INTRACRANIAL PRESSURE, CURED BY TAPPING THE LATERAL CEREBRAL VENTRICLE.

BY DR. NICOLL.

Dr. Nicoll showed a patient who suffered from acute symptoms of intracranial pressure, cured by draining the lateral cerebral ventricle.

G. F., æt. 21, on 29th June, 1897, while carrying a heavy iron casting on his shoulder, tripped and fell. His forehead struck the ground, while his skull at the same time received

Digitized by Google

a blow behind, near the occipital protuberance, from the piece of metal on his shoulder. This was followed by smart epistaxis and a condition of concussion which lasted for some hours.

For a fortnight he was confined to bed, suffering from headache, recurrent epistaxis, and giddiness. Over the junction of the nasal and frontal bones anteriorly, and over the occipital bone posteriorly, there was tenderness, and in the latter situation there was some swelling for a time. At the end of

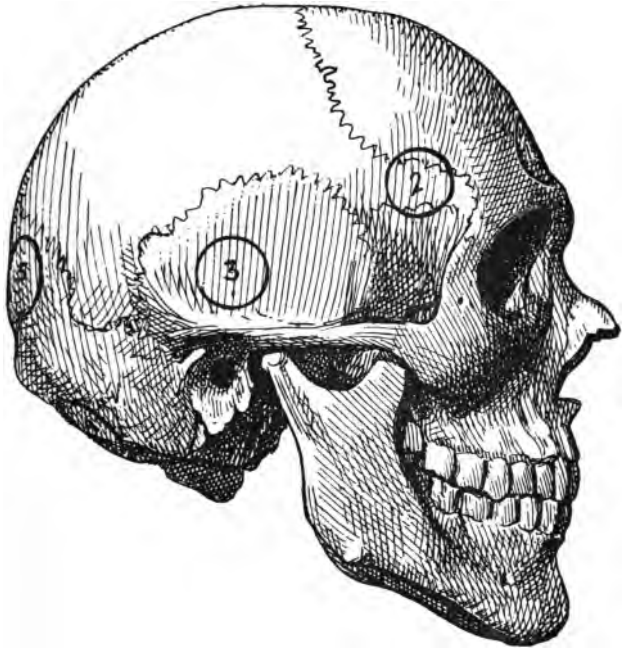

the fortnight he gradually, within a few days, regained his normal condition, and for about two months was fairly well, except that he occasionally felt giddy when stooping and had occasional epistaxis.

On 15th October, three and a half months after the accident, his condition changed. He suffered from severe pain in the right frontal region, marked giddiness, and a tendency to frequent vomiting. These symptoms increased in severity till 25th October, when I saw him in consultation with Dr. John Barr Stevens. At that time his condition was, briefly, as

Digitized by Google

follows:—Temperature practically normal; pulse, 62; severe and constant pain in right frontal region. The slightest movement, even turning the head on the pillow, produced instant giddiness and frequently resulted in vomiting. The patient appeared dull, and lay very still, possibly more from the desire to avoid the giddiness and vomiting consequent on any exertion than from commencing coma, though Dr. Stevens, who had full opportunity of observing his condition, is of opinion that at this time there was a tendency to stupor and commencing coma. His speech was slow and hesitating. There was no paresis or spasm of face, arms, or legs. There was no optic neuritis. His nasal bones were loose and "rocking" on the frontal bone.

On 28th October, his condition being unchanged except that there was distinctly more stupor, it was decided to explore the interior of the skull for the source of pressure. There being present only general symptoms of intracranial pressure, without any definite localising evidence, I was guided in my decision to explore the frontal region by the presence of pain there and by the loose condition of the nasal bones. Discs of bone, 1 inch in diameter, were removed from the sites marked (1) and (2) in the accompanying diagram. The dura in both places presented no bulging, and pulsated normally. In both sites the dura was incised, and the brain explored to the depth of 1½ inch by means of Macewen's cannula, with negative result. The effect of the operation was a slight diminution of pain and giddiness for a few days, after which the patient relapsed into his former condition with deepening stupor.

On 9th November I again saw him with Drs. W. G. and J. B. Stevens, when it was decided to explore farther. I removed a 1 inch disc of bone in site (3) in the diagram, and found the dura over the temporo-sphenoidal lobe bulging and pulseless. On incising it, the subjacent cortex appeared pale, pulseless, and bulging. Exploration with the cannula in three different directions, to the extent of 1 and 1½ inches, gave no result, but on pushing the cannula in the direction of the ventricle, it entered that cavity and evacuated a considerable quantity of fluid, the amount of which, however, could not be ascertained. With the object of discovering the possible source of this distension of the ventricle, in the shape of abscess, hæmatoma, or tumour pressing on the veins of Galen, I removed 1 inch discs of bone in site (4), over the cerebellum, and site (5), over the occipital lobe, and explored

Digitized by Google

both cerebellum and occipital lobe with the cannula. The result was negative.

From that date the patient made an uninterrupted recovery, and is now well.

Three things have induced me to think the case of sufficient interest to bring before the Society.

1. *The diagnosis.*—It is not uncommon for acute distension of one or both lateral ventricles to follow from blocking of the veins of Galen, the result of the presence in cerebellum or occipital lobe of abscess, hæmatoma, or tumour. In this case, however, both the subsequent negative exploration of cerebellum and occipital lobe and the patient's perfect recovery go to exclude that possibility.

Amongst the various possible explanations of the distension of the ventricle, perhaps the most probable in this case is that the vein of Galen draining the right ventricle was obstructed by thrombosis originating in some way from the injury received at the time of the fall.

2. *The extent of the cerebral exploration carried out.*—Though not the most extensive exploration of the encephalon I have carried out, it is the most extensive exploration of one hemisphere I have yet had to undertake, and when it is recollected that from each of the five trephine apertures the cannula was passed in two and three directions into the brain for distances varying from 1 to 2 inches, it will be seen that the interference with the brain was considerable.

As consulting surgeon to the Ear Hospital, when on duty in Professor Macewen's wards in the Western Infirmary, and in private practice, I have frequently had occasion to explore the temporo-sphenoidal lobe and cerebellum on one side, and in some cases, in addition, the occipital lobe. In several cases which have been under my care I have explored one or other or several of these sites on both sides. In this case, however, there has been added the not very common exploration of the frontal lobe.

Practice has advanced with great rapidity of late years in cerebral cases. There must be a limit to interference with the brain. With a knowledge of the anatomy of the brain and strict asepsis, however, it is not yet clear where the limit of successful interference with the brain is to be placed.

3. *The method of dealing with the discs of bone removed.*—Much has been written, and opinions widely differ, as to the

Digitized by Google

best method of dealing with bone removed from the skull in the matter of providing the most efficient protecting covering for the brain. The principal methods advocated are—(*a*) Leaving the bone removed unreplaced, on the ground that if replaced it either necroses or undergoes absorption. In this method the brain is protected by the dura, pericranium, and scalp fused together. (*b*) Breaking up the discs removed into small portions and implanting these on the sutured dura in the gap. In this method, these portions of bone are said to grow and firmly fill the gap. (*c*) Splitting the disc into two lamellæ and replacing one only. The supporters of this method assert that the thin lamella of half the thickness of the disc is more easily vascularised, and therefore less likely to necrose than the thicker plate formed of the entire disc. (*d*) Replacing the entire disc.

In this case I followed the method I have always practised —viz., replacing the entire disc. In this case the discs were not even kept in warm solution. They were laid between folds of dry sterilised gauze till the operation was over, then replaced, and the scalp sutured over them. The wounds healed by first intention under the original dressing. As you may see, all five discs are, four months after operation, firmly united *in situ.*

With the two objections urged against replacing the entire discs—viz., the risks of necrosis during healing, and of remote absorption—it is not easy to deal without some knowledge of the circumstances in which these untoward results have occurred. I have not seen absorption occur, and I have lately inspected three cases where the entire disc had been replaced ten, seven, and six years ago respectively. In none of these can I detect any evidence of absorption. It is not easy to follow up one's cases, however, more especially hospital cases, and in the meantime, until I have been able to extend my observations, I should wish to reserve final judgment. Whether subsequent absorption of the disc, granting it to be at all common, constitutes any argument against replacing it, is another matter. It would appear that what remains of the absorbed disc uniting with the fused dura and pericranium should tend to increase the protecting covering of the brain.

Necrosis of the replaced disc is also an occurrence of which I have had no personal experience. Over a now very considerable number of cases I have not, if I may trust my notes and memory, seen it once. In the records of cases in which it has occurred, and in the observations of certain writers, there is evidence that the main, if not the only, cause of

Digitized by Google

necrosis of the disc is sepsis. Should anything be permitted to interfere with the strictly aseptic condition of such a wound, it could hardly be matter for surprise should necrosis of the disc result.

Dr. Newman said that if fracture of the frontal bone were presupposed, it was possible to understand a thrombosis of the longitudinal sinus. If the veins of Galen were obstructed the effusion would probably be continued, and would reaccumulate after surgical interference, although absorption of an obstructive clot might have followed the operation.

Dr. Barr Stevens said that the man lay habitually on his right side with the face turned down. After the operation he was able to roll round to his left side. The symptoms had disappeared very gradually.

Mr. Maylard said that he always put back the whole disc removed by the trephine except in cases of intracranial pressure, where he split and then replaced it. A year or two ago he had trephined over the seat of an old disc, and found it atrophied all round the margin. The result depended in part on the kind of trephine employed. Atrophy was more liable to occur if a bevelled-edged trephine were used.

Dr. Nicoll, in reply, said that the posterior part of the skull had perhaps been more seriously injured than the anterior. The explanation of the symptoms which he had offered had been merely conjectural. He always used a parallel-sided trephine.

II.—FOUR CASES OF TUMOUR OF THE BLADDER.

BY DR. NEWMAN.

Dr. Newman showed four cases of tumour of the bladder treated by operation.

Tumours in the bladder differ from growths in most other situations in the circumstance that whether malignant or benign, if left alone, they invariably lead to a fatal termination, whether from hæmorrhage, or pain, or obstruction to the passage of urine, or from all those conditions combined.

From a clinical point of view, therefore, a papilloma of the bladder may be almost as rapidly fatal from hæmorrhage as an epithelioma. The surgeon is therefore bound in all cases where a tumour of the bladder is suspected to clear up the diagnosis by a cystoscopic examination, and, if the case be suitable, to remove the tumour at the earliest date. And

Digitized by Google

when this cannot be done, free escape should be given to the urine by a perineal or suprapubic operation in the male, or in the female by dilating the neck of the bladder; in this way serious hæmorrhage may be prevented, and rest afforded to the diseased parts.

No very accurate and exhaustive classification of tumours of the bladder has yet been made. Sir Henry Thompson has given a classification; he divides tumours of the bladder into three classes:[1] "Those which consist only of elements identical with the normal tissue of the bladder, 'homœoplastic,' and those which consist, more or less, of other elements never found in the tissue of the healthy bladder, or 'heteroplastic.'" The former may be regarded as benign growths, and under this heading he places the "fimbriated papilloma" and the "fibro-papilloma." Under the second head are placed malignant tumours—namely, epithelioma, scirrhus, encephaloid; but, as if there was some doubt in the accuracy of this classification, he places between these two great groups what he calls "tumours of a transitory type," which appear to occupy a position between the papilloma and the epithelioma.

Then he has what are called "dermoid tumours." This classification is clearly very incomplete and very imperfect; it does not include, for example, such tumours as myoma, angioma, fibroma, enchondroma, cysts, and the sarcomata.

The symptoms of papilloma of the bladder are well known, and are generally so definite that little difficulty is experienced in forming a diagnosis. The most prominent symptom, as a rule, of papilloma of the bladder is hæmaturia. In some instances, indeed, this is the only symptom beyond obstruction to the exit of urine. The most characteristic feature of the hæmaturia is that the urine first passed may be clear, or only slightly tinged with blood, while towards the end of micturition it is a bright red, and the last few drops of the stream are almost pure blood. This is no doubt produced by the contraction of the wall of the bladder against the delicate villi of the growth, which are soft and pultaceous by being constantly exposed to the action of the urine. Another characteristic of the hæmaturia in papilloma is that the hæmorrhage is increased very considerably by any exploration of the bladder.

Many methods have been proposed to assist in the diagnosis of tumour in the bladder—exploration by the finger through the urethra in the female or through a wound in the perineum in the male, sounding the bladder, and careful examination of

[1] *Tumours of the Bladder*, by Sir Henry Thompson, London, 1884, p. 56.

Digitized by Google

the urinary deposits. When one reads Sir Henry Thompson's description of how exploration of the bladder with the finger should be carried out, the marvel is that the injury done to the patient was not appalling. He introduced the *left forefinger* into the rectum as a guide to the incision of the bladder; and when the incision was completed, the same finger (*the left index*), without being cleaned, was used in exploring the bladder. Sir Henry Thompson[1] went further than this, and proposed that portions of a growth might be removed from the main mass by means of a lithotrite, and submitted for microscopic examination, surely overlooking the fact that the pieces of a growth removed by a crushing instrument must have lost their histological characteristics, and hence been rendered valueless for diagnostic purposes.

None of these methods are so satisfactory as the use of the cystoscope, which in the great majority of cases can be employed, unless when the tumour is very large or where it occupies the neck of the bladder, so that bleeding is certainly produced by the introduction of the instrument. The four cases about to be described were easily diagnosed by the cystoscope. The use of the instrument, however, requires some patience and perseverance before one becomes expert in its use, and in recognising the conditions present. Nitze's or Leiter's instruments are most valuable, as with a good light they give a very perfect view of the interior of the bladder. I have had considerable personal experience of the latter instrument, and have always found it most satisfactory. Howard Kelly's cystoscope is not suitable for general exploration, as with it the bladder is examined empty, while with Leiter's cystoscope the bladder is dilated with from 6 oz. to 8 oz. of aseptic clear fluid.

CASE I.—*Papilloma of the bladder the size of a Tangerine orange, removed by suprapubic operation and écraseur—Complete recovery.*

R. S., aged 53. The most interesting point in this case is that, while the patient must have had a large growth in his bladder for a considerable length of time, he complained of no symptoms until within three weeks of admission to the Royal Infirmary on the 15th of March, 1897, and at that time the only symptom which troubled him was hæmaturia. The hæmaturia was, however, quite characteristic, and varied greatly in amount from time to time, and on some occasions the urine was quite clear until the end of micturition, when

[1] *British Medical Journal*, 1890, vol. ii, p. 332.

Digitized by Google

almost pure blood was passed; on other occasions the hæmaturia was very profuse, and clots of considerable size were passed. Examination with the cystoscope revealed a large growth, like a small pink cauliflower, situated to the left of the middle line and about half an inch above the orifice of the left ureter. With the exception of some enlargement of the prostatic veins, the bladder was normal in appearance. On the 15th of April the bladder was opened by median suprapubic incision, and by means of a chain écraseur the tumour was removed; and after the bulk of the growth had been taken away, the base to which it was attached was scraped with a Volkmann's spoon and cauterised with the electric cautery.

On the 18th of May the patient was dismissed well, and since the operation there has been no recurrence of the hæmorrhage or any symptoms of irritation of the bladder. The bladder has been examined by means of the cystoscope on two occasions since the operation, and all that can be seen is a small scar about the size of a threepenny piece at the site occupied by the tumour, and the patient is now (2nd March, 1898) able to retain 15 oz. of urine.

CASE II.—*Small papilloma of the bladder removed through urethra by electric écraseur.*

M. E., a female, aged 43, was admitted to the Glasgow Royal Infirmary on the 18th November, 1892, complaining of hæmaturia which had lasted during four months. At the onset of the disease the hæmaturia was slight, but a day seldom passed without her observing some blood in the urine, and within the fortnight previous to admission the quantity of blood was much larger than at any previous time. She also suffered from considerable irritation of the bladder, and considerable straining at the end of micturition. She was very pale from loss of blood, but on questioning her it was evident her health had never been very robust, and on examination of the back, Pott's curvature was observed in the lower dorsal region. Besides containing blood, the urine also deposited a small quantity of pus, but otherwise there was no other evidence of any disease of the urinary tract.

On the 20th of November the patient was placed under chloroform, and an attempt made to explore the bladder with the cystoscope, but it was found she was unable to retain more than 2 oz. of fluid. Hot fomentations were applied, rest was enjoined, boracic acid was administered three times a day

Digitized by Google

in 2-grain doses, and the patient was placed upon milk diet and barley water. Gradually the irritation of the bladder diminished, and its ability to retain urine was considerably increased, so that by the 21st of December the patient could retain over 8 oz. of urine without difficulty. The bladder was then washed out carefully and explored, when a papilloma about the size of a horse-bean was found to the inner side of the right ureter. The bladder was then emptied of its fluid contents, and a Howard Kelly's cystoscope was introduced. With a little difficulty the wire of an electric écraseur was hitched round the tumour and the growth was removed, and the base afterwards was cauterised. A little blood continued in the urine for three days after the operation. The patient was dismissed on the 19th of January, 1893, and from then till 3rd August, when the patient was last seen, no recurrence of the symptoms has been noticed.

CASE III.—*Angioma of the bladder cured by electrolysis—Pyelitis and cystitis.*

Mrs. F., aged 39, was admitted to the Glasgow Royal Infirmary on the 11th of April, 1893, complaining of pain in the left renal region and in the bladder, also frequent micturition and hæmaturia. The history of the case was a very long one, but it is not necessary to give it in detail.

The illness dated back for fifteen or sixteen years. She first complained of a dull aching pain in the left lumbar region, especially after heavy work, and after some time the pain was associated with a sense of swelling in the left kidney, but otherwise there were no symptoms pointing either to a hydronephrosis or a pyonephrosis.

The pain in the bladder came on gradually about three years previous to admission, and has steadily increased since the onset. On admission the patient was pale and emaciated. The dull heavy pain in the left side is increased by pressure, and on palpation a distinct firmness and increased muscular resistance can be made out in the left side, and the renal dulness is slightly increased. The urine contains a considerable quantity of pus and blood, but nothing characteristic could be made out on questioning her regarding the nature of the hæmaturia. The patient gave a history of a former pain in the kidney shooting down the groin and attended with blood in the urine, and a feeling of something having dropped into the bladder; but her statements were too vague to draw any conclusion therefrom.

On the 27th of April the bladder was examined with the

Digitized by Google

cystoscope, when its wall was found to be roughened and deeply injected; there was a swelling seen close to the orifice of the left ureter, and this on closer inspection was made out to be an angioma about the size of a small cherry, and presented the appearance of a fully ripe bramble. After the bladder was explored by a Leiter's cystoscope, it was emptied, and a Kelly's cystoscope was introduced, through it two electrodes were passed, and coagulation of blood in the vessels of the angioma was induced by electrolysis. This was applied three times in all—on the 27th of April, the 2nd of May, and the 17th of May, and when the bladder was again examined on the 26th of May the growth was found to be completely contracted. No hæmaturia was observed after the 8th May. The patient reported herself well, as far as the hæmaturia was concerned, on the 1st of July, 1893, and on the 7th of January, 1896; at the latter date no growth could be seen with the cystoscope, but the cystitis was still occasionally troublesome.

CASE IV.—*Sarcoma involving the base of the bladder and rectum—No operation.*

J. S., aged 45, was admitted to the Royal Infirmary on the 18th October, 1897. The following is the report from the ward journal:—

"Complaining of passing bloody urine and of pain shooting up from either testicle during micturition. This pain is of fully twelve months' duration, and is only felt during micturition and for a very short time after. The pain is in both testicles, and passes upwards in the direction taken by the cords, but never goes so high as the level of the umbilicus. It is most severe at the onset of micturition. Eight months ago the urine became bloody, more deeply red towards the end of micturition, and frequently clotted. Usually slight pains for a day prior to the hæmaturia in the vesical region. The blood continued in the urine for about a day, and from that time he has had a similar attack each week, sometimes two in the week. The stream of water is interrupted five or six times before the bladder is emptied; also, he has had within the last five months several attacks of aching pain in the left side just below the ribs in front. This pain has never been very severe, and continues for about a day at a time. These attacks were not accompanied by any unusual blood in the urine; in fact the urine was frequently free from blood during and for some time after these attacks. Of late he has also felt, specially if

Digitized by Google

making a sudden movement, a pain pass down the front of the right thigh. There is a large tortuous varicose vein on the right leg. Enquiry gives no history of syphilis. He is subject to rheumatic pains in his shoulders. He was perfectly healthy until the present illness began.

"To-night the patient complains of slight pain in both testicles, and there is some tenderness on pressing over the bladder just above the symphysis. The glands in the groin are somewhat enlarged. To-day the urine is acid, dark amber, and contains a quantity of albumen. The reaction for blood with guaiacum is present. Red blood corpuscles are present in the deposit, but no tube-casts.

"*21st October.*—The quantity of urine passed in last twenty-four hours amounts to 34 oz. The amount of blood has increased since Dr. Newman passed the catheter, and a few pus corpuscles are present as well as an odd crystal of phosphate of lime. The bowels since yesterday have moved five times, and the motions have contained a considerable quantity of blood. Examination of bowels reveals no tumour, but high up a few mucous folds are felt. (Dr. Jackson, house surgeon.)

"*26th October.*—Examination of the blood to-day shows no excess of white blood corpuscles, but the red corpuscles show a tendency to form into clumps rather than into *rouleaux.* Hæmoglobin exists to about 55 per cent, and red corpuscles 57 per cent. There is now no blood coming away with the motions.

"*29th October.*—Dr. Newman tried again to use the cystoscope, but the amount of blood was so great that it has been postponed. Quantity of urine passed each day varies from 40 to 60 oz., and it still contains a large amount of blood, even more than on admission. No tube-casts have been detected.

"*3rd November.*—The blood has now entirely disappeared from the motions. The bowels have lately shown a tendency to be constipated, and defæcation is still very painful. Pain in the testicle, complained of at first, seldom troubles him now, but he complains of a pain passing up and down his right thigh from the hip to the knee, and sometimes passing down to the foot. Palpation over the bladder region gives some tenderness, specially on the right side, where there is great increase of muscular resistance. Abdomen here seems also to be slightly swelled.

"*4th November.*—For last few days there has been less blood in the urine, but to-day again it is very abundant

Digitized by Google

Microscopic examination reveals nothing beyond red blood corpuscles and pus cells.

"*15th November.*—To-day, on again examining the rectum, a large bulging is detected projecting the anterior wall of the rectum backwards, and apparently growing from the bladder and prostate. Dr. Newman is of opinion that this is a sarcoma growing from the base of the bladder. Patient's general condition is much worse. Blood still comes away freely with the urine. Dr. Newman is of opinion that operation could only hurry on the death of the patient; and he went home to-day."

In this case the tumour evidently occupied the neck of the bladder, and when the instrument was passed profuse hæmorrhage supervened. It was impossible at any time to get a view of the interior of the bladder, but with a sound in the bladder and the finger in the rectum the form and limits of the tumour could be easily ascertained.

Dr. Fleming asked how the pedicle was dealt with. The reply was that it was removed by the écraseur, and the base was cauterised. The resulting cicatrix was about the size of a threepenny piece.

Dr. Nicoll emphasised the value of the cystoscope, and said that in the use of the cystoscope one must be prepared to examine several times, and must have permission to use an anæsthetic if it were required.

Dr. Fleming said that if cocaine were properly used an anæsthetic was unnecessary. He had often employed hazeline lotions previously to the cystoscope in order to obviate hæmorrhage.

Dr. M'Call Anderson said that he had once passed for insurance, as a first-class life, a man who had been operated upon ten years ago for tumour of the bladder, and was perfectly well at the date of the examination. The head office had demurred to his decision. He wished to know whether Dr. Newman agreed with them.

Dr. Newman, in reply, said that the cystoscope required as much education as the ophthalmoscope. Hæmaturia was the great obstacle to be encountered, and it was often necessary to make repeated examinations. The risk incurred was not greater than that of passing a large bougie. He agreed with Dr. Fleming as to the value of cocaine, and personally employed a cocaine antrophor. He objected to the injection of cocaine into the interior of the bladder, as it altered the

Digitized by Google

appearances to a certain extent. He thought it quite safe to pass a patient as a first-class life ten years after the removal of a papilloma.

III.—MALFORMATIONS OF THE KIDNEY AND DISPLACEMENTS WITHOUT MOBILITY, WITH ILLUSTRATIVE CASES.[1]

BY DR. NEWMAN.

Now that many of the diseases of the kidney come to be placed under the surgeon for treatment by operation, all departures from the normal, whether in respect to number, form, size, or situation, must be considered of moment to those who have frequently to operate upon the renal organs.

Malformations and displacements of the kidney may be classified under the following heads:—

I. *Displacements without mobility.*—1. Congenital displacement without deformity. 2. Congenital displacement with deformity. 3. Acquired displacements.

II. *Malformations of the kidney.*—1. Variations in number. —(1) Supernumerary kidney; (2) single kidney—(*a*) congenital absence of one kidney, (*b*) atrophy of one kidney; (3) absence of both kidneys. 2. Variations in form and size.—(1) General variation in form, lobulation, &c.; (2) hypertrophy of one kidney; (3) fusion of two kidneys—(*a*) horse-shoe kidney, (*b*) sigmoid kidney, (*c*) disc-shaped kidney.

III. *Variations in pelvis, ureters, and blood-vessels.*

I. DISPLACEMENTS WITHOUT MOBILITY.

1. *Congenital displacement without deformity.*

CASE I.—Fixed displacement of the right kidney above Poupart's ligament, simulating a perityphlitic abscess.

There was a slight fulness of the abdomen in the right iliac and lower lumbar regions, and a rounded swelling was felt passing upwards and backwards. It occupied an area of about 2 inches in breadth, running parallel with Poupart's ligament. The swelling simulated an abscess in its physical characters, but on being incised was found to be a misplaced kidney.

[1] The paper was illustrated by cases and specimens which had come under Dr. Newman's observation during the last twenty years. The specimens were shown at the meeting and illustrated by diagrams.

Digitized by Google

CASE II.—Left kidney displaced downwards and forwards in a patient on whom lumbar colotomy was performed.

The lower border of the kidney was found immediately above the centre of the crest of the ileum, at the lowest limits of the colotomy incision. The organ was slightly lobulated, but normal in size.

CASE III.—Right kidney displaced downwards, and rotated on its antero-posterior axis, shortened ureter entering upper aspect of the bladder.

The convex aspect of the organ rested upon the brim of the pelvis, while the concave surface looked upwards. The right ureter was shortened, and entered the bladder close to the upper aspect of that viscus.

2. *Congenital displacement with deformity.*

CASE IV.—Right kidney at the brim of the pelvis, anomalous distribution of blood-vessels, and deformity of the kidney.

The kidney lay on the brim of the pelvis below the bifurcation of the aorta, and was supplied by two arteries, one directly from the aorta, and a second one from the common iliac artery.

CASE V.—Malposition of both kidneys, one to the right of the promontory of the sacrum, the other to the iliac fossa. The right kidney small and with no hilum.[1]

CASE VI.—Right kidney flat, oval in form, and situated at the brim of the pelvis, supplied by two arteries and one ureter from the anterior aspect.

Right kidney a flat, oval body, about the normal size, supplied by two arteries from the aorta just above the bifurcation, right renal vein passing to vena cava. The ureter from the anterior aspect. Left kidney normal in size, but lobulated slightly.

3. *Acquired displacements of the kidney.*

CASE VII.—Acquired displacement of the right kidney by a perinephric abscess.

The kidney with its convexity looking upwards and lying close to the diaphragm, while the pelvis was turned downwards. The organ firmly fixed by inflammatory adhesions. Renal vessels and ureter elongated.

[1] Newman, *Surgical Diseases of the Kidney*, p. 7.

Digitized by Google

II. MALFORMATIONS OF THE KIDNEY.

1. *Variations in number.*—(1) *Supernumerary kidney.* One case of supernumerary kidney was described. (2) *Single kidney*—(*a*) Congenital absence of one kidney.

CASE VIII.—Complete absence of the left kidney, ureter, and vessels; compensatory hypertrophy of right kidney.

The right kidney normal in position, but weighed 12½ oz., and measured 5 inches in length and 4 inches in breadth. No trace of the left kidney or its vessels and ureter, and no opening into the bladder corresponding to the entrance of the left ureter.

CASE IX.—Congenital absence of the left kidney, vessels, and ureter, placed in the museum by Dr. J. Lindsay Steven, and almost exactly the same as Case VIII.

(*b*) Atrophy of one kidney.

CASE X.—Extreme atrophy of the left kidney, with double pelvis, but single ureter.

The organ about the size of a walnut, the pelvis is branched, and there is no hilum. The upper limb of the pelvis springs from the inner and upper aspect of the atrophied organ, while the lower arises from the lower border. Both limbs unite about 1½ inch below the level of the kidney.

CASE XI.—Atrophied kidney, the renal tissue being almost entirely replaced by fat. Left kidney weighed half an ounce. Very little renal tissue could be found in the mass, and what remained was completely embedded in firm fat. The right kidney was the seat of advanced chronic interstitial nephritis.

CASE XII.—Atrophy of the right kidney, with compensatory hypertrophy of the left kidney, disease of the suprarenal capsules.

The right kidney weighed only 1 oz.; the left, 7½ oz. The atrophied kidney was embedded in a mass of adipose tissue, and contained four cavities filled with pultaceous material. Ureter thickened, and its lumen obliterated.

Absence of both kidneys has only been observed in the lower grade of monstrosities, especially acephalous monsters.

Digitized by Google

2. *Variations in form and size.* (2) Hypertrophy of one kidney.

CASE XIII.—Simple hypertrophy of the left kidney only, right kidney normal in size and appearance.

The left kidney weighed 10¾ oz., and the right weighed 6½ oz. In all respects the hypertrophied organ was healthy.

(3) *Fusion of two kidneys*—(*a*) Horse-shoe kidney.

CASE XIV.—Horse-shoe kidney united by an isthmus of fibrous tissue at the level of the bifurcation of the aorta. Renal form well retained.

CASE XV.—Horse-shoe kidney with lobulation and complete fusion of both kidneys. Malformation of the pelves, and anomalous distribution of blood-vessels.

CASE XVI.—Horse-shoe kidney with complete incorporation of the two organs, lobulation of both segments. The ureters were deformed, and anomalous distribution of blood-vessels.

(*b*) Sigmoid kidney.

Case of Dr. L. R. Sutherland. Complete fusion of two kidneys in sigmoid form; the upper hilum presents antero-internally, the lower anteriorly. The upper ureter united at the right, the lower at the left angle of the trigone, and the renal mass occupied the right lumbar region.

(*c*) Disc-shaped kidney.

The hilum faced anteriorly and antero-internally. Two distinct pelves, one above the other. The lower ureter faced to the right of the trigone, the upper ureter to the left.[1]

Dr. Newman also referred to various anomalies in the pelvis, ureters, and blood-vessels, as illustrated by cases observed in the Royal Infirmary.

[1] Royal Hospital for Sick Children Museum.

Digitized by Google

MEETING IX.—18TH MARCH, 1898.

The President, DR. G. S. MIDDLETON, *in the Chair.*

I.—CASE OF EXOPHTHALMIC GOITRE WITH UNILATERAL EYE SYMPTOMS.

BY DR. HINSHELWOOD.

Dr. Hinshelwood showed a case of exophthalmic goitre with unilateral eye symptoms. His paper on the subject has been fully reported in the *British Medical Journal* for 25th June, 1898.

Dr. W. K. Hunter thought there must be a connection between Graves' disease and the sympathetic nerve, as many cases of benefit had been reported to follow upon section of the nerve. The ocular symptoms might be accounted for by a peripheral lesion of the nerves.

Dr. Edington asked if there was any explanation of the abduction of the left eyeball on putting the inferior rectus into play. The eyeball was distinctly abducted when the patient looked downwards.

Dr. Hinshelwood replied that paresis of the internal rectus might be superadded to the other symptoms of the disease.

Dr. W. S. Dun said that this was the first case he had seen in which the affection was unilateral. One such case was mentioned by Trousseau. He had suspected Graves' disease in a recent case of his own, where there was no exophthalmos but marked enlargement of the thyroid gland. The case had improved under thyroid extract, and relapsed when it was stopped.

Dr. Hinshelwood, in reply to Dr. Hunter, said that he did not deny the importance of the sympathetic nerve as a factor in the etiology, but an affection of that nerve could not account for all the symptoms.

II.—ON THE TREATMENT OF STRABISMUS, WITH SPECIAL REFERENCE TO THE ADOPTION OF ADVANCEMENTS FOR CONVERGENT SQUINT.

BY DR. FREELAND FERGUS.

The subject of squint is, from the nature of things, a complex one; the causes of it are various, and its forms are numerous;

Digitized by Google

hence, it is not a simple matter to discuss, in a single night, the treatment of all its forms, nor shall the task be attempted. In the following remarks an endeavour will be made to deal with a few typical examples.

1. In certain persons the affection is the result of an error of refraction. This is especially true of concomitant squint occurring with hypermetropia, or with hypermetropic astigmatism, in one or in both eyes.

2. In others it is the result of an amblyopia in one eye. Instances of this are seen when the formation of an opacity of the cornea leads to strabismus, or when the affection results from cataract of one lens, or from other diseases seriously impairing the visual acuteness, as separation of the retina, atrophy of the optic nerves, &c. In these cases the deviation of the eyes is generally in the direction of divergence, although, for reasons which cannot here be discussed, there is occasionally convergence.

3. Then, again, it is sometimes due to paralysis of a single muscle or of several muscles in one or in both eyes.

4. In addition we must add to this catalogue those cases generally included under the name of heterophoria. These, in former days, were usually classed under the title of muscular insufficiencies. Most men who have studied the question have come to the conclusion that, because the muscle supposed to be involved cannot, as a rule, be shown to be altered either in structure or in its origin and insertion, the name muscular insufficiency is, for the most part, a misnomer. Hence the new name heterophoria.

5. Closely allied to the amblyopic squints are those in which the optical conditions are such that one eye has not for ordinary distances useful vision while the other has. Thus, one eye may be emmetropic, the other myopic. As will be seen presently, there is in these cases no impulse towards binocular fixation, and hence there is squint.

We have, perhaps, in these remarks not included all forms of strabismus, but those mentioned are the important varieties, and are sufficient for our purpose.

Another classification of strabismus is possible, and at this stage probably advisable. Some cases are absolute, others are relative.

By strabismus is meant a want of symmetry in the visual axes of the eyes. Thus, when a person with this affection looks at a distance the optical axes of his eyes may not be parallel. When he looks at a near object one eye may be

Digitized by Google

directed properly to the object, the other may not. It may, for example, converge too much, or it may diverge.

By absolute strabismus is meant that for no fixation point is there symmetry of the visual axes; by relative, that in some positions there is, and that in others there is not. The most familiar example of absolute strabismus is the concomitant form which is often associated with hypermetropia. Let the fixation object be placed in any position, then one eye is directed properly towards it while the other converges too much. Moreover, the angle between the visual axis of the eye which is properly directed and that of the eye which converges too much is within certain limits a constant.

Of relative strabismus the most familiar type occurs in paralysis of an ocular muscle. Let us take, say, a paralysis of the left external rectus. Now, on looking to the left side there is no interference with the movements of the right eye. It can move perfectly towards the left. The left eye, on the other hand, cannot; it is restricted in its movements towards the left, and hence when the patient looks towards the left at a distant object there is convergence of the optical axes. But were the patient to look towards his right, then there might be neither undue divergence nor convergence, for the right eyeball would be chiefly under the control of its external rectus and the left under that of its internal rectus. Neither of these muscles is affected by the supposed paralysis, and, hence, if a distant object is looked at there may be approximately parallelism of the optic axes.

Other important examples of relative strabismus are to be found in cases of what is called heterophoria. The example most easily understood is the variety called exphoria, and it may be in suitable cases demonstrated in the following manner. Let an ink line be drawn on a piece of paper, and let it be held vertically at a yard in front of the patient, as nearly as possible at an equal distance from each eye and at the height of the eyes. Most probably under these conditions the line will be seen singly. Let the test object now be brought nearer and nearer to the patient. The likelihood is that it will still be seen as a single line to a point much nearer to the eyes. At last, however, a position is reached which is the maximum of convergence, and for all nearer distances one eye follows the test object accurately while the other does not, but relatively, if not absolutely, deviates outwards. If there is fairly good vision in each eye a crossed diplopia ensues. This is a tolerably good method of measuring the near point of

Digitized by Google

convergence, although a still better one is an illuminated slit, as in the ophthalmo-dynamometer devised by Dr. Landolt.

This leads further to the remark that the treatment of any form of strabismus has for its ideal either the restoration of a disturbed binocular fixation, or else a cosmetic result. In certain cases where there is no useful sight in an eye a patient may yet insist on treatment in order that an obviously disfiguring squint may be put right. In most of these cases a sufficiently good result can easily be obtained. Here is a case in point:—

J. D., aged 20, has a divergent squint of the left eye. It is found that the right eye is almost emmetropic and has very good visual acuteness. In the left there are eighteen dioptries of myopia; the patient can read No. 14 Jaeger with the left eye when the types are held at the far point. Such cases are not uncommon. Now, any treatment here must be for the purpose of cosmetic improvement, for the optical conditions are such that even with careful correction binocular fixation would not extend beyond a very narrow limit. For suppose the correction to be made. Before one eye there would be placed a piece of glass with little or no refractive power; before the other a strong concave lens. Now, when the patient looks straight in front of him at a distant object there may easily be binocular fixation, but for every other position of the eyes it is almost impossible, owing to the prismatic and cylindrical effects which are consequent on the oblique refraction through the edge of the concave lens. When, however, there is the possibility of a fair amount of vision in each eye, then the proper object of treatment should be to secure binocular fixation for all possible points. Yet how few think of this. When a parent brings her child to have a squint seen to, or a medical man sends a patient to a specialist for the same purpose, it is in the vast majority of cases for the cosmetic result of having the squinting eye put apparently straight; rarely is it with the rational purpose of the restoration of binocular fixation. Yet this function is an important one, for, as is well known, it is the most important factor in the unconscious estimation of the third dimension. Hence, after the enucleation of one eye most people see everything on the flat, and, for some time at anyrate, are apt to pour their tea on the table and not into their cup. While, therefore, appearance is a thing not to be despised, our ultimate end in all operative work in strabismus is the restoration, when possible, of binocular fixation. It is the object of this paper to show that this result cannot, in a satisfactory manner,

Digitized by Google

be brought about by tenotomy, but that the best method of operating is by advancement.

The next step in our argument is an important one. We must insist on the necessity of every case being thoroughly examined. If this be done, then the surgeon obtains a clear idea of the conditions with which he is dealing, and may, in certain cases, arrive at a satisfactory conclusion as to the cause of the affection in the particular case which he is examining.

In times gone past tenotomy for concomitant squint was often performed without any examination of the functions at all, or, at most, the refraction of the eyes was measured and the visual acuteness. But in many cases no attempt was made before interference to measure carefully the angle of the squint, and no investigation was made as to the field of fixation nor the function of convergence. Had these matters been inquired into, I am satisfied that the death knell of tenotomies, except under special circumstances, would have been sounded long before Landolt's time. It is because he has for many years, with an assiduity and care worthy of all praise, investigated cases of squint that we are now in a better position than formerly to treat the affection on rational principles.

Let us narrow our inquiry in the meantime to the crux of the whole question, viz., the treatment of convergent strabismus as it occurs along with hypermetropia or hypermetropic astigmatism. If we can make out a good case for advancement of the external recti, instead of tenotomy of the internal, the worst of the fight will be over, for it is a comparatively easy task to extend the argument to most of the other forms of the affection.

From the days of Donders onwards, much has been written as to the etiology of that variety of convergent squint which is called concomitant. He it was who first pointed out its association with hypermetropia, or with hypermetropic astigmatism, and gave a rational explanation of the condition. For my own part, it seems that his explanation still holds good. At the risk of repeating what must be familiar to almost everyone who has taken a course of modern physiology, we give a brief summary of his views.

In ordinary circumstances, for any act of binocular fixation two closely allied functions are called into play—viz., convergence and accommodation. Thus, given a person who is possessed of good visual acuteness in each eye, and whose refraction is approximately emmetropic, when a distant object is looked at, the patient neither accommodates nor converges; both functions are in abeyance. If now a point 2 metres

Digitized by Google

away is fixed, the person both converges and accommodates for that distance. If the point be 1 metre away, then the accommodation and convergence necessary for the new distance are at once brought into play. If the test object is now brought nearer and nearer, two points are obtained. One of them marks the nearest limit of the power of accommodation; this varies with the age of the patient and with other circumstances which need not detain us at present. The other is the near limit of the convergence, and for the most part varies with the innervation of the internal recti muscles.

Such is the normal condition, and it will be noticed that for all ordinary distances the two functions progress *pari passu*. Be it observed that in normal conditions every act of accommodation means also a certain definite act of convergence. Now, in hypermetropia matters are different. Here distant vision requires an act of accommodation although not of convergence. The one function is called into play before the other, and as the object is brought nearer, the accommodation is more used than the convergence to a given amount. But we have just seen that if a given amount of accommodation is used in emmetropia, then there must also be employed a given amount of convergence. Therefore, if there is to be in hypermetropia binocular fixation, this involves that the two functions are more or less disassociated from each other; in other words, that the act of accommodation is not accompanied by a corresponding act of convergence, but by an effort less in amount.

It is probable that it is this interference with the normal relationships existing between the two functions which is in many cases the cause of ophthalmic headache. Thus, in hypermetropia we find that when each eye has a good visual acuteness the patient sacrifices his comfort in the interests of binocular vision, and forces himself to use less convergence than would otherwise be required for the amount of accommodation used. If, however, defective sight exist in one eye, then there is no longer any need of disturbing the normal relationships of the two functions, because from the defective vision it is impossible for the patient to have what may be called the natural perception of the third dimension. In many cases, it seems likely that the defective vision found in a squinting eye is the *propter hoc*, not the *post hoc*. No doubt in some subjects other influences are at work, for we occasionally, although rarely, find concomitant squint in persons in whom both eyes are possessed of excellent vision. In this connection it is well to remember that some authors have

Digitized by Google

tried to establish a connection between rickets and squint. That is, however, a matter beyond our present inquiry. What is insisted on is that where in hypermetropia binocular vision is impossible owing to one eye being defective in vision, then the effort of accommodation is at once accompanied by its proper amount of convergence. In other words, in these circumstances we have convergent squint.

In certain cases this squint is alternating—*i.e.*, it appears first to affect one eye, then the other; but in most, it sooner or later becomes located apparently in one. I say apparently, for it must be kept in mind that concomitant squint is in reality always a bilateral affection. For example, when a hypermetropic patient fixes a distant object, an amount of accommodation is used sufficient to overcome or correct the hypermetropia. Along with this there is the corresponding amount of convergence, and the two eyes assume a definite convergence towards each other. The distant object is not then in the line of sight of either. To rectify this, while the two eyes still retain their relative convergence to each other, one of them, usually that with the best visual acuteness, is turned towards the object which the person wishes to see, the other therefore apparently converges all the more; for the two maintain the same relative convergence. There is a certain tension of the innervation of both internal recti.

Such, briefly stated, is the theory of the origin of concomitant strabismus which, though it must under special circumstances be modified, appears to me to explain the greatest number of cases.

This paves the way for the discussion of the treatment of concomitant squint. That treatment divides itself into—1, Orthoptic; 2, Optical; 3, Operative.

1. The chief difficulty which the surgeon experiences in the scientific treatment of squint is the impatience of his patients, or more especially of their guardians. A young child has strabismus, and its parents or other guardians become anxious that the defect should be put straight without delay. Thus, the surgeon is rarely allowed to spend that care and time over the treatment of his patient which is requisite for orthoptic exercises. Moreover, there is always the pressure of school work, so that it is next door to impossible to have a young person subjected to this important line of treatment. In young adults, however, something of the kind should always be attempted. No statement of details can be given here, but in general terms it may be said that the lines to be

Digitized by Google

followed are, first, by regular and patient exercises to excite what vision is possible in the squinting and amblyopic eye. If we succeed in this, the next effort should be devoted to arousing in the patient the sense of binocular vision—*i.e.*, the sense of perspective. Probably the only method of doing so is by long and patient exercise with a good stereoscope. Any well devised stereoscope will do. The one which I personally use is that of Dr. Doyne, but I do not think it has any special advantages over any other form. For the early exercises it is well to put on one side of the stereoscope the upper half of a picture, and on the other the lower half, so that the patient's efforts may be directed to combining them into one. Whenever he can manage to do so, ordinary photographs such as are commonly used for stereoscopic purposes may be substituted, in order to arouse the patient's sense of the third dimension. These exercises are always of great use, and are specially beneficial as an adjunct to any surgical treatment.

2. As regards optical treatment, we must, of course, correct all errors of refraction. In olden times there was a haphazard way of fitting every case of concomitant squint with spherical + 3 D. It was said that every child who had a concomitant squint must have a hypermetropia of 3 D. This simply illustrates how very carelessly examinations were made at that time. For although it be true that in very many cases there is that amount, still in others there is not. In fact, not infrequently concomitant squint is found where one eye has even a somewhat low error of refraction, such as 2 D of hypermetropic astigmatism, and the other is nearly emmetropic. I have seen several such cases. It would simply be the height of absurdity to put a pair of + 3 D glasses on a case of that kind.

A correction, no doubt, should be made, but it ought to be as careful and as accurate as possible; otherwise it is worse than useless.

Optical treatment also includes proper exercises by prisms. Where, as a result of our efforts to encourage vision in the squinting eye, a diplopia has been established, they are of use in helping the patient to unite the images into one.

Under the heading of optical treatment may, I think, almost be included the instillation of mydriatics. These act orthoptically by paralysing the power of accommodation, and thus allaying the effort of convergence. In whatever way they act there is no doubt of the clinical fact that, given a case of squint with little difference in the error of refraction and with a fair amount of vision in each eye, a course of

Digitized by Google

mydriatics with correction of refraction errors will, without further treatment, often restore binocular fixation.

3. But I wish to-night to dwell especially on the operative treatment; for within the last few years my own opinion, in common with that of many better able than I to form one, has undergone a radical change, and I have thought the matter of sufficient importance to be intruded on this Society. For a considerable time I have operated on all cases of divergent squint by advancement. In my earlier days I operated on a few occasions for divergent squint, or insufficiency of the internal recti, by tenotomy alone. For many years, however, I have, in common with most others, invariably operated on divergent squint, absolute or relative, by advancement of one or both internal recti. For some time back I have operated on convergent squint only by the same method, and have given up tenotomies almost entirely. My endeavour to-night is to justify, if possible, this important change.

I shall try to show—1, That the operation is more rational than tenotomy; 2, that it is easily performed; 3, that the results are quite as successful; 4, that it does not produce the disfiguration similar to that produced by tenotomy.

1. Whatever theory may be held as to the origin of concomitant squint, careful examination of the field of fixation with an ordinary perimeter will show that the ultimate result is that in most cases the external recti muscles are extremely defective in function. As a rule, the internal recti do not seem to have a stronger action than normal. As a matter of fact, in a very fair proportion of cases they are weaker than usual. Yet, in most cases the strength of the internal recti does not differ from what is generally found. This is not merely an opinion, but is a matter of fact.

Now, if an attempt is made to rectify this state of affairs by tenotomy, apparent straightness is only obtained when the converging function is made as weak as the diverging was before. Not till then will the eyes easily assume the parallel position for distance, although it is freely admitted that this parallelism for distance can be obtained under favourable circumstances. That it is so in some cases is, however, more good luck than good guidance. But what then? Most acts of accurate vision require a certain amount of convergence. By tenotomy, to a very large extent indeed, this power of convergence is destroyed. You have not strengthened the diverging power by sacrificing the converging; all you have done is to weaken the convergence.

Digitized by Google

Hence, what is known as the positive part of the range of convergence is much lessened in extent, and as a natural and necessary sequence the near point of binocular fixation is at a considerable distance from the eyes. A heterophoria is artificially established. There is no possibility of binocular fixation for near distances.

This subject would be more easily discussed were I to introduce dioptries of accommodation and metric angles of convergence. These, however, are strictly technical terms, and express definite units of measurement. It is perhaps as well, therefore, to endeavour to convey an idea of the facts without employing these units; for their definition, elementary and simple though it be, would lead beyond the proper sphere of this paper. Let an easy example be taken. If a man is to read a book at 16 inches binocularly, he must accommodate at least to 16 inches, and converge on the same distance. Not only so, but as no function can be used to its full extent with comfort to the individual, he must be able to accommodate to a much nearer point, and to converge to one still more close. In both cases there must be a large reserve.

If, then, by tenotomy you have largely reduced this reserve, or annihilated it altogether, comfortable binocular vision is no longer possible. Under such circumstances it is not at all infrequent to find that the patient gives up the effort and allows one of his eyes, by preference the one less useful for sight, to deviate outwards. This deviation at first may only be for near objects, but ultimately it becomes constant for all distances. The previous convergence is in the worst cases turned into an absolute divergence. Therefore, from tenotomy there may be one or two distressing results—(*a*) The convergence may be so weakened that binocular fixation at the ordinary near at hand distance is impossible; (*b*) it may be so destroyed that there is absolute divergence. Facts confirm this theory. Within the last year I have carefully examined a number of cases which had in previous years been operated on by myself or by others for concomitant squint by the method of tenotomy. In only two of them have I found a satisfactory near point of binocular fixation; in all the others the positive range of convergence was much diminished, and in some it was absent altogether. In such cases it is usual to say that the operation has been a bad one; that the surgeon has cut too much. In some cases this charge may be true, but in the majority it is not. The absolute or relative divergence is nothing less or more than the necessary

Digitized by Google

physiological sequence of the altered conditions of the internal recti.

Particularly is this ultimate divergence liable to occur in cases which have been operated on under the influence of a general anæsthetic. In these cases the surgeon is apt to divide the tendon of the muscle too freely, as also its attachments to the capsule of Tenon. In very many cases operated on under the influence of chloroform or ether I have found a marked divergence. It is, so far as my experience goes, the exception to find the eyes straight even for distant vision.

There is, however, another side to the question. In many cases the tenotomy does not bring the eyes even approximately straight for distance, but still leaves a very marked convergence. That is a clinical fact which all who are not the merest novices will admit. In many such cases the explanation is that the diverging power is so weak that even by tenotomy the convergence cannot be weakened to such an extent as to allow the external recti to pull the eyeballs into the parallel position for distant fixation. Many of these cases are explained by a marked amblyopia in one eye, which involves that there is no impulse towards binocular fixation.

In my student days it was said that certain cases of convergent squint were associated with weakness of the external rectus muscle of the squinting eye, and even at that time it was a rule laid down for our guidance that unless the external rectus could draw the eye beyond the middle line advancement of the external should be performed with tenotomy of the internal.

In a very fair proportion of cases a tenotomy does not seem to make any very marked difference in the relative positions of the eyes.

From the above it will be apparent that tenotomies are somewhat haphazard experiments, which sometimes succeed but at other times do not.

The operation by advancement, on the other hand, is more rational, in so far as it does not attack a function which is more or less in a normal condition, but is directed against the abnormality of function. It is an effort to restore impaired function, not to impair healthy function. That statement by itself goes a long way to prove this operation to be more rational than tenotomy. But, further, in the vast majority of cases there is no reason to apprehend a resulting divergence. I have performed the operation in a large number of cases, and in one only has there been an

Digitized by Google

ultimate slight divergence. That arose from my carelessness, and a little more strict attention to the rules which I have formulated for my own guidance would have prevented this mishap. The case was that of a young lady who had been operated on by tenotomy for convergent squint in childhood. When I saw her, notwithstanding the tenotomy, there remained a convergent squint of not less than 30°. The examination of the field of fixation showed great diminution in the functions both of the internal recti and of the external.

As a rule, in concomitant squint both external recti must be advanced. This, however, ought not to be done when the convergence is deficient. In the particular case here referred to it unquestionably was, and that probably owing to the tenotomy, which, however much it had impaired one internal rectus, had not even apparently removed the squint nor strengthened in any way the external muscles. In future, when the convergence is markedly defective I shall not advance both muscles at the same time. This is the only case in which there has been even the slightest divergence. But what of that? It does not matter; this slight divergence is due to the destroyed convergence, and all that is required to put it right is an advancement of the previously divided internal rectus.

Speaking generally, however, I find it to be the rule that the operation should be performed on both external recti when the strabismus is severe, and when the internal recti are nearly of normal strength.

The advantages, then, which I claim for the operation are—(*a*) It does not, except from the carelessness of the operator, lead to divergence, and if it should, then the defect is easily remedied by advancement of the internal rectus; (*b*) it does not in the least interfere with the function of the internal recti, so that if their power was good before, it remains good and the patient may have an excellent range of convergence.

2. In the next place, the operation is easily performed. So far as that goes, a few drops of cocaine solution introduced into the capsule of Tenon render it all but painless, so that only for young children or for timid and nervous persons is a general anæsthetic required. The pain is reduced to a minimum if the patient during the operation is made to look in such a way as to relax thoroughly the muscle which is being operated on. *Thus, if the right internal rectus is being attacked, the patient should be made to look to the right side.* This is an important point.

Digitized by Google

That the operation is simplicity itself is proved by the fact that an internal or external rectus muscle can with the utmost ease be advanced within a period of ten minutes. I do not intend to trouble my audience with the details of the operation, for I have already described the manner in which I perform it in the *Ophthalmic Review.* The method which I follow differs but little from that detailed by Mr. Swanzy in his text-book. The operation presents no difficulty whatever, nor is it any more dangerous than tenotomy. It is true that I have seen this latter operation followed by acute orbital cellulitis; not in my own hands, but in those of another surgeon. Such a result I have never seen with an advancement. In any case, however, in which there is redness of the conjunctiva, it is well to follow the rule which I have adopted in all doubtful cases—viz., to bandage the eye with sterilised cotton-wool, and to cultivate any discharge collected thereon before operating. By so doing, the surgeon may be warned of danger.

3. Mention has already been made of the fact that a tenotomy sometimes does not seem in any material way to lessen the convergence. It is but right to state that occasionally with an advancement the same thing occurs. Even after the advancement of both external recti there may remain a slight convergence. Such cases are, however, rare. When this happens, if each eye is possessed of a fair amount of vision, our efforts should be directed to such orthoptic exercises as will stimulate the patient to binocular fixation. In most of these cases a perfect result, so far as straightness of the eyes is concerned, is ultimately attained, and let it be remarked that it is attained without any sacrifice of the power of convergence. When, therefore, the eyes become straight, there is a possibility of the patient having a satisfactory near point of binocular fixation.

4. As to the element of disfigurement, there can be no doubt as to which is the preferable operation. Almost invariably it is possible to tell by inspection an eye which has been submitted to tenotomy, for it presents three marked features—viz., the inner canthus is somewhat distended, the caruncle is shrunken, and there is a certain amount of protrusion of the eyeball. The eyeball may be said to rest at the base of a surrounding muscular cone, which keeps it in position. If, therefore, at any point this enclosing muscular sheath becomes detached, the eyeball tends at that point to protrude, and as a matter of fact it often does so. Sometimes

Digitized by Google

this defect exists to such an extent as to give an appearance of one of the lesser degrees of exophthalmos.

Such deformities are entirely unknown after advancements. There never is that dilatation of the inner canthus which is so troublesome in tenotomies, and for the avoidance of which so many proceedings have been devised without any very satisfactory results. The only deformity which results from an advancement is the formation of a small granuloma in the wound, which can easily be treated.

It might have strengthened the argument of this paper had I added some of the fixation diagrams taken in cases of squint. These, however, I meantime reserve. They do not in any essential differ from those already published by Dr. Landolt in his various papers, to which I acknowledge indebtedness.

Dr. Rowan agreed with Dr. Fergus that, on the whole, advancement gave better results than tenotomy in the majority of cases. Landolt, in his clinique, had occasionally to do advancement after tenotomy. The speaker had recently seen a case where, after a tenotomy of the internal rectus, the eye had rolled completely out. He emphasised the value of exercise of the ocular muscles, and deprecated the prevailing tendency to operate too soon.

Dr. Hinshelwood said that since the work of Landolt had become known there had been a gradual extension of feeling in favour of advancement. The argument in its favour, that it strengthened the muscle in place of weakening it, was a strong one. But it was not right altogether to condemn tenotomy in slight degrees of strabismus, where the subsequent deformity, and the weakening of the opposed muscle, would be comparatively trifling. In many cases, too, the eye was amblyopic, and restoration of binocular vision could not be hoped for. There were still cases, therefore, where tenotomy was reasonable and proper.

Dr. Fergus, in answer to Dr. Hinshelwood, said that he had done a fair number of advancements for small degrees of internal squint. The field of fixation had to be considered. Even if a large advancement were made, the ultimate tendency to convergence would correct any temporary overdoing. In cases of amblyopia one must do one's best to measure the excursions of the eye.

Digitized by Google

MEETING X.—25TH MARCH, 1898.

The President, DR. G. S. MIDDLETON, *in the Chair.*

I.—FRESH SPECIMENS.

BY DR. EDGAR.

Dr. Edgar showed two ovarian tumours removed from the same patient, the first being a dermoid cyst of the right ovary, the second a compound cyst of the left ovary, at one part dermoid, but for the most part an ordinary proliferating multilocular cyst which had ruptured prior to operation. This tumour was the size of a man's head. The woman, whose age was 54, complained of abdominal pain and swelling, of four years' duration. She was still menstruating. Defæcation was painful, and she was markedly cachectic. During the past four years there had been a gradual increase in the size of the abdomen, becoming much more rapid in the last four months. Six weeks before her admission to hospital she was seized with a sudden pain in the left iliac region, which recurred in three several attacks. Dulness was noted at that time in the right flank, while the left was clear. In a few days the left flank became dull, while the right cleared up, and soon afterwards the former condition was re-established. In a short time both flanks became dull, and the dulness extended upward to a point 2½ inches above the umbilicus. A tumour was felt on palpation. *Per vaginam,* the uterus was found to be prolapsed and retroflexed, and its lateral movement to the left was restricted. Under chloroform a second smaller tumour was also felt. A quantity of ascitic fluid and gelatinous material was removed on operation. The larger tumour was very friable, and its pedicle was twisted. The omentum and peritoneum were thickened. The uterine fundus was fixed to the abdominal wall, and the patient, at the time of the report, was doing well.

II.—NOTES OF A FEW DIFFICULT GYNÆCOLOGICAL CASES.

BY DR. J. K. KELLY.

1. Mrs. M'C., æt. 54, was admitted to Ward 30, on 7th December, 1897. She had had six children, the last eleven

Digitized by Google

years ago. Since that time she had noticed that her abdomen was swollen, and the swelling has increased during the past year. Notwithstanding this abdominal enlargement, she considered herself perfectly well until the beginning of September last, when one day, at her work, she fainted and had to be carried home. This was succeeded by abdominal pain and vomiting of everything she took. Since September she has had five similar attacks of severe pain followed by vomiting, each attack lasting about two days, and during this time the tumour has increased more rapidly in size. In addition to these recurrent pains, she has had constant pain in the left iliac and hypogastric regions, and up till a month ago she suffered from a pain in the left leg, which passed down as far as the ankle. Defæcation is painful, especially when she has not a daily evacuation. Micturition also has been painful for some time, and the amount of urine seems to the patient less than normal. She has lost her appetite, and suffers from a leucorrhœa of irritating character, giving rise to an eczema of the vulva.

Examination revealed a generally distended abdomen, tender to pressure all over, more especially below and to the left of the umbilicus. Percussion dull in the hypogastrium, where there is a tumour elastic to pressure, giving the feeling of a cyst containing fluid. While percussion dulness reaches hardly to the umbilicus, the tumour to palpation reaches nearly to the costal margin. *Per vaginam*, the uterus is atrophic, with hardly any portio vaginalis. High up in the fornices a resistant feeling presented by lower surface of mass felt *per abdomen*. Examination *per rectum* reveals nothing further.

Here, then, we had an abdominal tumour which had been present probably for a year. During most of the time it had gone on growing without causing any trouble; but suddenly, in September, some accident had happened which had disturbed its normal course, and had caused recurrent attacks of peritonitis, and from being a painless growth the tumour had been changed to one causing intense suffering. From its relation to the pelvis, from its position in the abdomen, from its cystic character, and from its previous uneventful history, this tumour was probably an ovarian cystoma; but if it were, what had occurred in September? There are two events that may happen in the history of an ovarian cystoma, that may set in suddenly, and cause serious symptoms. One of these events—rupture of a large loculus—could almost be excluded in this case. There had been no diminution in the size of the

Digitized by Google

tumour subsequent to the attack of faintness, and the symptoms were more severe than we expect from rupture. I considered, therefore, that the sudden change had been due to torsion of the pedicle, and this was confirmed at the operation. On 17th December, abdominal section: ovarian cyst was found universally adherent to anterior parietes, to omentum, and bowel. On separation of adhesions and emptying of cyst, which was filled with several pints of dark chocolate-coloured fluid, the pedicle was found twisted, the torsion amounting to two complete revolutions. Convalescence was somewhat disturbed by the eczema vulvæ, but patient went to the convalescent home well on 19th January, 1898.

2. G. C., æt. 24, nullipara, admitted 28th December, 1897. About the middle of July last, patient first observed a swelling in her left side above the umbilicus, and this gradually extended both upwards and downwards. For about three months previous to this, she had been troubled with occasional pain in the right side, midway between the umbilicus and the groin, and this pain was always worse at the menstrual period. Menstruation has gone on regularly without change in either quantity or appearance, but the dysmenorrhœa has increased since the swelling appeared. Until three weeks ago she could lie flat on her back without inconvenience, but now this posture is unbearable for any length of time, and she is compelled to lie on one or other side—by preference on the left side. Of late she has had some difficulty in micturition, having to pass water every few minutes. There is a good deal of mucus in the stools, and the fæces look as if they had passed through a narrow passage.

Patient has never had any other illness, and always used to be strong and healthy. She is a laundrymaid by occupation, and has frequently to work without interruption for twelve hours a day.

On examination there is a smooth tense swelling of the abdomen, most marked at the level of the umbilicus. The right side is more prominent than the left, both above and below the level of the umbilicus. The most prominent part of all is between the umbilicus and the right groin, which is also harder and more tender than any other part. There is absolute dulness to percussion from 1¼ inch below the ensiform cartilage to the pelvis. Left flank is dull all over, right flank is clear behind the line of the anterior superior spine. Change of position makes no change in percussion. *Per vaginam,* uterus is drawn high up, the portio vaginalis being near brim. The

Digitized by Google

tumour mass occupies the whole brim of the pelvis. On admission this patient was suffering very severely from pain as well as from pressure symptoms on the side of both rectum and bladder, and though we wished to delay operation till after New Year's day, we were forced to operate on 31st December. The theory I formed of the tumour was, that it was a very rapidly growing ovarian cystoma, that in its growth loculi were frequently bursting into the peritoneum, setting up here and there localised peritonitis, and that on that account we should have extensive adhesions, though there were evidently no intestinal adhesions in front of the tumour, such as gave rise to the clear percussion in the last described case. At the operation it became evident that at least some of the peritonitis was due to tubal disease of the right side accompanying the cystoma, and on inquiring afterwards we found that the patient, though unmarried, cohabited with a man. The operation was a very difficult one. The cyst had extensive adhesions to anterior parietes, intestines, and pelvic structures. The adhesions were in some places very dense and firm, so that they had to be divided by scissors and knife. On reaching the pelvis the right ovary was also found slightly cystic, with the tube adherent to it by the fimbriated end, and dilated to the thickness of a finger. After separating the adhesions down to the pelvis, removal was commenced by tying off and excising the right tube and ovary, and from this separation was continued across the pelvis through the cervix of the uterus into the left broad ligament, where the base of the cyst was tied off in separate portions so as to form a pedicle. This, with the stump of the uterus, was left in the lower angle of the abdominal wound, the peritoneum washed out with warm saline solution, and a small gauze drain left both over the pedicle and behind it. Patient rapidly recovered, and went to the convalescent home on 28th January, 1898.

3. Mrs. R., æt. 59, unipara thirty-three years ago, admitted 11th February, 1898. Patient reached the menopause seven years ago, and has been fairly well since, although she has never been robust. Since then there has never been any discharge from the vagina. Three months ago she noticed that she swelled up after taking food, and was obliged to avoid certain articles of diet. There was no pain or vomiting. At the same time she observed that she passed very little urine, and that it was darker in colour than normal. It was never darker than beer, however, and never suggested blood. There

Digitized by Google

has never been polyuria. About the same time she noticed a swelling in the lower part of the abdomen which had gradually increased. It appeared first in the middle, and not at any one side. For the past two months she has had slight pain in the left iliac region, increased by exertion during the day, and often keeping her from sleeping at night. It is relieved by pressure, and varies in intensity.

On examination, the results of palpation and percussion were rather confusing. The hypogastrium nearly to the level of the umbilicus was occupied by a lax-walled cyst, the wave of fluctuation in which was very full. Above and to the left of this and passing towards the costal margin were several firmer masses, like small tense-walled loculi, situated at a deeper level than the superficial cyst. The whole left side was dull to percussion, but when patient turned to the right side the left flank became clear and the tumour fell forward in the abdomen. To palpation the upper border of the tumour on the right extended beyond the line of percussion dulness. There was no enlargement of the inguinal glands. *Per vaginam*, the lower zone of the tumour presented, in the posterior fornix and towards the left, a cystic but somewhat irregular surface, slightly painful to pressure.

I had great difficulty in forming an opinion regarding the nature of this tumour. But from its position, which was mainly central, though extending markedly towards the left side; from its history, which pointed to a pelvic origin; from its varying consistency, which seemed to indicate a cystic tumour with loculi containing fluid at different degrees of tension; and from its evident connection with the pelvis, I inclined to think that it was an ovarian cystoma, and on that ground formed a favourable prognosis. On 18th February, abdominal section: no cyst was found. The main quantity of fluid lay in front of the bowels, shut in by soft gelatinous adhesions. On removal of the fluid the whole surface of the bowel was seen to be studded with little hard, whitish nodules varying in size from that of a small pin head to that of a split pea. Between the transverse colon and the lower border of the stomach, uniting the two to each other, and projecting from between them like a ridge, was a bluish-white hard mass apparently representing the omentum transformed into malignant tissue. Masses of the same character occupied the region of tubes and ovaries, and lay behind the uterus in Douglas' pouch. For about ten days this patient was relieved, took nourishment well, and improved in strength, but from

Digitized by Google

the 1st March she began to lose appetite, to be troubled with sickness, rapidly grew weaker, and died on 14th March. The inspection revealed that the primary seat of the cancer was in the ovary.

4. Mrs. J., æt. 27, admitted 7th February, 1898. Has had two children, the last a year ago. After the birth of her first child patient suffered from a severe pain in the right side, which lasted for about two months. It returned after the birth of her second child, but only lasted a week. After that she continued well till last December, when the pain returned. Shortly after it returned she went to a ball, and this greatly increased the pain. Since the New Year it has confined her constantly to bed, and has required to be relieved by morphia suppositories. It shoots down the leg as far as the knee, and sometimes even to the toes. It is also felt very severely in the small of the back. Coitus has been painful for several months. Since the New Year she has emaciated rapidly, has had night sweats and frequent chills, and has felt very seriously ill.

During the summer she had a sore throat, which lasted three or four months; red spots came out all over her body, and at present they can be distinctly seen on both fore-arms as pale brown circular stains. The hair has been coming out lately. The cervical glands are enlarged, and she has pain occasionally, especially at night, in the shin-bones. Micturition is sometimes and defæcation always painful.

On examination, the abdomen is tender to pressure all over, particularly in the right iliac region. Pressure in the lumbar region behind also causes considerable pain, but no tumour is detected by palpation. *Per vaginam*, uterus is strongly anteflexed, so as to depress anterior vaginal wall; measures 2½ inches. Endometrium not tender, but introduction of sound causes slight pain in the right side. In right fornix, appendages form an irregular cystic mass, excessively tender to touch. Left appendages are also tender, but outlines cannot be clearly made out.

The history here indicated an old-standing pelvic inflammation complicated with syphilis about eight months before, and acutely exacerbated within the last two months. The physical signs indicated a sacculated collection of fluid on each side, and the diagnosis of double lactosalpinx purulenta was made. On 13th February, abdominal section: a tubo-ovarian abscess was found on right side, and was separated with great difficulty from adhesion to uterus, omentum, and bowel. On

Digitized by Google

left side the adhesions to bowel along the pus-containing tube required careful separation before the appendages could be removed. Patient made an uninterupted recovery, and went home on 1st March.

5. Mrs. M'N., æt. 33, admitted 9th February, 1898. Had one child twelve years ago, and one premature birth at the seventh month thirteen years ago; since then three miscarriages, the last nine years ago. Has been unfit for work and more or less confined to bed during the last fourteen months by menorrhagia and pain. The pain was at first chiefly in left side, but it now involves also the right side. During menstruation the pain is greatly increased, and then resembles the pains of labour. Fourteen months ago, when lifting a heavy weight, she felt something give way in her inside with a snap, and this was followed by cramping pains in the abdomen and profuse hæmorrhage from the vagina. The hæmorrhage lasted for seven weeks at that time.

In August last she had another hæmorrhage which lasted four weeks; but, as a rule, the menstruation has continued only for ten days or a fortnight. On examination, palpation causes pain in both right and left iliac regions; and on the left side, on deep pressure, a distinct tumour can be made out. *Per vaginam*, the cervix lies nearer the pubis than normal. Uterus measures 3 inches. Fundus in right posterior quadrant of the pelvis. Posteriorly and to both sides of uterus are cystic tumours, somewhat irregular on surface and very tender to pressure.

In this case, then, we had evidently a pelvic disease of many years' standing, sufficient to cause absolute sterility during the past nine years. It is possible that the beginning of this may be traceable to the birth of her child twelve years ago, when she apparently had eclampsia and was unconscious for three days. The puerperium, however, does not seem to have shown any serious symptoms, as she was out of bed in three weeks. The explanation of the history I considered to be that in that puerperium a pelvic inflammation was started, which gradually closed the Fallopian tubes, and led to the collection in them of muco-purulent material. As the result of this, further pelvic inflammation resulted; but the history was unmarked by any noteworthy occurrence until fourteen months ago, when, as the result of an unusual effort, some of the adhesions in the pelvis had been torn through, and some of the pus had escaped from the tube into the peritoneum and set up an acute illness which had recurred again and again

Digitized by Google

ever since. At anyrate, on admission to hospital we had a double pyosalpinx and all the pelvic organs adherent to each other.

On 16th February abdominal section was performed. Dense adhesions, which covered the whole posterior surface of the uterus and stretched across over the adnexa to the sides of the pelvis, were torn through with great difficulty before the tubes and ovaries could be separated and excised. The omentum, also, was adherent over the fundus of the uterus and upper surface of right tube, but there were no direct adhesions to bowel. A small quantity of pus escaped from right tube as it was raised to the surface. Patient went out well on 5th March.

6. Mrs. M'I., æt. 26, admitted 11th February, 1898. Has had two children, and last 5½ years ago, and one miscarriage in November of last year. Patient states that she was quite well till about twelve months ago, when she began to be troubled with pain in the left side, which has continued since. For more than a year she has observed that the abdomen was swollen, and this swelling has increased of late. The bowels are constipated, and she constantly requires purgatives. Her periods have always been regular until the end of December last, when she took a flooding. This continued for five weeks, but gradually the amount of blood diminished until it ceased. At the time of the flooding she had no sickness, faintness, or vomiting. Of late the pain has passed round to the back. Micturition has become painful, and there is a good deal of rectal tenesmus, and occasionally some blood in the fæcal evacuation.

On examination the abdomen is uniformly and greatly distended, and clear to percussion all over. Palpation causes no pain except in the inguinal regions, where there is considerable tenderness to pressure. *Per vaginam*, uterus measures 3¼ inches, fundus slightly to right side, cervix enlarged and follicular. Right appendages irregular on surface and matted together. To left of uterus, and separated from it by a shallow groove, is a cystic mass about the size of a Jaffa orange, and passing also slightly behind the uterus into Douglas' pouch. The diagnosis here also was double pyosalpinx; but neither the examination of the chest nor the enlargement of the abdomen suggested, as perhaps they should have done, the condition that was found.

On 21st February abdominal section was performed. The omentum was completely adherent to the anterior abdominal wall and to the upper surface of the pelvic organs. When this

Digitized by Google

was peeled off the intestines were found studded with little granules like tubercles, and adherent both among themselves and to all surrounding parts. With great difficulty the left appendages were reached, raised from their position and excised, and during the process a considerable quantity of pus escaped from the tube. The right appendage also was removed. The tubes, examined microscopically, showed tubercle bacilli. Patient left hospital well on 15th March.

Dr. Middleton asked, with regard to the first two cases, whether the fact that the tumour could be traced further by palpation than by percussion was to be taken as indicating an adhesion of the bowel in front. Such a condition was quite common in other forms of tumour where no adhesion existed. He was interested in the mistaken diagnosis formed in the third case, as such mistakes were very common in abdominal diagnosis. He thought the result of treatment in the last case very satisfactory.

Dr. Edgar emphasised the difficulty of diagnosis in abdominal cases. He had now seen two cases of tubercular peritonitis, both ending in recovery. In the first he had washed out the cavity and closed the abdomen. In the second, a child, a rupture of the abdomen had taken place at the umbilicus, and fluid had trickled out through the orifice for about three months. The abdomen gradually became smaller, and at the present date, two and a half years later, the child is well. This case might be regarded as negativing the theory that recovery after operation was due to exposure to sunlight.

Dr. Bell Todd asked if there had been any indication of tubercle in the chest in the sixth case. In the first case mentioned by Dr. Edgar there had been lung symptoms, which disappeared along with the others.

Dr. Wyllie narrated the case of a girl of 16 whom he had attended. There were slight symptoms of peritonitis, and, on examination, symptoms indicative of ovarian tumour were discovered. He was doubtful whether they might not have been produced by inflammatory exudation, and asked whether in such a case it would be wiser to operate at once or to postpone operation.

Dr. Howatt asked what was the after condition, with regard to menstruation, of the cases of pyosalpinx on which Dr. Kelly had operated. In a case which he had seen, the result was an enormous increase in the length of the menstrual period, and the menopause had not been established nine months after the operation.

Digitized by Google

Dr. Kelly, in reply, said that a spherical abdominal tumour gave an area of clear percussion all round its border, within the area of the tumour as made out by palpation, but such a clear area was of limited extent. If a tumour were found, a half or even a third of the area of which gave a clear percussion note, he would be much inclined to suspect adherent bowel. With regard to the tubercular case, there was no great danger of general peritonitis in the separation of such universal adhesions, as they practically closed the peritoneal cavity. He had been interested in Dr. Edgar's cases. It was at present impossible to explain the *rationale* of the cures which followed upon abdominal incision. In answer to Dr Bell Todd, he said that nothing tubercular had been found in his patient's lungs, although he ought to have suspected the tubercular nature of the case from the abdominal condition. If peritonitis should have arisen from an ovarian cyst, one should not hesitate to operate, but if it had arisen from another cause, in the presence of an ovarian cyst, the question of operation would depend upon the cause of the peritonitis. The question of menstruation was still as dark as ever. The function had been shown to be related both to the ovary and the uterus. In a case which occurred in Glasgow, pregnancy took place after the removal of both ovaries. As far as his own experience went, in the vast majority of cases menstruation ceased after their removal.

III.—CYSTS OF THE BROAD LIGAMENT: THEIR DIAGNOSIS AND TREATMENT.

By Dr. J. M. Munro Kerr.

The subject of the paper I bring under your notice this evening is cysts of the broad ligament, with special reference to their diagnosis and treatment. Now, somewhere about 10 per cent[1] of all cystic growths of the female pelvis arise from the broad ligaments. That such a large number have that origin is, I feel certain, not generally appreciated. For that reason, then, and because so far as I can discover they have never been referred to in detail at any meeting of this Society, I desire to-night to say a few words regarding them.

Diagnosis.

In this part of the paper my desire is to point out the features presented by broad ligament cysts, and to indicate

[1] Macnaughton-Jones, *Diseases of Women*, sixth edition, p. 543.

Digitized by Google

how far they may be diagnosed by bimanual examination from cysts of the ovary. To assist me in this, and also in what I have to say regarding their treatment, I divide cysts of the broad ligament into three classes. The division does not claim to be very scientific; it is, however, as I hope to prove, thoroughly practical.

1. Cysts of the broad ligament more or less pedunculated.
2. Cysts in the broad ligament, but not occupying more than the upper two-thirds of that ligament.
3. Cysts extending deep down into the pelvis, and ramifying in the connective tissue around the uterus, bladder, and rectum. These have been graphically and tersely termed by Lawson Tait "embedded cysts."[1]

The cysts of the broad ligament that can be diagnosed as such by bimanual palpation, are those fixed in the broad ligament—those of the second and third classes. Such cysts are to be felt firmly fixed and quite immovable, close down to the vault of the vagina. They are uniform in outline. If of any size, they are closely applied to the uterus, but if very small they may sometimes be slightly separated from that organ. The connection is usually so close, however, that they appear to arise from the uterus, and so a frequent mistake is to confuse them, not with ovarian cysts, but with fibromyomata of the uterus extending into the broad ligament. This mistake is further liable to occur, because they are frequently very tensely filled with fluid, and their capsules, the separated layers of the broad ligament, are often much hypertrophied; the tumours thus giving to the examining fingers the impression of being solid, rather than cystic. Such a mistake, of course, can only occur with the smaller cysts, those of larger size being readily distinguished by their consistency from solid growths. If a differential diagnosis cannot be made, the matter may be at once cleared up by making an exploratory puncture from the vagina.

The uterus, if the tumours are of any size, is always displaced over towards the opposite side. An accompanying forward displacement is not infrequent in those of the third class from the cysts extending into the cellular tissue behind the uterus. The opposite condition—viz., a displacement of the uterus backwards from the cysts extending into the cellular tissue between uterus and bladder—is very much rarer.

Coursing over the surface of the cysts are usually found the elongated and hypertrophied Fallopian tubes of the sides

[1] *Diseases of Women and Abdominal Surgery*, 1889, vol. i.

Digitized by Google

corresponding to the tumours. These Winter,[1] Veit,[2] and others have pointed out may often be felt through the abdominal parietes as ridges on the surfaces. They are most commonly found in the upper and anterior part of the cysts. Occasionally, also, the ovaries may be distinguished, sometimes quite distinct from, but often glued, as it were, to the surface of the tumours. With increase in size of the cysts, however, the ovaries become flattened out, so that they can occasionally only be recognised, after removal of the growths, as a thickening in the walls of the capsules.

Winter has pointed out an "infallible sign" for the differential diagnosis between intra-ligamentary tumours and those lying deep down in Douglas' pouch. It is the relation of the sacro-uterine ligaments to the tumours. If these folds are in front of the tumours, he says, then they are lying in Douglas' pouch; if, however, they are pressed backwards and towards the middle line, then the tumours occupy the broad ligaments. As the author remarks, it is not always possible to make out such a sign.

To differentiate, by bimanual examination, cysts of the broad ligament from those of the ovary becomes, however, more and more difficult, and finally impossible, as the former come to occupy a position in Class 1. The more pedunculated they become the more difficult the diagnosis, for they lose all their characteristics, such as their immobility and their close application to the uterus, &c. In their growth they distend more and more the layers of the mesosalpinx, which generally continues to form a complete capsule, although it may occasionally undergo a partial atrophy owing to the rapidity of the growth of the cyst. This latter occurrence is well illustrated by a case mentioned by Lawson Tait.[3]

The Fallopian tubes and ovaries likewise become more difficult to differentiate as the tumours become pedunculated and increase in size. They are found on the larger tumours, not well up on the surface of the cysts, but close down to the pedicle.

Fortunately, for practical purposes a differential diagnosis between true ovarian cysts and pedunculated cysts of the broad ligament is of little importance, for the treatment is exactly the same in both—viz., ligature of the pedicles and removal of the tumours.

[1] *Gynäkologische Diagnostik*, 1896.
[2] *Gynäkologische Diagnostik*, 1891.
[3] *Op. cit.*, p. 225.

Digitized by Google

There is one feature of these cysts of the broad ligament which I have not referred to, and that is their fluctuation. You will see it always mentioned by writers that to percussion they give a uniform wave of fluctuation over the whole surfaces. It is, however, only in the larger cysts, especially those of the first class, that this can be made out. With the smaller ones only a feeling of elasticity is obtained. The reason that the fluctuation wave is so uniform is of course because true cysts of the broad ligament are always unilocular. Those that appear to be multilocular (and there are examples of these mentioned in the writings of Tait, Bantock, and others) should be termed not multilocular but multiple unilocular cysts.

But even on feeling a uniform wave of fluctuation one is not always correct in concluding that the cyst is unilocular, and consequently of broad ligament origin. As has been repeatedly pointed out, a multilocular cyst of the ovary may, if the walls of the loculi are thin, or if one loculus is very much larger than the others, give an exactly similar sensation to the palpating hands.

Finally, we can come to no conclusion regarding the nature of the cysts, either from the history or from the symptoms complained of by the patient.

Treatment.

The treatment of those cysts of the broad ligament which have become pedunculated—viz., those of the first class—is of course ligation of the pedicles and removal of the tumours. A different treatment, however, is necessary with those of the second and third classes, which are more or less embedded and fixed in the broad ligament and have no pedicles. In these latter cases removal of the cysts is only possible by "enucleation." The operation is best performed from the abdomen, although one or two surgeons have removed them successfully from the vagina.

This enucleation in cysts of the second class is always easy. A transverse incision is made in the capsule, preferably in the upper part, and if possible just below the Fallopian tube, which we have seen courses over the surface of the tumour. By commencing there one usually gets a better start, for the capsule is looser at that part. The cyst is then gradually and carefully shelled out of its bed, care being taken not to rupture it, as the removal is always much easier if its wall is main-

Digitized by Google

tained intact. When possible, and it is often possible, the cysts only should be removed, the ovaries and tubes being left behind.

The treatment to be adopted with cysts of the third class —those embedded deeply in the broad ligament—is likewise removal by enucleation. This, however, is frequently a matter of very considerable difficulty. Thus, Butler Smythe[1] writes regarding the operation—"To my mind there is no operation in abdominal surgery that requires more patience, judgment, and careful handling, than the enucleation of the cyst deeply embedded in the broad ligament." Words similar to these are to be found in the writings of Wells, Keith, Martin, and indeed of all operators of any experience. The difficulties attending their removal are due in part to their depth in the pelvis, and the consequent difficulty in reaching them, but chiefly to the close connections they frequently form with bladder, rectum, and uterus. As a rule, adhesions with these organs may be readily separated, and the cysts removed entire. Sometimes, however, that is impossible, and portions of the cysts have to be clipped off and left behind. Especially is this so in the cases where the adhesions are very intimate with bladder and rectum, for there is danger of inflicting serious injury upon these structures if too forcible attempts are made to bring about a separation.

With the uterus their connections are sometimes extremely close, and often, too, very vascular. This latter fact has been especially remarked by Hofmeier,[2] who has once or twice only succeeded in arresting the hæmorrhage by very careful stitching of the uterine wounds. In these cases, where the connections with the uterus are so very intimate, and where the cysts are bilateral, many have suggested and advocated the removal of the uterus along with the tumours. Amongst a host of others may be mentioned Skene Keith, Spencer, Webster.

Another structure that these deep seated cysts may become adherent to, and may very much displace, is the ureter. The separation is usually not very difficult. One thing, however, I would say regarding the ureters: it is that special care should be taken not to include them in clipping away any portions of the capsules. It is surprising, owing to the displacements they often undergo, how easily it may be done. I have seen a very well-known and brilliant operator remove an inch or so of a ureter when trimming a capsule.

[1] *A First Series of Fifty-four Consecutive Ovariotomies*, 1897, p. 9.
[2] *Grundriss der Gynäkologischen Operationen*, third edition, 1898.

Digitized by Google

The hæmorrhage from the capsules is often very great. Usually it is a general oozing, which can be arrested only by packing, or by bringing the surfaces firmly together by careful stitching. Sometimes, however, individual bleeding points can be recognised and ligatured. Ligation of the ovarian and uterine arteries before removal of the cysts, as has been suggested, is simple enough in the case of the ovarian, but extremely difficult in that of the uterine where the tumours are at all deeply seated. It is questionable if it is of very much advantage.

The treatment of the capsules after removal of the cysts can only be briefly referred to here. For a detailed description I would refer you to a paper by Doran, in the last volume (vol. xxxix) of the London Obstetrical Society's *Transactions.* At present, the safest method appears certainly to be the stitching of the margins of the capsule to the lower part of the abdominal wound, and packing the cavity with sterilised gauze. The other method, adopted by Martin of Berlin and others, of stitching up the sac from the bottom, does not seem quite so safe, especially if there is much hæmorrhage from it. Undoubtedly, however, it is a much more ideal method of treatment.

Now, it must be apparent to all that the removal of "embedded cysts" by enucleation is a more serious operation than the removal of ordinary ovarian tumours or pedunculated broad ligament cysts. One would, therefore, naturally expect the percentage mortality to be higher. In all probability it is so, but unfortunately it is impossible to get statistics on the subject, for, as a rule, all cysts of the pelvis are classed together in published lists; or if those of the broad ligament are separated from the ovarian, as Tait has done,[1] they are not divided up into groups, and the easy and difficult enucleations, the pedunculated and embedded cysts, are placed side by side.

Hofmeier[2] refers incidentally to his mortality in removing these embedded cysts by enucleation. He had eight cases, with two deaths. The only other reference to this particular aspect of the subject, so far as I have discovered, is to be found in a discussion that followed a paper read by Emmet,[3] in 1890, before the New York Obstetrical Society. All who spoke then were impressed with the seriousness and gravity of the operation. Emmet himself reported two cases, with two deaths; Cleveland two cases, with one death; Lee one case,

[1] *Op. cit.*
[2] *Op. cit.*, second edition, p. 378.
[3] *American Journal of Obstetrics*, vol. xxxiii, p. 760.

Digitized by Google

with one death; Mundé nine cases, with four deaths. It must be remembered, however, that these figures are eight years old. I do not for a moment believe that the mortality at the present time is anything like as high as they suggest. It is, however, considerable.

Treatment by puncture and vaginal or abdominal drainage.—My object in mentioning this method of treatment, which has in the present day fallen into such general disuse, is not to advocate its revival, but simply to suggest that, as the mortality is still considerable with enucleation, occasionally it might be wiser to substitute this simpler treatment of puncture and drainage. I have said occasionally, for I believe that there are but few cases in which it is advisable. I am, however, convinced that it sometimes is so. I give an example. It is to Professor Murdoch Cameron that I am indebted for kind permission to incorporate the case in the present paper. I had the pleasure of assisting him at the operation.

Mrs. M'L., æt. 36, was admitted to the Western Infirmary under Professor Cameron in October, 1895. She complained of a tumour in the abdomen of three years' duration. There had been amenorrhœa for the past six years. Nothing special otherwise in history. On examination bimanually a large cystic tumour was felt occupying both iliac regions and extending into hypogastric and lumbar areas.

The diagnosis was a multilocular ovarian cyst.

Operation.—On opening abdomen each broad ligament was found to be occupied by a large cyst extending high up into abdomen and deeply down into the pelvis. On attempting to enucleate the left one the hæmorrhage was so great that it was deemed advisable not to proceed. Both cysts were then incised, margins stitched to lower part of abdominal wound, and drainage-tubes introduced. These latter were allowed to remain in for two days, and were then removed. Recovery excellent.

Subsequent History.—I have seen patient twice since the operation, last time on the 25th March of this year, two and a half years after the operation. There is absolutely no reaccumulation of fluid; the shrunken up remains of the cyst can be felt. She is perfectly well.

If the above case had been treated by enucleating the cysts, and I have no doubt it could have been done with some little care and patience, the uterus would, in all probability, also have had to be removed. Surely, however, puncture and drainage was a wiser treatment in that case; and that is all I am contending for, that occasionally, very occasionally if

Digitized by Google

you like, for enucleation drainage and puncture should be substituted.

It is very unfortunate that we have no exact information regarding the permanent curative effect of treating those cysts we have been considering by puncture and drainage. All the text-books mention in a vague sort of way that puncture occasionally effects a cure, but there is no definite statement regarding the number of cases that remain permanently cured. Keith advocated the treatment very strongly, while Tait, with even greater vigour, condemns it. No one, so far as I can discover, has collected any large number of cases of undoubted broad ligament cysts, and stated how many of these have been punctured and drained, and of this percentage how many have or have not refilled. In my own short experience I have seen only two cases treated by puncture and drainage. In neither have the cysts refilled, and both of the cases were operated on more than two years ago.

The fact that these cysts occasionally contain papillomatous growths in their interior forms an important objection to the treatment by puncture and drainage. The difficulty can always be got over, however, by exploring with the finger the interior of the cyst through the puncture wound. If any papillomatous masses are discovered the cyst must certainly be enucleated. The other objections—viz., the difficulty of the diagnosis and the occasional refilling of the cyst—I have discussed already.

Dr. J. K. Kelly said that the subject was one of interest to operators. His own feeling was that such cysts must, if possible, be removed. One could not trust that the tumour would not refill, nor could one be confident of its innocent nature. If he were to drain, he would not be contented with the vaginal drain, but would pack the interior of the cyst with iodoform gauze, and thus attempt to obliterate it, and prevent refilling.

Dr. Edgar mentioned one case of his in which the cyst lay in front of the uterus, and another where it lay behind, the uterus in both being nearly in the middle line. Fluctuation was usually distinct, as the tumours were unilocular. The specific gravity of the fluid was low. An apparently multilocular cyst was really composed of independent cysts. He recalled a case where a cyst had been mistaken for a fibromyoma, a possibility which Dr. Kerr had suggested. He did not understand how a cyst of the broad ligament could escape from the ligament and not be covered by peritoneum (Dr. Kerr

Digitized by Google

replied that the peritoneum atrophied). The treatment should be either enucleation or ligation of the pedicle. Enucleation was usually quite easy, although it might be difficult low down in the pelvis.

Dr. Kerr, in reply, said that he was surprised that Dr. Edgar had never seen a cyst of the broad ligament in which the capsule was partially atrophied.

MEETING XI.—1ST APRIL, 1898.

The President, DR. G. S. MIDDLETON, *in the Chair.*

I.—FRESH SPECIMENS.

BY DR. BEATSON.

Dr. Beatson showed a fresh specimen of a tumour of the mamma which had a very strong capsule, and presented marked intra-cystic growth. In structure it resembled a fibro-adenoma.

II.—CASE OF MYXŒDEMA WITH DULNESS OF HEARING AND TINNITUS IN A MAN.

BY DR. J. G. CONNAL.

Cases of myxœdema are not uncommon, but are more frequently met with in women than in men, in the proportion of about 7 to 1. The interest in the following case seems to me to lie in the patient's belief concerning the cause of his illness, in his remarkable susceptibility to some drugs, and the fact that the dulness of hearing and tinnitus disappeared under constitutional treatment by thyroid gland extract.

The patient is 36 years of age, and he consulted me in 1891, when he complained of palpitation, shortness of breath, and great weakness. He had a pale, waxy appearance. The eyelids were puffy. There was a marked swelling round his ankles and up on his shins, which did not pit on pressure. The voice was slow and tremulous, skin dry and rough, hair dry and stunted in growth, pulse slow, temperature subnormal. There was no albumen in the urine. At that time I thought it

Digitized by Google

was a case of myxœdema, and treated him with tonics, but with no satisfactory result.

When Dr. Murray, of Newcastle, drew attention to the remarkable effect of thyroid gland in the treatment of myxœdema, I determined to try it. But before doing so, I asked Dr. R. M. Buchanan to see the patient with me. We had no doubt as to the diagnosis, and considered it was a suitable case for the new treatment. The photograph (Fig. 1, p. 128) shows the patient's condition at this time.

At that time there was some difficulty in obtaining the thyroid gland, but we sent to the slaughter-house and got some sheep's thyroids. I gave the patient instructions to take one gland, divide it into three parts, and take one part, viz., one-third of a gland every second or third day. His wife, however, thinking that one third of a gland was a ridiculously small affair, prepared three glands and gave them at one meal. The result was very striking. The pulse rose to 120, temperature was over 100° F. He was sick, vomited, had severe diarrhœa, and developed a well-marked jaundice. For several days he was very ill, and was off duty for two months. Still, when he recovered it was noticed that there was a marked improvement in his symptoms: the swelling was less, he had lost 2 stones in weight, his voice was firmer, and his intellectual capacity much sharper. He was urged to go on with the thyroid gland treatment, but in smaller doses. This, however, his wife absolutely refused to allow him to do. I met him several times after that, and strongly advised him to try the tabloids of thyroid gland which were now being manufactured, but I could not convince him to try it in the face of his wife's opposition.

I lost sight of him till the autumn of 1896, when he came to consult me on account of dulness of hearing and tinnitus in both ears, but worse in the left, which he said had been present for some time, but had lately become more noticeable.

On taking note of his general condition at this time, he appeared much worse than when I had previously seen him. All his symptoms were accentuated. He could not follow out a train of thought. The voice was tremulous, and the speech slow and hesitating. Even allowing for the dulness of hearing, he seemed to have difficulty in understanding what was said to him. When spoken to, it was some time before he returned an answer. He was much stouter than formerly, was easily fatigued, found he had great difficulty in walking, and often tripped and fell to the ground. He complained of feeling the cold very much, his hands chipped easily, and his

Digitized by Google

skin had a hard scaly feeling. He was getting quite bald, and the eyelids were more œdematous looking than formerly.

Without saying anything to him I put him on tabloids of thyroid gland (B., W. & Co.), beginning with half a tabloid night and morning, and gradually working it up to three tabloids per day. These sickened him a little at first, but he

FIG. 1.

Photograph taken in 1891, before beginning treatment.

was persuaded to continue their use, and we have now an opportunity of noting their marked benefit to the patient. The swelling has disappeared, the voice is different, the mental capacity much sharper, the dulness of hearing has gone, the hair is growing a little, and he feels fit for any exertion—in fact, he says he is a new man (Fig. 2, p. 129).

Digitized by Google

A remarkable point in the history of this patient is that he attributes all his symptoms to the administration of iodide of potassium.

On 26th November, 1886, he was admitted to the Western Infirmary complaining of pain over the sacral region and passing down the front of both legs as far as the ankles. For

FIG. 2.

Photograph taken in 1897. Patient had then been some months under treatment.

this condition he was treated with iodide of potassium, and there is a note in the ward journal to the following effect:—"This patient reacted in a peculiar manner to the administration of iodide of potassium. On Tuesday evening (30th November) he was given a dose of 10 grs. Next morning he was in a comatose condition. The lymphatic glands in the

Digitized by Google

neck were excessively swollen, and his eyelids were so œdematous that vision was impossible. The patient described his condition as that of impending dissolution. The symptoms disappeared in two days, but it was thought advisable to discontinue the administration of the medicine." He was subsequently treated with subcutaneous injections of morphia, and made a good recovery, leaving the hospital on the 8th December.

Previous to his admission to the hospital he had been under the treatment of his own medical attendant, who prescribed a mixture containing iodide of potassium. I have seen this prescription, and the patient tells me that after one dose of the medicine (containing 2 grs. of iodide) he had severe headache, extreme pain in the throat and eyes, and watery discharge from his eyes and nose. He took no more of that mixture, but went to the hospital, and was admitted, with the result above noted.

He dates all his illness from this time. He says the swelling of his eyelids never disappeared, his hair came out very freely, and he had stiffness in his limbs. He became irritable, easily worried, and very stout.

I give the statement of the patient and his determined belief in the iodide of potassium as the cause of his illness, but there is one rather interesting point noted in the journal of the Western Infirmary—viz., that when he was admitted in November, 1886, there was noticed to be a slight swelling round his ankles, which did not pit on pressure, and he stated then that he had great difficulty in keeping himself warm—he used to shiver at nights, and take cramp in his legs.

Writers on therapeutics admit the action of iodide of potassium on the thyroid gland, and we acknowledge its influence by prescribing the drug in goitre, where we suppose the enlargement is not due to cystic conditions. Seeing, then, that it is admitted that iodide of potassium has the effect of diminishing hypertrophies of the thyroid gland, can any explanation be given for the patient's belief that his illness was induced by the administration of the drug? If one might hazard a conjecture, it is that there was an incipient myxœdema on his admission to the Western Infirmary in 1886, evidence of which might be deduced from the swelling round his ankles, which did not pit on pressure, and the cold, shivery sensations of which he at that time complained. If this is so, then the administration of iodide of potassium might possibly have

Digitized by Google

accelerated the progress of the disease. On glancing over the symptoms of iodism one is struck by the similarity of some of its manifestations to those of myxœdema—the action on the mucous membranes, the puffy œdematous condition of the eyelids, the physical and mental depression. If it is objected to this view that in this case the dose of the drug was small, on the other hand one can point to a remarkable susceptibility of this patient to its influence.

I would draw attention to the condition of the mucous membranes in this case; that covering the inferior turbinated bone in both nostrils was greatly swollen and lying against the septum, while the uvula was elongated and wrinkled.

A portion of the pendulous uvula was cut off with scissors, and it was intended to treat the hypertrophied inferior turbinated bodies, but on his return after taking the thyroid tabloids it was noticed that the membrane was not so much swollen, and so nothing further was done to it. He was very dull of hearing when he came, indeed it was this dulness of hearing which led him to consult me. The symptoms and objective examination of the ears pointed to an obstruction of the Eustachian tubes as the cause of the deafness. The watch, which should be heard at 40 inches, was only heard at 1 inch on the right side, and half an inch on the left. The tuning forks were better heard by bone than by air conduction. The ears were gently inflated by Politzer's method, but not much of the air douche reached the tympanum, and, consequently, it had very little effect in improving the hearing. The mucous membrane of the tympanum is continuous through the Eustachian tubes with that covering the naso-pharynx, nose, and pharynx. We have already noticed that the mucous membrane in these parts was greatly swollen, and one is quite justified in supposing that the mucous membrane in the Eustachian tubes and tympanum was in a similar condition. This swollen, hypertrophied condition of the mucous membranes improved markedly under the thyroid treatment, and, coincident with this, there was an improvement in the hearing, so that now, while there is still a little evidence of hypertrophic rhinitis, the hearing is perfect, and the tinnitus has disappeared.

This improved condition of the mucous membranes and of the hearing under the influence of thyroid extract is worthy of notice. The gland extract has been used in the treatment of almost every disease. On the Continent it has been given

Digitized by Google

to patients with dulness of hearing. At the Austrian Otological Congress in November, 1896, Dr. Bruhl drew attention to a number of cases he had treated with thyroid tabloids in Politzer's clinic. Twenty-one patients were treated; of these, fourteen remained under continuous observation. Of the fourteen, eight received no benefit, either subjectively or objectively. Of the remaining six, four improved considerably and two very much.

Dr. Alt, who had conducted similar investigations in Gruber's clinic, also spoke of the benefit he had derived from the use of the drug in cases where, after a suppurative condition of the middle ear, cicatricial contraction and adhesions had formed.

As I had seen the drug employed in several of these cases, and apparently successfully, I determined to give it a trial. I did so in twelve cases at the Ear Hospital and in private, but with rather disappointing results. In ten of the cases the result was negative, in two there was apparently a slight improvement. One of these, an hospital patient, I lost sight of, and in the other the benefit was only temporary.

In the class of case I selected there was evidence of sclerosis of the middle ear; but perhaps I subjected the drug to too severe a strain, for I only employed it after all other methods of treatment had been tried unsuccessfully.

I saw no bad result from giving the drug, but in two of the patients, after using the gland extract for some time, a peculiar slatey-blue appearance of the conjunctiva was noticed.

Dr. Walker Downie said that he had seen a similar disappearance of thickened tissue in the nares and fauces in cases treated by thyroid extract.

Dr. R. M. Buchanan had seen the case with Dr. Connal. It was the first he had seen in a man. He had seen seven cases in women, and this proportion was exactly that given in the statistics of the disease. The disappearance of the creaky or leathery character of the voice under treatment was to be accounted for in the same manner as the disappearance of the thickening of the nares and fauces.

Dr. Middleton had seen, including the present case, three examples of the disease in males. The effect of treatment on the mucous membrane was fairly well known. Laryngoscopic examination during life did not show marked thickening of the vocal cords. He had found the thickening most pronounced in the soft palate.

Digitized by Google

III.—A MASS OF ENLARGED CERVICAL GLANDS EXCISED ALONG WITH A PORTION OF THE INTERNAL JUGULAR VEIN.

BY DR. BEATSON.

Dr. Beatson showed a patient from whom a mass of enlarged cervical gland had been excised along with a portion of the internal jugular vein. He said that the operative treatment of strumous cervical glands must vary according to the extent to which they were involved. If a whole mass of glands were affected, as in this case, they would be found matted and adherent to veins. Operation should be resorted to only after improvement of the general health by constitutional treatment, and a careful diagnosis of the local conditions should be made. The operation in this case was done by Senn's modified S-shaped incision, the resulting cicatrix not being so unsightly as that of the oblique incision. It was decided to ligature the internal jugular vein, as Watson Cheyne advised. The vein was then stripped up and religatured, the portion included between the ligatures being removed along with the entire mass of glands. He found fine horsehair the best suture for operations about the face. If any of the glands were softened, they should be previously punctured and stuffed.

Dr. Wyllie said that such an incision involved a large flap, which might give rise to difficulty if the glands had suppurated.

Dr. Rowan asked if there were no glands involved elsewhere.

Dr. Beatson replied that there was some risk of sloughing with the large flap. The vitality of the skin might be interfered with if several glands were adherent and the skin were reddened. In that case it might be an open question what incision to use. There were no other enlarged glands.

IV.—ON WHITE BLOOD CORPUSCLES.

BY DR. W. K. HUNTER.

Ever since the invention of the microscope, white blood corpuscles have been among the objects of greatest interest to the histologist, and at no time has this been greater than at the present. Indeed, for some years past, white blood corpuscles have held pre-eminence over all other cellular elements; for has it not been shown how it is they that constitute the army on which our bodies depend for defence against that most relentless foe, the pathogenic micro-organism? It is

Digitized by Google

true that much of the enthusiasm shown in these blood corpuscles has expended itself in theorising as to the nature of their weapons and their methods of warfare; but, besides this, many valuable observations have been made as to their composition, minute structure, and life history, and it is this aspect of the subject we have now to consider.

As far back as fifty years ago it was recognised that there were present in the blood several varieties of leucocytes, differing from one another in their size, shape of nucleus, and in having a hyaline or granular plasma. But it was not till Ehrlich published his researches (1878-87) that anything like a definite classification could be laid down; for Ehrlich's classification took note, not only of the morphological characters of the corpuscles, but also of their chemical affinities for certain of the aniline dyes. We know that the aniline dyes can be divided, according to their reaction, into two groups:—(1) The "acid" dyes, and (2) the "basic" dyes. Though called "acids" and "bases" these pigments are in reality not so, for, from their chemical composition, they are salts. But in the "acid" dye it is the acid part of the salt that is the staining element, while with the "basic" dye, it is the basic part that stains; and this is why they are called "acid" and "basic."

Now, Ehrlich found that the granules of certain leucocytes would stain with an "acid," but not with a "basic" dye, their granules were what he called oxyphile; but, on the other hand, there were corpuscles whose granules only stained with "basic" dyes, these he called basophile. And so he classified the white blood corpuscles according to the staining reaction of their granules. He likewise compounded a "neutral" stain made up of an "acid" and a "basic" stain, and he maintained that in certain corpuscles the granules were neither oxyphile nor yet basophile, but neutrophile. This, however, has since been proved to be incorrect, for it has been shown[1] that a truly neutral dye does not stain these granules at all, and that it was really the acid element of Ehrlich's neutral stain that was doing the staining.

But not only do the granules of the various kinds of corpuscles have a special affinity for certain dyes, they also stain with these dyes in different degrees of intensity. This is well illustrated in staining the nuclei of the different kinds of leucocytes, and by those corpuscles that contain oxyphile granules. The staining power of the dye, moreover, depends on the nature of the solvent used. Eosine, for example, stains

[1] Kanthack and Hardy, *Journal of Physiology*, vol. xvii.

Digitized by Google

much better in aqueous than in alcoholic solutions, and some oxyphile granules which stain with watery solutions of eosine will not stain with alcoholic solutions of that dye. We have in this, therefore, another factor in the classification of leucocytes, for we distinguish those corpuscles whose granules stain with all solutions of eosine as being strongly eosinophilous, from the ones whose granules only stain with watery solutions of eosine, and which are therefore faintly eosinophilous. It is also to be noted that heat increases the intensity of a stain, presumably because it renders it more soluble, and therefore a more completely saturated solution.

With a view then to examine the properties of a white blood corpuscle in regard to its reaction with the aniline dyes, it is customary to "double" stain it, using both an "acid" and a "basic" dye; and as eosine and methylene blue are respectively good examples of such stains, they are the pigments most commonly used for this purpose. In staining white blood corpuscles, then, one proceeds as follows:—A small drop of freshly drawn blood is allowed to spread itself out between two cover-glasses, which are immediately thereafter slid apart one from the other. The films are allowed to dry at the temperature of the room, and when dry, fixed by passing the covers through the flame of a Bunsen burner. But as this does not seem to fix all the elements of the corpuscle, it is well to now place the covers for a few minutes in alcohol—a 70 per cent solution I find answering the purpose quite well. On removal from the alcohol the preparations are allowed to dry, and then placed for a few minutes in a solution of eosine.[1] They are next thoroughly washed in water, allowed to dry, and again fixed in the flame. They are then placed for a few minutes in the methylene blue solution,[2] next washed, dried, and mounted in Canada balsam.

We are now in a position to consider the more intimate structure and varieties of the different leucocytes that have been met with in the blood. But, in the first place, there is a difficulty in terminology, for each writer on the subject seems to have his own classification and his own special names for the different kinds of corpuscles. I shall therefore, for the sake of clearness, give, in tabular form, the classifications of four of the more prominent writers—Ehrlich, Metschnikoff, Kanthack, and Gulland.

[1] I use the following solution :—Eosine, 1 grm. ; rectified spirit, 40 c.c.; water, 160 c.c.

[2] Löffler's solution does admirably.

Digitized by Google

These are as follows:—

EHRLICH.	METSCHNIKOFF.	KANTHACK.	GULLAND.
Eosinophile cell (granulation α).	Eosinophile.	Coarsely granular oxyphile.	Eosinophile.
Neutrophile (granulation ϵ).	Polynuclear.	Finely granular oxyphile.	Oxyphile.
Lymphocyte.	Lymphocyte.	Lymphocyte.	Lymphocyte.
Mononuclear, finely granular basophile (granulation δ).	Mononuclear.	Finely granular basophile. Hyaline.	Small basophile finely granular. Small hyaline. Large hyaline.
Amphophile (granulation β).	...	...	...
Mastzellen (granulation γ).	...	Coarsely granular basophile.	Large basophile coarsely granular.

As to the above classifications, then, we may say with confidence, that not one of them is perfect, for no classification ever is; but for purposes of description they are convenient, and as these four differ less in their groupings than in terms, we may keep all of them before us while we consider in detail the various corpuscles with which they are concerned.

The first group in all four lists comprises the *coarsely granular oxyphile*, or *eosinophile* corpuscle of granulation α, and as it has well-defined characters there is little difficulty in its recognition. The eosinophile corpuscle has a diameter of from 10 to 11 μ. Its nucleus, which takes the form of a bent bar or sometimes of a horse-shoe, contains a distinct nuclear network, and it stains rather less deeply than the nucleus of the polynuclear corpuscles. The cell plasma seems to be transparent, and it is filled with large, coarse, well-defined spherical granules, of high refractive index, which stain intensely with eosine, even in strong alcoholic solutions. These granules contain no hæmoglobin, nor are they fatty granules; they seem to be albuminoid in composition, and in that respect related to the nucleus of the cell. The eosinophile corpuscles possess amœboid movement, but they are not phagocytic. They are rare in normal blood (2 to 4 per cent of all the leucocytes), but are found in greater abundance in the cœlomic

Digitized by Google

fluid, in areolar tissue, in red bone marrow, and in the blood in cases of spleno-medullary leukæmia.

The second corpuscle to consider is the *finely granular oxyphile* leucocyte, which is, without doubt, identical with the "*polynuclear*," and the "*neutrophile*" cells of granulation ε. It is rounded in shape, measuring from 8 to 9 μ. Its nucleus is very irregular in outline, often forming several little portions, connected by fine filaments, and it contains a close network of fibres which stain deeply with methylene blue. The plasma is clear though faintly oxyphile, and it contains a fine granulation which is likewise feebly oxyphile—*i. e.*, which only stains with eosine in weak alcoholic or watery solutions. This is the most common leucocyte found in the blood, forming about 75 per cent of those present. It is phagocytic and actively amœboid.

As to the *lymphocyte*, there is little difference of opinion either as to its structure or function. It is a small round cell, measuring 6 μ in diameter, and it has a deeply staining nucleus which fills up almost all the cell. The narrow margin of plasma surrounding the nucleus seems to be hyaline, and like the nucleus, it stains with basic dyes, though much less intensely. The lymphocyte has no amœboid movement and it is non-phagocytic. It forms from 15 to 25 per cent of all the leucocytes in the blood, being increased after food and lessened with starvation. It is doubtless formed in the various lymphoid tissues scattered throughout the body.

With these three kinds of leucocytes, the eosinophile, polynuclear, and lymphocyte, there is little difficulty in their designation or classification, for they each have well-defined characters, and are, therefore, easily identified. It is true that in bone marrow and in the blood of some cases of leukæmia, we find gradations between the two former, where the question may arise as to whether the corpuscle is finely granular or coarsely granular; but the eosinophile and polynuclear corpuscles, as we meet with them in normal blood, have scarce any resemblance, and there is no difficulty in distinguishing them.

But with those corpuscles which yet remain to be considered—the basophile cells—the task of description and classification is much more difficult; for one finds all gradations, both in regard to the size of the cell and the condition of its plasma, between the lymphocyte and hyaline cell on the one hand, and between the lymphocyte and coarsely granular basophile cell on the other. With so many intermediate forms, then, one cannot do more than describe certain types

Digitized by Google

from amongst them; and it is with this reservation that we proceed to consider these basophile cells.

The first of them to describe is the *hyaline* cell—the *mononuclear leucocyte* or *macrophagocyte* of Metschnikoff. It measures from 8·5 to 10 μ in diameter. Its nucleus is spherical or kidney-shaped, and shows a fine nuclear network forming comparatively large meshes. This nucleus stains much less intensely than does that of the lymphocyte, probably because in the latter the fibres of the network are much more closely placed together. The plasma of the hyaline cell is abundant, and is described as being "hyaline," but it is not so, for with a high power it can be seen to contain fine basophile dots which Gulland[1] says are the "knots" of a very fine network forming the stroma of the cell. The hyaline corpuscle forms about 2 per cent of all the leucocytes in the blood. It is amœboid and phagocytic, and is probably the mature form of the lymphocyte, or at least of some of the lymphocytes, for we have seen all gradations of mononuclear cells may be found ranging between the lymphocyte and the large hyaline cell. The hyaline cell, Metschnikoff[2] says, developes into the epitheloid and giant cells.

Another form of basophile cell has been described by Kanthack and Hardy[3] under the name "*finely granular basophile corpuscle.*" It measures 7 μ, being the smallest of the amœboid cells in the blood. It has, they say, a trilobed nucleus, and the clear structureless surrounding plasma (which colours a purple or pink tinge) contains an immense number of minute granules which stain opaque blue or purple. It is said to form from 1 to 5 per cent of all the white blood corpuscles, being most abundant about two hours after a meal, when it is also seen to be most completely charged with its granules.

This, I presume, is the same corpuscle as that of Ehrlich with granulation δ, and as what Gulland would consider an intermediate stage in the development of the large coarsely granular basophile corpuscle. But as far as my observations have gone, that corpuscle has not, as a rule, a trilobed nucleus —it is more often spherical—neither has its plasma a pink tinge, nor yet its granules a purple colour, when stained with methylene blue. I have seen certain polynuclear corpuscles which would almost answer to the description given by Kanthack and Hardy; but then the pink of their plasma and

[1] Gulland, *Journal of Physiology*, vol. xix.
[2] *Comparative Pathology of Inflammation*, 1893.
[3] Kanthack and Hardy *Ibid.*

Digitized by Google

the purple of their granules was certainly due to the eosine of my double stain, for when stained with methylene blue only, the plasma remained clear. They were, therefore, not basophile corpuscles. It is possible that some of these so-called finely granular basophile cells are transition forms between the lymphocyte and the polynuclear corpuscle; but of this I have no certain evidence, and that such a transition ever takes place, is still a matter of much doubt.

We now come to the *coarsely granular basophile corpuscle* of Kanthack and Hardy; and it seems to be pretty much the same leucocyte as Ehrlich's cell with granulation γ, as the "*mast*" *cell* (mastzellen), and as the *myelocyte* or marrow cell. It has been described as a large flattened cell, measuring 12 μ or more. The nucleus is rounded and stains, as a rule, feebly; but sometimes it is found deeply stained, and this is said[1] to occur in the older cells and in those with more active movement. The plasma of the cell is clear and does not stain with basic dyes, but it is filled with large basophile granules which usually stain much deeper than the nucleus, and sometimes completely hide it from view. This coarsely granular corpuscle is found normally in the connective-tissues and in the cœlomic fluid; but only in the blood in certain morbid conditions, the most notable example being spleno-medullary leukæmia. It is non-phagocytic, and as a rule has little amœboid movement.

The above description of this coarsely granular corpuscle seems to be the one commonly accepted by most writers on the subject. It may hold good for those corpuscles as found in the body cavities and connective-tissues—of this I have had no experience; but it certainly does not apply to those corpuscles as found in the blood in all cases of leukæmia, for I can prove an exception. Quite recently I have had the opportunity of examining the blood in two cases of leukæmia, and in both I found the so-called basophile granules to stain, not only with methylene blue, but also with eosine, showing them to be not basophile only, but amphophile; otherwise the corpuscles presented all the appearances characteristic of the marrow cell. When stained with methylene blue only, I could distinguish four different forms of this cell:—(*a*) A cell similar in appearance to the hyaline cell, but usually containing some slight and indefinite granulation of its plasma. (*b*) A cell usually larger than the last, but with a deeper stained nucleus (nearly as deep as the nucleus of the polynuclear corpuscles), and a plasma containing distinct granula-

[1] Gulland, *Journal of Physiology*, vol. xix.

Digitized by Google

tion, much lighter in colour than the nucleus. (*c*) Nucleus large, filling the greater part of the cell, and staining faintly; the small ring of surrounding plasma containing deeply stained granules. (*d*) Cells usually rather smaller than those of the the last two groups, but with a plasma more or less completely filled with deeply stained granules, which could not be easily distinguished from the nucleus. The granules in this cell were coarser than those of the other groups. Speaking generally of the cells in all these groups, it might be said that the larger the nucleus the fainter did it stain, and the less the amount of surrounding plasma the deeper in colour were its granules.

When similar preparations of this blood were stained with eosine only, it was found that the granules of all the above forms of myelocytes were also faintly oxyphile, *i.e.*, they stained with eosine with an intensity similar to that of the granules in the polynuclear cells, many of which were to be seen in the same field alongside these marrow cells. It is to be noted, however, that the granulation of the marrow cells, though staining the same, was usually much coarser than that of the polynuclear corpuscles.

Other preparations, again, were double stained with eosine and methylene blue, with the result that in those specimens where the fine oxyphile granules of the polynuclear cells were well stained, the granules of our marrow cells were pink; while in those where the granules of the polynuclear cells were very faintly stained, the granules of the marrow cells were blue. In some other preparations, again, the granules of the marrow cells seemed to have stained both with eosine and methylene blue, for they had a distinctly purple colour—a colour which may be produced by mixing red with blue. All this, I take it, points to the fact that these granules are amphophile, staining with eosine or methylene pretty much according to the respective strengths of these dyes. I cannot find in my preparations any confirmation of the view[1] that these marrow cells contain both basophile and oxyphile granules lying one alongside the other. And I wish to emphasise the fact that all the marrow cells from the blood of these two cases of leukæmia were amphophile, for after carefully examining numerous preparations, I could find no evidence of the presence of a marrow cell with purely basophile reaction. It is scarcely necessary to add that these amphophile corpuscles are not the large eosinophile corpuscles also found

[1] Buchanan, *Journal of Pathology and Bacteriology*, vol. iv, 1896.

Digitized by Google

in the blood in leukæmia—corpuscles, which in size, shape of nucleus, and general appearance, resemble these amphophile cells, but differ from them in containing large eosinophile granules. The granules in these eosinophile cells are strongly eosinophilous, while those of the amphophile cells are but faintly so, even in the corpuscles whose granules are the coarsest. It may be that the amphophile corpuscles form a stage in the formation of this large eosinophile corpuscle, for Kanthack and Hardy[1] have shown that there is a stage in the elaboration of the eosinophile corpuscle of the frog where that corpuscle is likewise amphophile.

In regard to the minute *structure* of the various white blood corpuscles little remains to be said. Each corpuscle has a reticular nucleus, staining with varying degrees of intensity in the different kinds of leucocytes, the intensity of the stain probably depending on the closeness of the nuclear network and on the thickness of its individual strands. As to the rest of the cell, Gulland[2] has shown us that it also contains a meshwork (the mitoma) of fine filaments, forming an outer network continuous with that of the nucleus. The "granules" in the cell are the "knots" (the microsomes) of the network, the coarsely "granular" corpuscles having a coarse mitoma with large microsomes, while the finely granular cells have a fine mitoma with fine microsomes. The "granules" of the cells, then, though almost always staining somewhat differently from the nucleus, and looking like granules, are not granules, nor yet products secreted by the cell, and lying free in the cell plasma; but they belong to the stroma of the cell, and are as much a part of the cell as the nucleus itself. Gulland thinks that the cell mitoma has to do with amœboid movement—if not the source of movement, the means by which it is carried out—the mitoma and microsomes being coarsest in those cells most actively motile. In support of this view he reminds us that the very active eosinophile corpuscle has very large microsomes, while the microsomes of the sluggish hyaline cell are with difficulty made out.

Of what has just been said as to the structure of the leucocyte, any observations I have made are in agreement more or less with those of Gulland. In the finely granular oxyphile, and in the basophile cells, even with a one-eighteenth or one-twelfth oil immersion lens, the network of the stroma seemed undoubted; but in the eosinophile cells, on the other

[1] Kanthack and Hardy, *Philosophical Transactions*, 1894.
[2] Gulland, *Journal of Physiology*, vol. xix.

Digitized by Google

hand, I could never make out any filaments connecting the eosinophile granules. This last may be due to my methods of staining, or to the rupture of their connecting filaments, which, as a matter of fact, must often take place; for it is a common occurrence to find large eosinophile granules lying outside of, and quite free from, the plasma of their corpuscle.

The *origin* of the different kinds of leucocytes and their relationships one to another is a subject still in dispute, and one on which any observations I have made throw little light. I shall content myself, therefore, with a brief statement of two opposite points of view taken up by certain writers on the subject. The first is that of Gulland.[1] He says that, as a rule, all kinds of leucocytes are derived from the lymphocyte (which is the form of all young leucocytes), and that the special characters which these leucocytes subsequently develop are determined by the functions they assume and the environment in which they live. The shape of the nucleus depends on the size and activity of its owner, the nucleus becoming bent (horse-shoe shaped) when the cell is not large enough to to let it lie straight, or becoming multipartite (polynuclear) in the more active cells so as to allow of their passing more readily through narrow apertures. The "granulation" of the cell, we have already seen, Gulland considers also to be determined by the cell's activity. When not too much specialised one kind of leucocyte may, through change of function, take the characters of another. For example, a small hyaline cell may become a polynuclear corpuscle, and a polynuclear corpuscle an eosinophile corpuscle; or, a finely granular basophile cell may become a large basophile cell; but the eosinophile cell cannot become a large basophile cell. These more highly specialised cells do not themselves readily divide and so multiply, but any lymphocyte may develop into either of them if circumstances determine it so.

The other point of view is that taken by Hardy and Kanthack, who maintain that the various kinds of leucocytes are generically quite distinct, and that the rounded nucleus of the hyaline cell, the polymorphous nucleus of the polynuclear cell, and the horse-shoe nucleus of the eosinophile cell are all true morphological features, and not due to environment. They recognise that the hyaline cell is the mature form of the lymphocyte, and must therefore have its origin in lymphoid tissue; but they seem to think that special regions exist for the proliferation of the other kinds of leucocytes—*e.g.*, the

[1] Gulland, *Journal of Physiology*, vol. xix.

Digitized by Google

intestinal wall for the polynuclear cells, and the lining membranes of the body cavities for the eosinophile and large basophile cells.

As to the *functions* of the different kinds of white corpuscles found in the blood, much in recent years has been written, but with this aspect of the subject I do not propose to deal otherwise than in the form of a most brief *résumé.* The lymphocyte, we have seen, is an immature cell, and as such its function is to grow and become mature. The same, I take it, applies to the finely granular basophile cell. The corpuscles classed under the title "coarsely granular basophile cells" are not found in the blood in health; and why they should be there in cases of spleno-medullary leukæmia has not been satisfactorily explained. They are probably derived from the bone-marrow, where similar cells are to be found; but more than that we do not know, and even of that we are by no means certain.

The remaining three kinds of corpuscles—the hyaline, polynuclear, and eosinophile—are concerned in the various inflammatory processes which take place in the tissues. These corpuscles probably all contain, and excrete under certain circumstances, certain substances which have been called antitoxins, and which are supposed to neutralise the poisonous action of the toxins produced by the different micro-organisms. But not only do the substances secreted by these corpuscles neutralise the toxins of the micro-organisms, they also seem to have a paralysing action on the micro-organisms themselves. This at least seems to be so in regard to the eosinophile cell, which is non-phagocytic, and which therefore can only produce its effect on the adjoining micro-organism by means of an excretion. The hyaline and polynuclear cells, on the other hand, are phagocytic—*i.e.*, they take up into themselves and digest the micro-organisms whose condition will permit it. Probably the eosinophile corpuscle, by its secretion, so paralyses the micro-organism as to render it possible for the phagocyte to swallow it up, and so remove from the tissues a source of irritation. This explanation is strengthened by the observation that the eosinophile corpuscle always arrives at the seat of irritation, and attaches itself to the irritating micro-organism some time before the appearance of either of the phagocytes.

From the above it will be understood how it is that in most chronic diseases an examination of the blood reveals an increase in the number of white blood corpuscles—a response, doubtless, to the presence in the circulation of the irritant

Digitized by Google

which causes the disease. In many acute illnesses, on the other hand, the number of leucocytes in the blood is less than normal, due probably to destruction of phagocytes by a virulent micro-organism. Convalescence brings back again the proper number of white corpuscles; and, indeed, the crisis of a fever may often be predicted by noting an increase, in place of the former deficiency, of these corpuscles. The increase means that the phagocytes no longer succumb to the virulence of the micro-organism, but that they will now succeed in eliminating the micro-organisms from the circulation.

V.—CARD SPECIMENS.

DR. ALEX. FERGUSON showed specimens from a case of malignant endocarditis.

DR. R. M. BUCHANAN showed macroscopic and microscopic specimens of a sporozöon in a fish.

MEETING XII.—15TH APRIL, 1898.

The President, DR. G. S. MIDDLETON, *in the Chair.*

I.—CASES OF SPINA BIFIDA.

A. DR. A. N. M'GREGOR.

Dr. M'Gregor showed two cases in which the radical operation for the cure of spina bifida was performed. The first case was chiefly interesting on account of the situation of the growth at the level of the second and third cervical vertebra. The appearance of the tumour at birth showed that it had, at a previous date, been larger, for its surface was wrinkled and there was only a small quantity of fluid in the sac. Pressure produced little or no change in size, and had no effect on the fontanelles; it was therefore diagnosed as an old spina bifida which had healed spontaneously, or that the opening in the spinal canal was very small. Two months later it was seen that the tumour had increased to the size of a tangerine orange, and it also produced signs of irritation on pressure.

The operation described by Mayo Robson was performed

Digitized by Google

with a further precaution against escape of cerebro-spinal fluid —by means of an assistant's finger introduced immediately on opening the sac so as to block up the vertebral opening till the sutures were in position, and only removed as the sutures were tied. The proximity to the brain made this precaution advisable.

The child made an uneventful recovery, being dismissed well fourteen days after operation.

The second case was a larger tumour in the lumbar region, the walls were thin, and there was a slight serous exudation from its surface. The tumour was translucent, showing strands adherent to the inner wall of the sac. The skin only extended an inch from the base of the tumour, so that the flaps had to be dissected from the lumbar region on both sides. The strands were cut off, as they did not appear to consist of nerve elements, and the fact that the bowel and bladder functions are unimpaired confirms that view.

The child was dismissed well in seventeen days.

B. By Dr. J. H. Nicoll.

Dr. Nicoll also showed a case of spina bifida, which he said formed a contrast to Dr. M'Gregor's, as it was impossible to excise the whole sac. He therefore excised portions of the sac between the nervous elements, and also between the nerve strands. He then scratched and roughened the anterior portions of the sac where incisions were not safe. The patient was a girl, now aged 7, suffering from a spina bifida in the lumbar region, which had gradually increased in size. She was brought to him at the age of 5, when she had nearly complete paralysis of the legs, incontinence of urine, and incontinence of fæces alternating with flatulence. The tumour was sessile, and measured 8 inches by 9 inches across the summit. The above mentioned operation was performed. She was confined to bed for three months afterwards, and then a gradual improvement in the condition of the legs, the bladder, and the bowel began to manifest itself. At the present date (two years afterwards) there was perfect control of the bowel, and, during the day, of the bladder, though there was still incontinence of urine at night. The legs had almost completely recovered. A good deal of bulging had been left.

Dr. J. A, Adams said that the use of Morton's fluid was not advisable in the majority of cases, as it was impossible to predict the ultimate result. He had not seen many cases with

Digitized by Google

unmistakable nerve elements in the sac, although he remembered a few. In one case, similar to Dr. Nicoll's, he had had a good result as far as concerned the operation, but there had been no improvement in the symptoms. He had often seen cases of nocturnal incontinence where there had been a condition approaching to spina bifida. It would be interesting to see if the condition of the bladder in Dr. Nicoll's case would improve commensurately with that of the legs.

II.—COMPLETE EXCISION OF THE PYLORUS, WITH NOTES OF A SECOND CASE.

BY DR. J. A. ADAMS.

The radical operation for removal of cancer of the pylorus has not been extensively practised in this country, judging from the number of cases published, and the success obtained has not been sufficient to encourage surgeons to attempt the operation. Most of our text-books mention the operation only to discredit the procedure in favour of some of the palliative modes of treatment, such as gastro-enterostomy.

Continental surgeons have given more attention to this operation. In the report of my first case (*British Medical Journal*, 18th April, 1896) I quoted cases by Wölfler, Rydygier, and Kocher, who each had a measure of success, particularly the last named. In this connection it is interesting to note that the first operation was performed on animals by Winiwarter and Gussenbauer; on the human subject by Billroth. The mortality according to Bramer (quoted in the *American Text-Book of Surgery*), who collected seventy-two cases, was 76 per cent.

Hahn (*Berliner Klin. Woch.*, 1891, p. 853) divides the cases he has collected into two periods, viz., before 1885, and 1885 to 1891. During the first period he found that in seventy-two operations for carcinoma the mortality was 77 per cent, and during the later period thirty-four cases gave a mortality of 41 per cent. Guinard's statistics are somewhat similar, showing a mortality of 71 per cent before 1881, and of 52 per cent since 1887. Of four cases with the aid of Murphy's button there were three deaths.

So far the results have perhaps warranted the disfavour with which this radical operation is regarded, and I feel that this is to a great extent due to the difficulty of performance and long duration of the operation.

Digitized by Google

My object in publishing this case is to emphasise the points set forth in the report of the previous case, believing that a fuller appreciation of them will lead to a greater measure of success in future.

In the first place, rapidity of operation is of the first importance. The shock of prolonged exposure and manipulation of the stomach is so great that many patients never rally at all, and the few who survive the immediate effects do so with their vitality so impaired that they are unable to stand the necessarily imperfect alimenation of the first week.

The use of clamps has been avoided in these operations, for I prefer to trust to the fingers of an assistant, believing that less injury is sustained by the delicate tissues, that there is less risk of subsequent hæmorrhage, and knowing that the parts may thus be more readily brought and kept in apposition.

The continuous suture with catgut possesses the great advantage over the interrupted suture of saving time; it also renders the line of union more elastic, and, though one stitch should cut or tear, the serous surfaces are yet kept in apposition sufficiently to favour immediate union. At short intervals of eight to ten stitches a knot should be made to prevent undue tension.

In these cases the opening of the stomach after excision of the tumour was reduced by suturing the upper border, so that the cut end of the duodenum was atttached to the greater curvature of the stomach, as recommended by Billroth.

Before proceeding with the details of this case, let me briefly recapitulate the salient features of the previous one and add the subsequent history.

The patient was an old woman, who gave her age as 65 years, but who looked at least ten years older, was much emaciated, and apparently dying of inanition. On 19th July, 1895, the operation was performed by means of a straight central incision, through which the tumour was drawn and excised with an inch of healthy tissue on both sides. The upper end of the wound in the stomach was stitched with a continuous Lembert suture—catgut being used—till the resulting lumen equalled that of the duodenum, and these were brought together and sutured in a similar manner, beginning at the posterior surface. With the exception of some delirium on 30th July, due to over stimulation, she made a thoroughly good recovery, was out of bed on 21st August, and dismissed on 11th September.

The tumour was a carcinoma occupying the whole extent of

Digitized by Google

the pylorus, and occluded the opening to the diameter of a No. 12 catheter. The patient reported herself from time to time as perfectly well and quite able for her housekeeping duties; she increased markedly in weight, and her colour improved. A year after the operation she had a slight left hemiplegia, from which she recovered. She went to Ireland soon after, and while there (March, 1897) suddenly became unconscious, and remained in that condition for a week, when she died. Until the onset of the fatal illness she ate well, and was free from nausea, vomiting, and other digestive troubles.

Unfortunately she died in a remote district, at some distance from medical aid, and therefore no *post-mortem* examination could be obtained. The satisfactory element in the case is that she lived twenty months in comfort, so far as her digestive apparatus was concerned, though almost *in extremis* when the operation was performed.

This second case was admitted to Dr. D. C. M'Vail's wards in the Royal Infirmary on 29th April, 1897, whence he was transferred to the surgical wards under my care on 25th May. The medical report, for which I am indebted to Dr. M'Vail and his house physician, Dr. Davidson, is as follows:—

J. C., æt. 70, male, admitted on 29th April, 1897, complaining of pain in the stomach after meals, sour eructations, and vomiting.

History.—Eighteen months ago the patient began to complain of acid eructations and the belching of large quantities of sour-tasting gas. His appetite was also failing, and these symptoms continued till two months prior to admission, when he began to vomit. This vomiting has continued till a week before the date of his admission. The matter ejected was sometimes profuse, usually about a quart or more, yellowish in colour till a week before admission, when it became brown —"like tea in colour, but rather thin." He vomited six times after admission, at intervals of two to four days. The character of the vomited matter was generally that of a ropey clear mucus with clear fluid; its reaction varied from alkaline to neutral and faintly acid. There was never any brown colour or "coffee ground vomit" observed, and the quantity varied from 1 pint to 1½ pint. No blood was observed. At times he would put up mouthfuls of fluid at intervals of half an hour to four hours. The stomach was frequently washed out.

The pain used to come about half an hour after meals as an uneasiness, growing worse until it became actual pain. The

Digitized by Google

interval between the ingestion of food and the pain gradually diminished, and he has pain without food, and this, when present, is always aggravated by food. So far as could be ascertained, this pain was attributed to violent muscular contractions.

Diarrhœa began six weeks before admission, and continued five weeks at the rate of five to six motions a day. The amount of fæces was considerable at each motion, never black, and always free from blood. No griping or pressing pain was experienced, and the bowels had previously been quite regular. After admission the bowels were constipated for the most part. For some time prior to admission he did not dare to take flesh food, not even eggs. He lost 14 lb. in weight during the last two months, but kept at his work till a week ago.

Condition on Admission.—The patient is greatly emaciated; his temperature, 97° F.; tongue clean; arcus senilis well marked. There is great flaccidity of the abdominal wall.

Gastric Condition.—There is much distension, the lower border of the stomach being at the level of the umbilicus, and stretching from beneath the costal margin on one side to the other. Splashing of the contents is easily observed, also very constant and exaggerated peristaltic movements of the stomach wall—to eye and hand—from left to right at the rate of about 1½ in. per second. The contractions rapidly follow each other, the longest interval observed being about thirty seconds. At the height of contraction the resistance to the hand is very great, but during the interval it passes away completely. The abdominal muscles are very lax, and take no part whatever in the contraction. The stronger contractions are painful, and are accompanied by acid eructations.

No tumour is felt, but as part of the stomach is under the right costal margin, it is impossible to speak definitely of the condition of the pylorus.

On 18th May the stomach was washed out, and on the following day, while the stomach was empty, a distinct tumour was felt descending in front of the liver, almost in the middle line. It was freely movable, about the size of an egg, smoothly rounded, and slightly painful on pressure. It was not observed again. He complained of deep-seated pain on pressure just opposite the ninth costal cartilage. Gastric splashing is still great, but the contractions are not so severe. There is no alteration in the outline of the stomach. His temperature varied from 97° F. to 98·2° F.

The cardiac condition presents no murmurs, the arteries are

Digitized by Google

rigid and tortuous, and there is marked visible pulsation of the arteries of the neck. The quantity of urine varied from 20 to 60 oz.; specific gravity, 1016 to 1026; no albumen.

Treatment.—Diabetic diet, and latterly 10 grs. of salicylate of bismuth thrice daily.

The operation was anxiously desired by the patient whose condition made him quite miserable; and though his age, emaciation, weakness, and atheromatous vessels contra-indicated the radical operation, I consented to make an exploratory incision and, if practicable, remove the tumour.

On 30th May, 1897, he was put under chloroform by Dr. Gilchrist, and with the assistance of Drs. M'Gregor and Howat I opened the abdomen in the middle line, above the umbilicus.

The pylorus was easily found and drawn into the wound; the growth seemed quite circumscribed, and, as no enlarged glands were found, it was decided to excise the tumour. One assistant grasped the duodenum with one hand well below the tumour, so as to prevent the escape of its contents, and in like manner with the other caught the stomach above. An incision was then made round the duodenum, about an inch from the tumour, so as to cut the vessels, which were at once ligatured; the gut was now cut through, and the cut ends carefully cleansed. The mesentery was next incised, and its vessels secured. Lastly, the gastric part of the growth was cut clear in a similar manner, and the cut ends washed. The next step in the operation was the suturing of the upper margin of the stomach wound by means of a continuous suture of fine catgut, involving only the serous and muscular layers and binding the serous surfaces together, till the opening was of the same size as that of the duodenum. The assistant holding the stomach and bowel now approximated the cut surfaces, while the mesentery was sutured, and the union of the gut to stomach accomplished by means of a similar suture. Three lengths of catgut were used, and knots were made every eight or ten stitches as a safeguard. After a minute inspection of the line of suture, the parts were washed in sterilised water and dropped into the abdomen. The abdominal wound was closed by two rows of stitches, the buried stitches being of catgut and those in the skin of silkworm-gut.

The operation lasted one hour and twenty minutes, being twenty minutes longer than in the previous case, the delay being due to the free bleeding and the difficulty of controlling it on account of the impaired vessels.

Digitized by Google

The patient took chloroform fairly well; there was no vomiting after the operation, but he suffered from shock; the temperature fell to 96·2° F., and pulse to 52, rising in four and and a half hours to 96·8° F. and 60 respectively. At 6 P.M. the bodily heat had risen to 98°, and his pulse was better at 72. With the exception of thirst, he made no cemplaint except of slight abdominal tenderness on pressure. The day after operation was marked by a temperature ranging between 99° and 100·2° F., and the pulse varied from 85 to 106, thereafter remaining steadily normal for seven days, when he developed signs of pneumonia, which caused his death six days later.

The wound was dressed on the eighth day after the operation, and was dry and practically whole.

Nutrition was administered solely by the rectum for the first four days, after which teaspoonful doses of beef juice, whisky and water, and milk were given. The diet was gradually increased, and after the pneumonia developed more liberty was taken in the matter of food, with the object of trying to support him in his feverish condition. Notwithstanding this, he made no complaint about his stomach, and said that the food caused him no pain.

The *post-mortem* report by Dr. Anderson of Dr. Workman's examination is extremely interesting, and is given *in extenso*:—

"I. *Examination of removed pylorus.*—A portion of stenosed pylorus, showing the entire gastro-duodenal junction, was examined after the operation, and Dr. Workman reports that the tumour is a colloid cancer, the cancerous tissue being well marked between the mucous and muscular layers, and also infiltrating the muscular coats. The tumour was accompanied by inflammatory round-celled growth, and in some of the sections the latter alone was evident.

"II. *Post-mortem examination performed by Dr. Workman.*—The stomach was considerably distended with gas and semi-fluid food. The duodenum is also considerably distended with fluid food, and, on examining, a pouch-like dilatation extends behind the pancreas, increasing the dimensions of its cavity. The union between the stomach and duodenum is very good, the two being securely sutured together. The transverse colon is adherent to the wound connecting the stomach and duodenum, and is bound down by adhesion and contraction of the omentum. In front of the transverse colon where it is bound down, a small pouch is observed, formed by its dilated wall and about the size of a walnut. The colon

Digitized by Google

from this point to the cæcum is distended with gas, while beyond this point to the sigmoid flexure it appears collapsed; the sigmoid flexure and rectum contain semi-solid fæces to about 4 oz. The small bowel contains about 8 oz. of fluid food and bile. Liver healthy; no evidence of secondary tumour. The lungs, in addition to an old calcareous deposit and fibrous adhesions, show a pneumonia of recent date. The posterior parts of both lobes are in a state of red hepatisation passing into the grey stage. Other organs fairly healthy. Patient is very emaciated. Small cartilaginous or bony tumours on the ribs.

"*Microscopic examination.*—Sections of the abdominal wound show a slight indentation at the position of the incision; beneath this the tissues of the abdominal wall are infiltrated with altered blood. The peritoneal surface also shows a slight indentation, which is lined by a mass of leucocytes forming an area of inflammatory new growth; otherwise the wound is perfectly healed. The sutures are readily seen cut across in the section, and are evidently becoming absorbed by infiltration of leucocytes.

"*Gastro-duodenal adhesion.*—Sections show the mucous membrane of the stomach is chiefly cut obliquely, as evidenced by the glandular appearance of the tubules, which are cut across; the mucous membrane of the duodenum is cut more vertically, and it appears much thinner than that of the stomach. Just at the point where those two join, the muscular wall comes to the surface. The line of junction of stomach and duodenum in the section appears very irregular, and in its neighbourhood there is considerable leucocyte infiltration. The adhesion has evidently been very intimate and complete. The muscular tissue in the vicinity is already apparently undergoing gradual atrophy. Very slight hæmorrhage has occurred into the tissues. The sutures may be seen in the sections as coiled-up hyaline fibres infiltrated with leucocytes, and in their neighbourhood numerous giant cells are found (phagocytes?). No evidence of cancer can be demonstrated in the neighbourhood of the wound. A small ulcer of the stomach wall, about 2 ins. removed from the wound, is examined by sections of its edges. The sections show mucous membrane running up to the ulcer, and then somewhat folded over; on careful examination there seems to be some extension of the epithelium among the muscle bundles of the deeper structures, which leads to the suspicion that the ulcer has been due to a secondary deposit of the cancer.

Digitized by Google

"Portions of lung examined from different areas show most pronounced lobar pneumonia, with, in parts, considerable fibrinous deposit in the alveoli, but for the most part the condition has gone on to the stage of grey hepatisation. Slight exostosis of several ribs observed."

The above report shows clearly that the continuous suture is safe, and that the resulting union was most satisfactory. The distension of the proximal end of the colon and the collapsed condition of the parts distal to the omental adhesion seem to point to obstruction of the colon, but this view is contradicted by the fact that the bowels had moved nine times after the operation, that there were no subjective signs of obstruction, and that the lower bowel contained fæces, though it is quite possible that the contraction of the adhesion was taking place shortly before death.

Apart from that point, which might occur in any abdominal operation, the result of the pylorectomy was of itself very satisfactory, the fatal result being clearly due to pneumonia.

The *post-mortem* examination confirms my belief in the efficacy of the mode of suture, and as that is the speediest method known to me, I have the greater confidence in employing it in those cases where shock is proportionate to the duration of the operation.

The absence of evidence of bruising of the stomach or bowel favours the use of an assistant's hands rather than clamps, and the ease of approximating the cut ends is an additional argument in favour of this view.

Since the publication of my last article, Dr. Alexis Thomson, of Edinburgh, has had a successful case where he used Murphy's button. The patient did well, and passed the button thirteen months later.

In the *British Medical Journal* for 4th December, J. R. Jessop, F.R.C.P., reports a case where he performed the radical operation on 11th May, 1896. He used an elastic tourniquet and the continuous suture. The large wound of the stomach was closed from below, so that the duodenum was attached to the upper end of the stomach wound. Two rows of continuous suture were employed, one for the mucous and the other for the serous surface. The operation lasted an hour and forty minutes. The patient remained well for a year, and then had to undergo a second operation thirteen months after the first. There was no return of the disease but an adhesion of duodenal wound to liver, which was released. The patient died two days later.

Digitized by Google

In conclusion, I may state that the impression left in my mind after the experience I have had in these two cases, and after careful consideration of the successful and unsuccessful cases reported, is that pylorectomy is indicated in all cases where an early diagnosis has been made. A considerable number of the cases recorded show that great emaciation, well-marked gastric symptoms, and a large pyloric tumour may exist without secondary deposits, and surgeons should therefore impress physicians with the absolute necessity of at least early exploratory laparotomy in suspicious cases.

Mr. A. E. Maylard said that Dr. Adams was to be congratulated on his success. Pneumonia was a common cause of death after operations on the stomach. He was not quite inclined to endorse all the statements with regard to operative procedure. He did not think that rapidity of operation was so absolutely of the first importance. Shock might be as severe after an operation of one hour's duration as after one of four. The condition of the patient before operation was of much greater importance in determining the severity of the shock. Cases should therefore be got in as early a stage of the disease as possible. The danger of rapid operation was that one might not be sufficiently careful in stitching; many cases died of leakage. The method of suture must depend upon the condition found at the operation. A small tumour might give rise to extensive secondary formations, a large one to none at all.

Dr. J. H. Nicoll also congratulated Dr. Adams. The only case in which he had operated died on the fifth day. No *post-mortem* was permitted. He endorsed Mr. Maylard's remarks on the subject of speed. The stomach was one of the territories of the abdomen in which speed in operating was not so important as care in stitching, &c.

Dr. Middleton had seen many cases of pyloric cancer, and for the last ten years had been in the habit of consulting surgeons with regard to them. In not one of his cases had they yet operated, whether in hospital or private practice. The physician was not always to blame, as malignant disease, before the appearance of tumour, was frequently difficult of diagnosis. He did not think it right to bring in a surgeon unless he were prepared to press the operation. Would Dr. Adams say that a surgeon should be called at the earliest suspicion, and would he be prepared to operate at such a time?

Dr. Adams, in reply, said that though he was in favour of rapidity, surgeons were quite entitled to hold the opposite view.

Digitized by Google

He had no doubt that exploratory incision should be done more frequently. He had seldom seen a patient the worse of it, and thought that it should be done on suspicion.

III.—MULTIPLE SARCOMA.

BY DR. A. N. M'GREGOR.

Dr. M'Gregor read a paper on multiple sarcoma, illustrated by photographs. He read the histories of two cases which he had seen in private practice and in hospital, where the chief symptoms were the occurrence of successive crops of sarcoma, progressive emaciation, and anæmia. He laid particular stress on the distribution of these growths, and held that they could not be secondary growths from a primary lesion infecting the blood stream, for they were limited to the trunk, the limbs, head, and chest being unaffected. The rapid appearance of the growths was demonstrated, forty-five having appeared in forty-nine days in one case. He noted also that in some cases reported, where *post-mortem* examinations had been made, no primary tumour was found.

Particular importance was attached to the differential diagnosis in the early stages from glandular enlargements of tubercular and syphilitic origin, as also to the rapidity of growth in these cases, the average life of the patient being three months after the appearance of the first tumour.

Mr. A. E. Maylard asked if pigment had been found, and was told that it was found in the second case. He said that the existence of pigment suggested melanotic sarcoma, and asked if the rectum had been examined.

Dr. Adamson could not see how it was possible to establish a clear differentiation between such cases and those arising by infection from a primary source of growth. He doubted if there were a disease that could be called multiple sarcoma without a primary focus. He believed that dissemination throughout the body took place by the arterial circulation after the formation of a focus in the lungs.

Dr. M'Gregor, in reply, said that the rectum was not examined in either case. The distribution of the tumours was a fairly sufficient indication that they had not been disseminated by the blood stream, as in his cases only the skin of the trunk was affected, and not the head or arms. The nodules in the lung in Oliver's case were not said to be sarcomata, but were possibly due to miner's anthracosis.

Digitized by Google

IV.—ACUTE TUBERCULOUS CHOROIDITIS FOLLOWING OPERATION FOR TUBERCULOUS LESIONS IN A LIMB.

BY DR. G. H. EDINGTON.

Dr. Edington narrated the particulars of the case of a boy, aged 3 years, in whom operation for tuberculous lesions in a limb had been followed by acute tuberculous choroiditis. Evidences of tuberculosis had appeared after an attack of measles. These comprised affection of left knee- and elbow-joints, and enlargement of lower end of left humerus, whilst ulceration was present on palm of left hand, and the cubital gland was enlarged and softened. The palmar ulcer was scraped, as also the cubital gland. Four days later the cornea of left eye was observed to be "steamy." The eye condition became rapidly worse, great enlargement of globe being a prominent feature. Dr. Ramsay enucleated after a diagnosis of tuberculous choroiditis, and this was confirmed on microscopic examination.

MEETING XIII.—22ND APRIL, 1898.

The President, DR. G. S. MIDDLETON, *in the Chair.*

I.—A CASE OF CONGENITAL ABSENCE OF THE LEFT RADIUS AND OF THE LEFT THUMB, MALFORMATION OF THE LEFT ULNA, SPINAL CURVATURE, AND COMPLETE DISPLACEMENT OF THE HEART TO THE RIGHT.

BY DR. MIDDLETON.

The subject of these deformities was a man, 38 years of age, who was admitted to the Royal Infirmary in March of the present year suffering from bronchitis, to which he had been subject for about eighteen months. Lividity of the face was very marked, but there was little dyspnœa and no orthopnœa. Under suitable treatment he rapidly improved, and was ultimately dismissed well.

He was a stunted man, his height being only 4 ft. 7½ in. and his weight 7 st. 2 lb.

He presented a well-marked spinal curvature involving the whole of the dorsal region, and associated with twisting of

Digitized by Google

the vertebræ on themselves, so that the left side of the chest was compressed from before backwards and flattened, while the right side of the chest was rounded and expanded (Fig. 1, p. 157).[1]

FIG. 1.

Apparently dependent on this deformity there was complete displacement of the heart to the right side. The illustration (Fig. 2, p. 158)[1] shows the outline of the cardiac dulness as demarcated by a light percussion stroke, and the cross, in the

[1] From photograph by Dr. James Dunlop.

Digitized by Google

third right intercostal space above and within the nipple line, indicates the position of greatest impulse—an impulse so well defined that it might almost have been called an apex-beat. The cardiac sounds were best heard in that situation, and

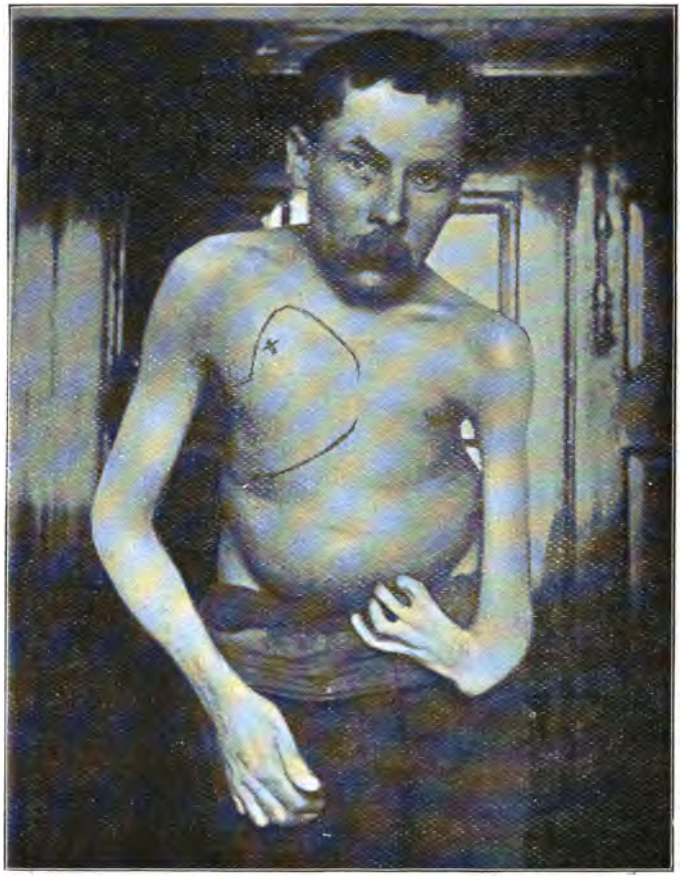

FIG. 2.

with the first there was audible a blowing systolic murmur, which was also heard along the right border of the sternum. This murmur ultimately disappeared, and the sounds over the centre of greatest impulse became accentuated. Over the whole of the left side, in front and behind, the percussion note

Digitized by Google

was clear, and the respiratory murmur was well heard. There was no history of pleural or other disease that could have caused the cardiac displacement, and the conclusion was arrived at that it was due to the great deformity of the

FIG. 3.

thorax. There was, of course, no history of the heart having become displaced.

The left arm and hand presented the peculiar appearance shown in the illustrations. There was great atrophy of all the muscles about the left shoulder, &c., and shortening of the

Digitized by Google

arm and hand. For example, at the insertion of the deltoids the measurements were—right, 9 in.; left, 6 in.; length of right humerus, 12½ in.; of left, 11 in.; of right hand, 7 in.; of left, 5½ in. The fore-arm was even more shortened, the greatest length (external surface) being barely 6 inches. The thumb was entirely absent, and no radius could be felt. The fingers presented a somewhat claw-like appearance.

Notwithstanding these defects he made free use of his hand. He could lift things easily, and had considerable power of flexion at the wrist and also at the elbow. In the ward, when convalescent, he proved a very useful, handy man.

The skiagram[1] (Fig. 3, p. 159), shows very clearly that the radius and the thumb are entirely absent; while the ulna, growing without the opposition of the radius by its side, has become markedly curved and shortened. It is impossible to be sure of the condition of the bones of the carpus, but no definite abnormality is seen.

Cases of this kind are not common, though I believe they are hardly so rare as cases of congenital absence of the ulna. Sometimes they are bilateral, when their explanation is probably to be sought for in some constitutional cause affecting the blastema—*e.g.*, syphilitic inflammation. The facts that this man presented none of the usual features of congenital syphilis, and that the lesion affected only one arm, seem to warrant the inference that in his case the blastema of the thumb and of the radius had been destroyed by some embryonic thickening of a simple inflammatory nature.

II.—TWO CASES OF RECOVERY FROM SYMPTOMS OF CEREBRAL TUMOUR.

By DR. T. K. MONRO.

Two years ago I brought under the notice of this Society (see the Society's *Transactions*, 1897, vol. i, pp. 132-139) two cases of recovery from intracranial tumour. In one instance a boy suffered from characteristic symptoms for some months before and after his seventh birthday. The diagnosis was tumour of the cerebellum, perhaps tubercular. About three months ago this boy was operated upon for a painless abscess over the right hip, but the movement of the joint appears to be quite unrestricted. There is still absence of both knee-jerks, but there has been no return of head symptoms, and the general condition has remained good.

[1] Taken by Dr Faulds.

Digitized by Google

The other case was that of a man in whom a large myxoma of the left lobe of the cerebellum ceased to grow and ceased to cause symptoms, and who, after forty-five years of good health, succumbed to a cancer of the pylorus.

Two other patients who have recovered are here to-night.

CASE I.—Summary: *Illness commencing in eighth year of life, and characterised by headache, vomiting, constipation, left hemiplegia, loss of vision, and a prolonged convulsive attack—Recovery after some months except from blindness and slight hemiparesis—Liability since puberty to occasional epileptic seizures.*

Maggie B., who was aged 17 last January, consulted me at the Royal Infirmary Dispensary in March, 1897, on account of a defect of power in the left thumb and forefinger interfering with her progress in learning to knit with the machine in the Blind Asylum. Most of the following facts were ascertained about two months ago (21st February, 1898). She took ill when aged about 7½ years, and the severe symptoms continued for three or four months. Except during the fit, which will be described, she did not lose consciousness, and she was never absolutely unable to walk. She first was ill with her "stomach"—that is, she was confined to bed for some days with headache and sickness—and when this ceased she took a fit which lasted from 8·30 A.M. till 1·30 P.M., and is said to have involved especially the left arm and leg. The fit was followed by gradual loss of power in the left side, gradual loss of the eyesight, constipation, vomiting, and pain in either head or eyes. No second convulsion took place for six years or more. Some three or four months after the fit a swelling on the top of the head opened spontaneously and discharged fluid, like "matter." After this broke she was able to get out of bed; till it broke, the arm and leg were constantly stiff, and the fingers constantly moving. Menstruation began after 13, and is regular. The second fit was at about 14, and she has been subject to such attacks since, but though she gets no medicine for them, they are diminishing in frequency and severity, one recent interval having been three months. They occur sometimes before and sometimes after menstruation, but never during a period, and only when she is in bed. There is an aura in the form of a sense of choking, but patient has no time to help herself. The eyes tend to deviate upwards and to the left, the face may be drawn very slightly to the left; the left arm and leg especially may be flexed and convulsed, and at the commencement the left forefinger is

Digitized by Google

sometimes rigidly extended. Headache sometimes follows recovery of consciousness. Patient is still rather costive, and if this is not attended to, the fits are more severe.

Patient is now free from pain and tenderness in the head, and from vomiting. She has an excellent appetite, and is putting on flesh. Hearing, smell, and taste are good. There is slight external rotation of the left eye. The eyes can be deviated conjugately to either side. When patient is told to look at her nose, she does this with her right eye, the left rotating outwards; even when the right eye is covered she cannot look towards the nose with the left. The pupils are both large, the left responding very slightly, and the right scarcely, if at all, to strong light. Patient says she has always been able to distinguish light from darkness. Both optic discs are atrophied, the margins being slightly altered and the vessels narrowed. When she shows her teeth, it can be seen that the left side of the face is a very little weaker than the right. The left hand is smaller than the right, but can grip strongly and is free from athetoid movements. The tip of the left thumb cannot be opposed to the other left finger-tips. There is no evidence that any form of sensation has been impaired. It is only after a long walk that the left leg begins to drag. There is no ataxy on standing. The right knee-jerk is normal or slightly reduced; the left is exaggerated. There is no ankle clonus.

The parents and the remaining five children are all healthy, except that the father has suffered from sciatica and some other slight rheumatic trouble.

Patient (the eldest child) was healthy in the early months of life, but after vaccination and teething was "difficult to bring up" (had vomiting and diarrhœa, but no cough). She had measles at 2 years and influenza at 11, but never had whooping-cough or scarlet fever.

The wide distribution and slight degree of the hemiplegia, together with the fact that though the weakness was of gradual onset there was only one convulsive attack during a considerable number of years, point to a lesion at a distance from the central area of the cortex, and this view is supported by the early occurrence of severe optic neuritis. The lesion may have been in the neighbourhood of the right internal capsule, and the paresis of the left third nerve might then be accounted for by the distant pressure of the growth or by a localised meningitis, or by a small independent lesion in the left crus or corpora quadrigemina.

Digitized by Google

The antecedent delicacy of the child, her age, and the very circumstance of recovery give a certain presumption in favour of the growth being tubercular.

Seeing that so many cases of ordinary idiopathic epilepsy commence at puberty, it is the less surprising that this girl with her damaged cerebrum should on the advent of that epoch become the subject of epileptic attacks, and it is also quite natural that the epileptic discharge should involve first or most that side of the brain whose nutrition was long ago impaired by the original organic lesion.

CASE II.—Summary: *Headache, vomiting, optic neuritis and defective knee-jerks—Recovery.*

Mary C., æt. 15¾, came to the Royal Infirmary Dispensary in March, 1897, complaining principally of headache. This had troubled her for seven months past, and affected all parts of the head, but was worst at the back. It was absent at times, and was sometimes slight, but at nights in particular it was so intense as to interfere with sleep and make her cry. Vomiting did not begin till a considerable time after the headache, and was very infrequent. Constipation was a feature of the illness. General weakness was admitted, but no local palsy. Patient could walk well, but on standing with feet together and eyes closed, tended to fall backwards and a little to the left. The left knee-jerk was almost completely abolished, and the right distinctly reduced. The pupils, which were somewhat large, were equal, and contracted to light. There was slight double ptosis. Patient was not aware of any dimness of vision, though she admitted some soreness about the eyes, but well-marked optic neuritis was found to be present on both sides. The urine was free from albumen and sugar, and the heart and lungs were healthy.

Patient is the youngest of five surviving children. Five others are dead, the causes of death including whooping-cough, small-pox, measles, and "decline" affecting the chest. The surviving children and the mother are mostly in good health. The father died some years ago of a throat affection. The treatment ordered was syrup of the phosphates with cod-liver oil, and phenacetin (10 grains) at night for the headache.

On 27th April, 1897, it was noted that patient had been free from headache and vomiting for two or three weeks. Constipation continued. Patient noticed several times daily that her sight would get dim for some ten minutes at a time. Visual acuteness was—in the right eye, $\frac{6}{24}$; in the left, $\frac{6}{18}$.

Digitized by Google

The neuritis, though not associated with hæmorrhages, and though now subsiding, was still very marked. Both knee-jerks were distinctly defective. The general condition was now pretty good.

Shortly after this note patient became worse again, and on 14th May it was noted that during the preceding fortnight headache usually wakened her about 4 A.M., and continued till early afternoon. Moreover, she vomited immediately after taking anything, even water. Pain affected the head generally, but was worst at the back, and extended below the occiput. There was no tenderness. Constipation was obstinate. The mother stated that the left ear had discharged from time to time since infancy, and that since the present illness began headache was not so severe when the ear was running. Vision in each eye was now $\frac{6}{18}$. Both knee-jerks still very defective. No ataxy, vertigo, or palsy. In the swollen optic disc of the left side one minute linear hæmorrhage was observable. Patient was ordered 10 grains of antipyrin at night.

The distressing symptoms speedily passed off, and the mother attributes great virtues to the powders obtained at the Dispensary. When patient was seen some weeks ago, it was found that she is in regular employment, and has long enjoyed good general health. So far as her own feelings go she has quite recovered, unless, perhaps, slight constipation be excepted. When her eyes are tested separately, she says that the sight of each is quite good. Nevertheless, ophthalmoscopic examination reveals early consecutive atrophy of the left disc, and to a less degree of the right. There is also slight ptosis. Patient is deaf in both ears, and the left ear discharges from time to time. The right knee-jerk is normal, and the left only slightly defective. Though patient will be 17 next June, she has never menstruated. Still, none of these presently existing abnormal conditions is such as to prevent her discharging the duties of life with as much ability, activity, and comfort as before the onset of her illness nearly two years ago.

The symptoms, negative and positive, point to a lesion of the cerebellum, either tumour or abscess. The ptosis may be due to pressure acting in the direction of the corpora quadrigemina. The diagnosis between abscess and tumour is not easy, for while the chronic ear disease is there to account for abscess, we are not sure about the duration of the discharge; at one time it was said it began in infancy, and on other occasions it was said to have begun about the same time as the severe illness.

Digitized by Google

The prolonged arrest of symptoms so severe as those from which this patient suffered is perhaps in favour of tumour, and from the family history and wretched surroundings of the patient we might imagine her to be a fit subject for tubercle. The greater impairment of the left knee-jerk and the fact that patient tended to reel backwards and to the left perhaps warrant a conjecture that the right side of the cerebellum is the principal seat of disease.

Dr. Alex. Robertson said that in the first case the diagnosis was undoubtedly correct, but the locality of the lesion was not so certain. There was one point not in favour of a lesion in the internal capsule—viz., the implication of the third nerve. He suggested that a tumour in the right side of the cerebellum, pressing rather far forward, might more fully account for the symptoms. If the pressure were long continued, it might affect the motor strands so much as to lead to incomplete repair. In the second case he doubted the cerebellar localisation. An abscess did not usually lie dormant. If the symptoms dated from the discharge, such a condition might give rise to implication of the petrous bone. A chronic inflammatory action extending inwards and backwards might thus affect the third nerve, without the necessity for assuming the existence either of tumour or of abscess.

Dr. Love asked if Dr. Monro's personal experience was that a tumour of the right side of the cerebellum led to diminution of the left knee-jerk. As far as work on animals had shown, the cerebellar relation was uncrossed, and, as a rule, the knee-jerks were exaggerated in cases of cerebellar tumour. Had Dr. Monro actually met with tubercular tumours in the internal capsule, as the situation was very unusual?

Dr. Monro, in reply, said that anatomically the cerebellar relation was uncrossed, and, as Gowers had said, the clinical facts were therefore puzzling, for the knee-jerk was affected on the opposite side. With regard to the first case, he had decided against a lesion in the right side of the cerebellum because a tumour there would cause palsy of the sixth nerve at least as soon as of the third. It was simpler to suppose that there was a slight meningitis accompanying a tubercular lesion. It was difficult to consider the second case as due to the antecedent ear disease, for the knee-jerks were absent. He had said in his paper that the tubercular tumour was not in, but in the neighbourhood of, the capsule, where he thought they did not unfrequently occur.

Digitized by Google

III.—TWO CASES OF CHRONIC CARDIAC DISEASE TREATED BY THE SCHOTT METHOD.

BY DR. ALEX. ROBERTSON.

In too many cases where new modes of treating disease are introduced exaggerated statements are made regarding the curative, or at least beneficial, action of the alleged remedial measures. More especially where recovery or marked amelioration of symptoms follows their use hasty conclusion that the result should be attributed to their action is not infrequent, possibly quite ignoring other conditions which may have been important contributory factors. Disappointment has been so frequent when much vaunted "remedies" have been subjected to the test of unbiassed and sober examination that a very excusable scepticism has arisen in the minds of many, probably most, medical men regarding every new claimant for acceptance on its appearance. And yet there is a risk that the germ of truth and reality in some of these newer modes of treatment may be overlooked, and that our armamentarium for combating disease may be so much the poorer by its exclusion.

These remarks are applicable to what is known as the Schott or Nauheim mode of treating chronic diseases of the heart. Some years have now passed since attention was directed in this country to the apparent immediate and remarkable changes which occurred in hearts dilated and hypertrophied under this treatment. It was stated that directly after a saline or carbonic acid bath there was an appreciable, sometimes very marked, reduction in the dimensions of a dilated heart, and that a similar change followed resistive exercises, also recommended by the brothers Schott. It was not contended by the advocates of these measures that the reduction of area occupied by the heart after each bath or group of exercises was long maintained. On the contrary, it was freely conceded that there was soon a return, nearly but not quite, to the previous condition, but that after a course of baths and exercises extending over three or four weeks there was usually a gain more or less permanent. At the same time the feeling of relief and improvement which the patient experienced was oftentimes very striking. These were the statements, and support was lent to them by the observations at Nauheim of some trustworthy observers belonging to this country.

At the Carlisle meeting of the British Medical Association the Schott treatment was one of the subjects of discussion,

Digitized by Google

and quite recently at one of the London societies there was an interesting debate on its merits. Much difference of opinion was expressed; but, upon the whole, the impression of those who were most competent to judge by personal observation was favourable to its use in some conditions of cardiac disease.

About two years since I first tested the action of the baths and exercises in a severe case of mitral valvular disease, with general enlargement of the heart. The results upon the whole were negative; but looking back on the case now I feel satisfied that the morbid condition was too advanced to expect relief from that or any other mode of treatment. However, the feeling of disappointment produced by the result in this case indisposed me to try it further for a time. Still, on later reflection, I felt that it should not be hastily discarded, but was worthy of a careful trial. The two patients now brought before the Society seemed fair test cases. The valvular disease in both was well marked, and the consecutive changes in the heart were equally so.

CASE I.—D. M'L., age 18, tinsmith, was admitted into the Infirmary on 3rd February, 1898. The report in the ward journal, of which the following is a brief summary, bears that his heart trouble began when he was 14 years of age, and was of rheumatic origin. On admission there was orthopnœa, and he had an aspect of much distress. His extremities were a good deal swollen, and there had been blood in his sputum the day previously. There were loud murmurs indicative of mitral regurgitation and aortic obstruction. This diagram shows the extent of dulness in the cardiac region which was then present. Under ordinary medicinal treatment he improved rapidly; the report on the 14th February, eleven days after admission, was as follows:—"Greatly improved; sleeps well; appetite good; orthopnœa gone." He was allowed to move about the ward; but, though much relieved, he was easily distressed by slight exertion, and there was reason to fear that he might readily relapse. No doubt the area of cardiac dulness, as shown by the diagram on admission, when contrasted with the one at the commencement of the Schott treatment, showed some improvement after its use. But though the cavities of the heart were a little contracted, they were still probably unduly relaxed and dilatable.

It was at this stage of the patient's illness that the special baths and exercises which constitute the Schott treatment were begun. In all he had fourteen baths, six saline and

Digitized by Google

eight in which the special agent was carbonic acid gas. The former—the saline—were each prepared with 5 lb. of chloride

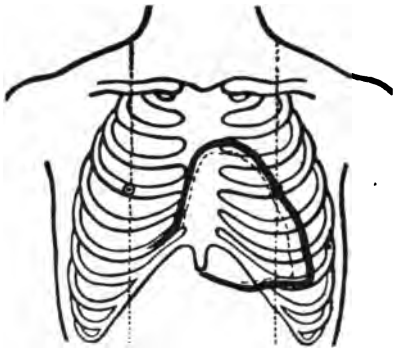

DIAGRAM 3. CASE I.—D. M'L.

Before second bath.	*After second bath.*
Parasternal line, 5¼ inches.	Parasternal line, 4¾ inches.
Transverse at nipple, 5½ inches.	Transverse at nipple, 5 inches.
Greatest transverse, 7⅛ inches.	Greatest transverse, 6⅛ inches.
Pulse, 108; respiration, 24.	Pulse, 120; respiration, 20.

of sodium and 8 oz. of chloride of calcium to 30 gallons of water. The temperature of the water was 92° F., and the



CASE I.—D. M'L. Before second bath.



CASE I.—D. M'L. After second bath.

duration of the immersion was eight minutes in the first bath and thirteen minutes in the sixth.

The carbonic acid baths were each of thirty minutes'

Digitized by Google

duration. There was a free development of the gas round the person of the patient. The temperature of the water was the same as in the other case.

The exercises were begun after the third saline bath, and have been continued till now every second or third day, when no bath was given. At the outset he only had them for a few minutes, and therefore they were only partial. Latterly he has had the whole set, which occupy about three-quarters of an hour.

The observations on the effects of the baths were made in some instances by myself; in others by Dr. J. W. Allan, dispensary physician; and in the remainder by Dr. A. C. Wilson, my late,

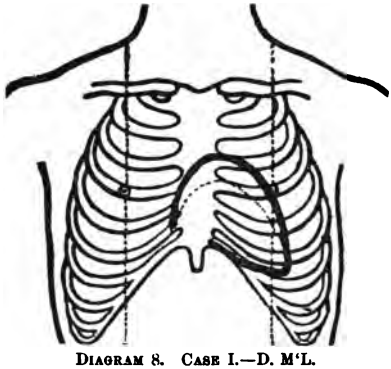

DIAGRAM 8. CASE I.—D. M'L.

Before seventh bath.	*After seventh bath.*
Parasternal line, 5 inches.	Parasternal line, 3½ inches.
Transverse at nipple, 4¾ inches.	Transverse at nipple, 3¾ inches.
Greatest transverse, 6 inches.	Greatest transverse, 6 inches.
Pulse, 104; respiration, 22.	Pulse, 104; respiration, 20.

and Dr. W. K. Russell, my present house physician—both competent observers. Each diagram showing the measurements before and after the bath is signed by the observer. Only Diagrams 3, 8, 9, and 15 (pp. 168, 169, 170, 171), are submitted, but they are fairly representative of the others. The dark outer line represents the area of the heart, as determined by percussion before, and the dotted inner one after, each bath.

Notes were made of the frequency of the pulse and respirations, and a sphygmogram was taken, before and after each bath. Upon the whole, with some slight exceptions, there was not much change in either the rate of the pulse or the respirations on each occasion. This rather surprised me, as in the cases

Digitized by Google

recorded by others, especially Dr. Bezley Thorne, there was a marked reduction in both. After the fifth bath the pulse

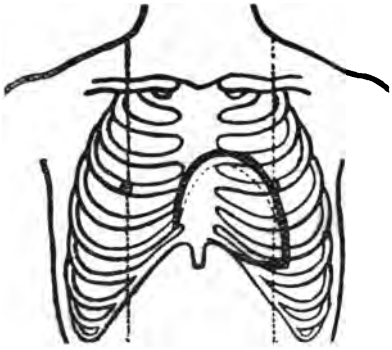

DIAGRAM 9. CASE I.—D. M'L.

Before eighth bath.	*After eighth bath.*
Parasternal line, 4⅝ inches.	Parasternal line, 4¼ inches.
Transverse at nipple, 4¾ inches.	Transverse at nipple, 4½ inches.
Greatest transverse, 6 inches.	Greatest transverse, 6 inches.
Pulse, 100; respiration, 18.	Pulse, 100; respiration, 18.

was 14 quicker, and the respirations 2 more than before it; and after the eleventh bath the pulse was 6 increased in

CASE I.—D. M'L. Before eighth bath.



CASE I.—D. M'L. After eighth bath.

frequency. However, at the close of the series of baths the respirations were 22 to 24, and the pulse 96, which contrasts favourably with 30 and 116 respectively before they were

Digitized by Google

begun. A similar remark falls to be made regarding the sphygmographic tracings. At the close they still indicate low tension, as they did at the commencement. The aortic notch is low and deep, and the dicrotic wave prominent in both cases. After the fifth and sixth baths there was a nearer approach to the normal.

Turning now to the cardiac measurements, it will be observed that there was some reduction after each bath. The observations, it should be mentioned, were made immediately before and in from five to ten minutes after the bath. The most marked diminution was to the right and upwards to the left; there was an apparent reduction in the dimensions of the

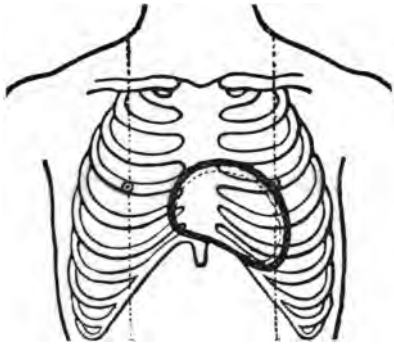

DIAGRAM 15. CASE I.—D. M'L.

Before fourteenth bath.	*After fourteenth bath.*
Parasternal line, 4¼ inches.	Parasternal line, 4 inches.
Transverse at nipple, 5⅛ inches.	Transverse at nipple, 5 inches.
Greatest transverse, 6¼ inches.	Greatest transverse, 6 inches.
Most obvious point of apex beat from midsternal line is 4⅝ inches.	Most obvious point of apex beat from midsternal line is 4¼ inches.
Pulse, 96; respiration, 24.	Pulse 96; respiration, 24.

right ventricle and auricle, and also in the left auricle. But there was a reversion to nearly, and in some cases quite, the same condition before the next one. Still, upon the whole, there has been a gain. Thus, the measurements before the first bath on 15th March, and before the last one on 21st April, were as follows:—

	15TH MARCH.	21ST APRIL.
Left parasternal line, . .	6¼ inches.	4¼ inches.
Transverse at nipple, . .	5¼ ,,	5⅛ ,,
Greatest transverse, . .	6¾ ,,	6¼ ,,

This is at once obvious on looking at the diagrams.

Digitized by Google

The patient's own statements are very decided as to the benefit he has derived from this treatment. In evidence, he says that he can now walk up and down the three long stairs between his ward in the Infirmary and the airing ground without fatigue, which he could not do before its commencement.

CASE II.—J. D., age 12, admitted to Infirmary, 20th January, 1898. He was a healthy boy till April, 1897, when he had an attack of rheumatism. This subsided, but two months afterwards he became an inmate of the Children's Hospital, where he was found to be suffering from disease of the heart.

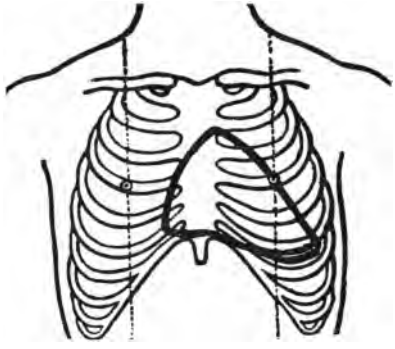

DIAGRAM 2. CASE II.—J. D.

Before beginning exercises.

Parasternal line, 5½ inches.
Transverse at nipple, 5 inches.
Greatest transverse, 7¼ inches.

Most obvious point of apex beat is 5½ inches from midsternum.
At centre of fifth rib dulness to right from midsternal line is 1¼ inch.

He improved, and kept pretty well till the end of December, when he got a fresh cold, and had a feeling of distress in the breast.

On admission he was somewhat cyanosed, and was easiest when sitting in bed. There was pulsation in the epigastrium and lower intercostal spaces to the left. Considerable bulging was evident in the præcordium. The area of the cardiac dulness, as shown by the diagram, was much increased. The apex beat was in the sixth interspace, 1½ inch outside the nipple line, and the impulse was of a heaving character. A blowing systolic murmur was heard at the aortic cartilage, down the spine, over the cranial bones, clearly over the head

Digitized by Google

of the humerus, and less so, but distinctly, at the elbow. A mitral systolic murmur was also present. There were some dry and moist râles of medium size in the chest.

Under medicinal treatment he improved, and the urgent symptoms passed away. He had, however, a relapse, and it was not till 21st March that it was thought advisable to begin the special exercises. These, as in the other case, were only partial at first, but in the course of a week he was able for the whole series at a time. Since then they have been continued daily.

Contrasting the diagram taken on admission, with that

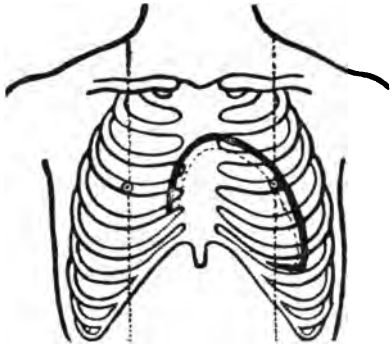

DIAGRAM 5. CASE II.—J. D.

Before.	*After.*
Parasternal line, $4\frac{1}{8}$ inches.	Parasternal line, $3\frac{3}{4}$ inches.
Transverse at nipple, $4\frac{5}{8}$ inches.	Transverse at nipple, 4 inches.
Greatest transverse, 6 inches.	Greatest transverse, $5\frac{3}{4}$ inches.
Apex beat to midsternum, $4\frac{5}{8}$ inches.	Apex to midsternum, $4\frac{1}{2}$ inches.
Dulness to right from midsternum, $1\frac{3}{8}$ inches.	Dulness to right from midsternum, 1 inch.

Between times of percussion, exercises given for seventeen minutes.

at the commencement of the resistive exercises, it will be seen that under ordinary treatment there was a reduction in the area of cardiac dulness. This was chiefly in the region of the auricles. Again, comparing Diagram 2 (p. 172) with Diagram 7 (p. 174), taken yesterday, both figures and measurements show a marked contraction in the cardiac area. Further, Diagrams 5 and 7 (pp. 173, 174) show, as in the case of the baths, a reduction of the dull area after each set of exercises. This, for the most part, as in that case also, was only of a temporary kind, but the recession does not seem to have been complete in many cases, as is indicated by the reduced area of dulness at the close of the treatment.

Digitized by Google

The boy's own feeling of improvement is in full accordance with these observations.

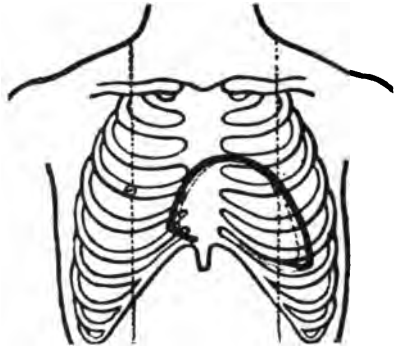

DIAGRAM 7. CASE II.—J. D.

Before.	*After.*
Parasternal line, 4 inches.	Parasternal line, 4 inches.
Transverse at nipple, 4½ inches.	Transverse at nipple, 4 inches.
Greatest transverse, 6½ inches.	Greatest transverse, 6 inches.
Most obvious point of apex beat from midsternal line is 5½ inches.	Most obvious point of apex beat from midsternal is 5¼ inches.
Dulness to right from midsternum, 1¼ inches.	Dulness to right from midsternum, 1¼ inches.

While not seeking to lay much stress on two cases, I may remark that the general impression left on my mind is

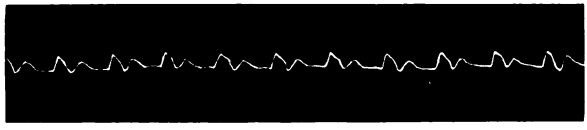

CASE II.—J. D. Before exercises.

CASE II.—J. D. At close of treatment.

favourable to this mode of treatment. It would be observed that it was only after the more urgent symptoms had been

Digitized by Google

removed under measures of an ordinary kind that recourse was had to these special measures. Indeed, the condition of both patients on admission was much too dangerous to think of other than well-established lines of practice. It is to be feared that harm would result in many such cases if either baths or exercises were used when the more grave symptoms of cardiac disease are present Probably, however, substantial benefit may be derived from either or both of these measures if employed at the stage when they were begun in the two patients shown to the Society.

Dr. Adamson asked if the patients were kept in bed all the time, and was told that they were not.

Dr. Middleton did not think the results indicated in Dr. Robertson's paper better than those attainable by ordinary methods. He had seen a cardiac dulness measuring 9 inches in the transverse diameter reduced in less than a week to 4 inches simply by rest in bed and the hypodermic injection of strychnine. He had not been favourably impressed by anything he had seen in Glasgow of the Schott treatment.

Dr. Jack laid stress on the necessity of care, particularly in the regulation of the exercises.

Dr. Robertson replied that in both his cases ordinary treatment was employed until it had ceased to produce improvement, and that further improvement had occurred on the institution of the Schott treatment. He thought this might be true of many cases. He agreed that careful regulation of the baths and exercises was necessary. In his cases the exercises were at first used only for a short time, and their duration was gradually increased.

IV.—NOTES ON THE CASE OF A GIRL SUFFERING FROM A CHRONIC PULMONARY CONDITION, IN WHOM MARKED CYANOSIS WAS PRESENT.

BY DR. R. B. NESS.

Dr. Ness read notes on the case of a girl of 17 suffering from a chronic pulmonary condition, in whom marked cyanosis was present, involving the face and the mucous membrane of the mouth and eyes. The fingers and toes were bulbous. There was no evidence of congenital malformation of the heart or of organic cardiac lesion. There was a well-marked spinal curvature.

Digitized by Google

Dr. T. K. Monro asked whether the obstruction was in the pulmonary capillaries, or was due to contraction or compression of one of the large pulmonary arteries.

Dr. Ness replied that the obstruction was in the tissue of the lung, and was due in part to a chronic inflammatory condition, and partly to the marked deformity of the thorax and spine.

MEETING XIV.—6TH MAY, 1898.

The President, DR. G. S. MIDDLETON, *in the Chair.*

I.—APHASIA WITH ALMOST COMPLETE LETTER-BLINDNESS AND ONLY PARTIAL WORD-BLINDNESS, AND WITHOUT HEMIANOPSIA.

BY DR. JOHN LOVE.

Dr. John Love showed a case of aphasia in which there was almost complete letter-blindness (*cécité littérale*), with only partial word-blindness (*cécité verbale*), and without hemianopsia, of which the following is an abstract:—

Dr. Love said that what was meant by the term "letter-blindness" was that with normal or unimpaired vision and intelligence there was an inability to recognise or interpret the signs known as the alphabet, although previously well known to the individual. The memory of "letters" had been obliterated, they were without meaning for him, while all other forms of visual memory were perfect—memories of "form," "colour," "place," "words," "algebraic signs," "numbers" and "musical signs." Dr. Love went on to remind his hearers that the "visual memory centre" for right-handed persons was assumed with much probability to include the angular gyrus and supra-marginal convolution of the left side, but this "centre" was in all probability a highly complex one, corresponding to the various modes of visual memory which, as is well-known, have a functional independence, any one of which may be lost without the others, as in the cases now to be presented, and as many other observations show; surely, then, it might fairly be assumed that with such a degree of functional independence there is also a somatic or anatomical independence

Digitized by Google

of these cortical "centres." Dr. Love, however, did not intend to discuss this aspect of the problem further. The case had been brought forward as one of great interest and considerable rarity although not unique; a search, by no means exhaustive, had discovered observations of a like nature by Broca, Charcot, Morgan, Bramwell, and M'Vicar. Briefly, the facts of the case were as follows:—

The patient, a young man of about 20 to 21 years of age, a railway clerk, in the midst of apparent robust health, became suddenly ill on 14th November, 1897, and was seen by Dr. Love on 5th December, he having become hemiplegic on the right side two days before; he was then very stupid and drowsy and apparently aphasic. The case was looked upon as one of epidemic cerebro-spinal meningitis. He gradually emerged from this condition of stupor, and there was some improvement in the paralytic symptoms and in the aphasic conditions. By the middle of March he was able to be removed from his home in the country to the Western Infirmary under the care of Dr. Finlayson, to whom Dr. Love acknowledged his indebtedness for the opportunity of studying the case further, and of presenting it to the Society. The hemiplegia presented some unusual and interesting features, but these were passed over to allow of a fuller consideration of the aphasia. On admission the remarkable observation was made that while the patient was "blind" to all letters of the alphabet except "I," he was yet able to read, certainly not fluently, but still with considerable facility, especially for isolated words, even when very unfamiliar and polysyllabic in character. He was, however, unable to indicate a single named letter in the words he had just read, neither was he able to compose words with movable letters, nor to decompose them into their component letters; his difficulty was the same with capitals and small letters, Roman, Gothic, and Italics, script, and printed characters; figures he could read, at least as far as 9, and he could manipulate a simple arithmetical problem, but only Arabic figures; Roman numerals he failed to understand. There was no word-deafness, and intelligence was unimpaired. Olfactive and gustatory memories perfect. He was not agraphic, but his writing showed a certain degree of paragraphia. There was no amusia; he was familiar with the new notation of music, and while he was unable to give any one of the signs its *alphabetic* name, he was able to give it its *musical* name and to sound it. There was no hemianopsia; he was right-handed for all acts. He presented both

Digitized by Google

articulative and amnesic speech defects. He exhibited remarkable facility for reading "mirror writing." Now there is a remarkable improvement in the articulative and some improvement in the sensory defects; he reads fairly, and there has been some re-education of the memory for letters, but it is still most defective; he writes well with almost no trace of paragraphia. Letters by the patient were shown, and he read before the Society both from printed and written text, and he was tried with separate letters of words he had just read; his power of reading "mirror writing" was also shown.

Note.—The case will be followed and reported fully later.

Dr. Alex. Robertson said that it was not easy to understand how words could be read when letters could not, but it appeared to him that the impression of individual letters might, with some people, become less distinct as time went on, and that of words more distinct. Successive impressions might be made on the same group of cells. He would have been surprised had hemianopsia been present, as it did not usually occur in letter or word blindness. Such symptoms as were present in this case might be produced by a lesion about the region of the angular gyrus. Why, then, should hemianopsia occur?

Dr. Gunn said that a child acquired a knowledge of syllables and words long before letters were acquired.

Dr. Love replied that not much could be said as to the absence of hemianopsia, as cases of both kinds were on record. It might be produced by a lesion about the cuneus or by a subcortical lesion. His reason for mentioning it was to suggest that the lesion was cortical. The pathological condition was a meningo-encephalitis. Dr. Gunn's remark coincided with his views, and teaching in modern schools was based upon the principle involved. Brissot's explanation was that after a certain amount of education words became merely ideographic signs, and not phonetic. They became unities, and in fact formed pictures.

II.—A CASE IN WHICH EXCISION OF THE WRIST WAS PERFORMED FOR TUBERCULOUS DISEASE.

By DR. EDINGTON.

The case is that of a man, aged 43, a worker in a pottery. He came to the Central Dispensary on 1st September, 1897, with tuberculous disease of the left wrist. There was fulness

Digitized by Google

all over the dorsum of the hand, and two discharging sinuses were present here in the space between the first and second metacarpal bones at their bases. On introducing a probe it passed upwards to the wrist and downwards to the base of the second metacarpal bone. There was flattening of the palm, but no evidence of disease in the tendon-sheaths. Pronation and supination were free, but all movements at the wrist were restricted. Cicatrices were present at the lower end of the ulna, and in front in the middle line above the flexion-furrow of the wrist, in which latter situation also was a patch of scrofuloderma. In addition, there was a small superficial tuberculous abscess at the lower angle of the cubital space. There was atrophy of the muscles of the limb. He suffered from an occasional cough, and was round-shouldered, which he attributed to working over a lathe in the pottery. Examination of the lungs was negative in result.

He stated that his illness began about two years previously, when a small swelling appeared at the lower end of the ulna on its dorsal aspect. He continued at his work for about nine months, when the swelling burst and began to discharge. He was treated in one of the infirmaries, where, he says, the swelling was opened up and some bone removed. There was also something done at the radial side of the carpus. Six weeks later an opening, which healed and broke again, formed on the flexor aspect. For fifteen months before coming to the Central Dispensary he had been unable to work on account of the condition of the parts.

On the 11th September, 1897, I performed excision of the carpal bones, at the Dispensary, by Lister's ulnar and radial incisions, the latter being made to include the mouths of the sinuses. The carpal bones were removed with the exception of the pisiform and the hook of the unciform. The intercarpal joints contained a turbid fluid, and the articular surfaces of the bones were more or less eroded by tuberculous granulation tissue. The proximal half of the second metacarpal was hollowed out by caries, and was removed by the bone-pliers. The bases of the third, fourth, and fifth metacarpals were partially removed, but the first metacarpal was left intact. On the inner surface of the ligaments there was much tuberculous granulation tissue, and this was removed as completely as possible. The lower end of the ulna, from which the styloid process was absent, was removed, as also a slice from the lower end of the radius, and the inferior radio-ulnar articulation was ablated. There were no signs of active disease in either of the fore-arm bones, or in the radio-carpal synovial cavity.

Digitized by Google

The cavity left by the operation was stuffed with iodoformised gauze, and the incisions were loosely stitched.

The scrofulodermatous patch above the front of the wrist was scraped, and the abscess at the cubital space was similarly dealt with.

The parts were dressed with cyanide gauze and wood-wool tissue, and an anterior splint of junk with a large pad for the palm was applied.

As might have been expected from the presence of the sinuses, there was some suppuration after the operation, but the patient was of the opinion that this was due partly to the fact that *within eight days* after the operation he took part in a matrimonial scuffle occurring among the other occupants of the stair. Notwithstanding the foregoing, the parts healed rapidly; the splint was left off in the course of a month, and in six weeks all dressings were dispensed with. On two subsequent occasions passive movement of the fingers was performed under chloroform. He wore for some time a wristlet of poroplastique, but, finding it irksome, discontinued it.

He has been back at his work now (6th May) for the last two months, and suffers very little inconvenience. He carries articles to the lathe, and uses the hand in the supine position to support them. Lateral movements of the wrist are practically absent, but flexion and extension, each to the extent of 45°, can be performed. There is slight displacement of the hand towards the ulnar side, and some limitation of flexion of the fingers. The index is shortened by about half an inch. The movements of the thumb are normal, as also pronation and supination of the fore-arm.

Remarks.—I am inclined to view the carpal condition in this case as secondary to disease of the second metacarpal bone. This conclusion is only natural when one takes into account the anatomical fact of the common synovial cavity between metacarpus and carpus. It is true that we have a history of the lower end of the ulna having been diseased early in the case, but at the operation no active mischief was found in this bone, nor was the radio-carpal joint affected. On the other hand, the base of the metacarpal bone was destroyed by active disease, thus opening the intercarpal articulations to infection.

The cicatricial condition of the parts around the sinuses prevented one identifying the tendons of the radial carpal extensors and of the long extensor of the thumb. The last

Digitized by Google

was evidently not damaged by the operation, while the former obtained attachment probably to the periosteum of the metacarpal bones. This is likely, so far as the extensor longior is concerned, from the fact that a skiagraph by Dr. Mackintosh, of the Western Infirmary, showed periosteal restoration of the second metacarpal. This fact would also account for the but slight degree of shortening of the index finger mentioned above. The slight degree of ulnar flexion, as a result of the operation, may, I think, be attributed to the attachments of the flexor and extensor carpi ulnaris tendons having been left intact. The absence of signs of tuberculosis in the lungs afforded grounds for a favourable prognosis.

III.—SPECIMENS.

By DR. T. K. DALZIEL.

1. Specimens of urinary calculi—(*a*) From the middle of the ureter, history of two years' duration, removed by laparotomy and utero-lithotomy; (*b*) in the upper end of the ureter, history of twenty-seven years' duration, hydronephrosis, suppuration, nephrectomy by laparotomy; (*c*) from the pelvis of the kidney, removed by nephro-lithotomy from an extremely stout patient.

2. A case of actinomycosis of the cervical sympathetic glands, of seven months' duration, treated by operation.

3. Papilloma of the ovary. The capsule had ruptured, and general peritoneal infection had occurred. The patient had been operated upon six years before for a similar condition of the other ovary, and had completely recovered. After each operation the secondary peritoneal papillomata had disappeared, and there had been no recurrence of the ascites.

4. A large congenital tumour of the neck from an infant 3 weeks old.

5. A specimen of carcinoma of the parotid gland.

Dr. R. M. Buchanan said, with regard to Specimen 4, that such a condition was, in his experience, very rare. He had seen only one other tumour of the same nature. The specimen had precisely the same macroscopic characters as an odontoma, but, histologically, two kinds of epithelial elements were present.

Dr. Knox, referring to the case of actinomycosis, said that two or three years ago he had shown the first case of the kind

Digitized by Google

recognised in Glasgow. The disease was only to be fully recognised by the aid of the microscope. In the speaker's case it affected the jaw, and the patient had died from infection of the bronchial tubes, in spite of scraping and of treatment by iodide of potassium, to which many successes had been ascribed. A combination of iodine and the iodide was also largely given, but removal was the only radical cure. It was impossible to give a hopeful prognosis while any actinomycotic tissue remained.

Dr. Dalziel replied that the patient, although not yet cured, was certainly enormously better. The past improvement was due to his excellent physical constitution.

Digitized by Google

TRANSACTIONS

OF THE

GLASGOW MEDICO-CHIRURGICAL SOCIETY.

—o—

SESSION 1898-99.

—o—

MEETING I.—7TH OCTOBER, 1898.

The President, DR. G. S. MIDDLETON, *in the Chair.*

DEMONSTRATION OF CASES.

BY DR. MIDDLETON.

I. *A case of disseminated sclerosis illustrating the difficulty of diagnosis between functional and organic paralysis.*

In March, 1897, a schoolgirl, 12 years of age, was admitted to my ward complaining of loss of power in her legs.

Five weeks before admission, when in her usual health, she was one day seized with vomiting, which persisted throughout the day. Next day she had prinkling feelings in her right arm, and she noticed some weakness in her arm and hand. Two days later similar sensations were felt in her right leg. On the following day, on getting out of bed for the first time since the vomiting occurred, she could not stand, the right leg doubling under her. The arm and leg were so powerless that she could lift neither of them off the bed. A fortnight later she had so far improved that she was able to move about without assistance, and she continued to do so for a week. Then a relapse occurred, affecting the left leg, and, later, the

Digitized by Google

right. When the legs became affected she had severe paroxysmal pains in the ankles, knees, and thighs. She had sometimes difficulty in micturition, but never incontinence; the bowels had been constipated. She had never had chorea or rheumatism.

The girl was greatly wasted, the atrophy affecting all the muscles of the arms and legs, and, to a less extent, those of the face. The left side of the face was slightly paralysed. The grasps of the hands were equally weak, and a fine tremor was visible in both hands when extended. No wrist-jerks were present.

She was quite unable to walk, and, indeed, had very little power of movement in the legs. The feet were kept in a position of talipes equinus, and at both ankles there was a flail-like movement. Very slight knee-jerks were obtained, and slight ankle clonus, but there was no plantar reflex. Sensation was quite normal in the upper limbs; but, in the lower, sensibility to tactile, painful, and thermic stimuli was slightly impaired. There was no tenderness on pressure of the limbs or on tapping the spine.

The pupils were somewhat dilated, and responded well to light and in accommodation. Perimetric tracings taken in April showed a considerable diminution in the field of vision, especially for white light.

The electric reactions of the nerves and muscles were noted by Dr. George Macintyre as follows:—

Electric sensation felt in right arm and leg distinctly at 8½ cm.

Right leg—Muscles supplied by the ext. pop. nerve contract at 8½ cm.

Tibialis anticus, .	faradic gives	C. at 6½ cm.
	galvanic ,,	K.C.C. and A.C.C. at 6 m.a.
Peroneus longus, .	faradic ,,	C. at 7 cm.
	galvanic ,,	A.C.C., no K.C.C. at 3 m.a. No opening contraction.
Soleus, . . .	faradic ,,	C. at 7¾ cm.
	galvanic ,,	K.C.C. and A.C.C. at 5 m.a.

Left leg—

Ext. pop. nerve, .	faradic ,,	C. at 7½ cm.
	galvanic ,,	no K.C.C., marked A.C.C. at 4 m.a.
Tibialis anticus, .	faradic ,,	C. at 7 cm.
	galvanic ,,	K.C.C. and A.C.C. at 6 m.a.
Soleus, . . .	faradic ,,	C. at 7½ cm.
	galvanic ,,	slight K.C.C., marked A.C.C. at 9 m.a.

Digitized by Google

The internal organs were normal, except that there was a loud, musical, ventricular systolic murmur at the base.

The left facial paralysis noted on admission disappeared in a few days, but paralysis of the right side took its place for several days.

Improvement took place almost from the time of her admission, so that within a fortnight she was walking without assistance. A fortnight later, while the general improvement was maintained, complete right facial paralysis recurred, and lasted for nearly a fortnight.

After a couple of months' residence she was dismissed greatly improved in all respects, although nutrition was by no means good, and she could not walk with freedom. Sensation was good all over.

The case was indexed as hysterical paralysis, a diagnosis made largely on account of the fleeting nature of the various paralytic phenomena.

The girl was readmitted on 19th July of the present year, having in the meantime continued fairly well, and always able to walk about and even to act as a message girl, till some five weeks before her return. The onset of the attack on this occasion was characterised by a shooting pain in the left temple, followed next day by severe vomiting for several hours. Immediately after the vomiting ceased she had a prinkling sensation in the left side of the face and mouth, lasting for three weeks. A week before those sensations passed off she had another attack of vomiting, followed by similar prinkling sensations in the right side of the face. A third attack of vomiting occurred on 3rd July, followed by prinkling sensations in both arms and legs, replaced in a week by loss of power in these. Since that time she had been unable to stand or sit.

On admission she was much emaciated and extremely weak. The pulse was 120, and soft. She was peculiarly inclined to talk, answering questions rather at random. The temperature was normal.

The paralytic phenomena were much as on her first admission, and need not be given in detail. Both arms and both legs were affected, the left side rather more so than the right. Sensation was slightly impaired, the knee-jerks were somewhat exaggerated, and there was a trace of ankle clonus, and also a slight plantar reflex.

The heart was as before.

The pupils were dilated, and reacted feebly to light and in

Digitized by Google

accommodation. There was no nystagmus, but the right eye did not converge properly.

On the evening of 21st July she fell into a collapsed state. She complained of a feeling of tightness across the foot of the sternum, and was restless and moaning. The face was deeply flushed, with the exception of well-defined white rings encircling the eyes and the mouth. The skin was covered with a clammy perspiration. There was involuntary discharge of urine and fæces. She was quite sensible. Under treatment by hot bottles, stimulants, and the hypodermic injection of ether and strychnia, she gradually revived somewhat.

There were no convulsions or twitchings, no retraction of the head, and no coma or delirium. The right pupil was smaller than the left, but both reacted. There was well-marked lateral nystagmus.

She was very sick, and vomited biliary matter. The pulse at times could not be counted, the rate being so high. The respiration was irregular and shallow, but never of the Cheyne-Stokes type.

For about a week or more she lay in a critical condition, sometimes almost unconscious, and always limp and without showing any interest in anything going on around her. For most of the time the temperature fluctuated about 100°, the actual maximum being 100·8° (rectal).

During this time other phenomena noted at one time or other were—contraction of the pupils, moaning, difficulty in swallowing, double facial paralysis, weakness of the left external rectus, tremors of the hands, ataxia of the hands, absence of deep reflexes, a trace of sugar in the urine, &c.

For days it looked as if a fatal termination might occur at any time, but gradually she began to improve and to gain in strength. She was long troubled, however, with incontinence of urine and fæces. Early in September she was able to walk a few steps unassisted, and she has continuously improved. There is still very great wasting of the muscles, but there is no paralysis of any of them, the loss of power in all of them being apparently proportionate to the loss of tissue. There is no facial paralysis. The knee-jerks remain exaggerated, and there is a trace of ankle clonus; the plantar reflex is present, but not active. There is still a trace of nystagmus.

In this case I have departed from the original diagnosis, and am inclined to regard it as a somewhat unusual form of disseminated sclerosis. The extremely grave condition present in July seemed clearly due to pressure on the brain, and could

Digitized by Google

not, in my opinion, be explained as of functional origin. The multiplicity of the phenomena cannot be accounted for by a solitary lesion, not even by a tumour of the brain, and, therefore, I am compelled to suppose that there are several foci of disease. The variability of the phenomena, and the periods of complete, or almost complete, recovery, which at first led to the diagnosis of hysteria, point rather, according to Dr. Buzzard,[1] to disseminated sclerosis, and the occurrence of marked nystagmus supports that view. The results of examination of the eyes are against the idea of the case being hysterical, for two recent separate observations of the field of vision, at intervals of a fortnight, showed no diminution of the field for colour, and there was no evidence of optic atrophy.

On 22nd September Dr. George Macintyre reported on the electric reactions, and his observations also tend to exclude functional disease. "The external popliteal nerve responds slightly to 2 m.a. and very distinctly to 4 m.a. on both sides; with this current there is a prolonged contraction, broken by some clonus. The tibialis anticus and the extensor communis digitorum on both sides respond markedly to 8 m.a. with the constant and 7 cm. with the induced current, but not to a weaker current. This is the case with a short current, but when a current of long duration is passed there appears a slowly produced spasm which continues during the passage of the current, and disappears slowly after the current is stopped. The induced current gets response at once, but seems comparatively weak. The left gastrocnemius gives the same slow spasm with a strong continued current, and very little response to a quick current of galvanism. The spasm is an over-extension of the foot, with over-extension of the toes, as though the current went to the front of the leg; it takes almost five seconds to disappear."

"The right leg with the same current seems to give no contraction (?) of the gastrocnemius, but there is great spasmodic over-extension of the toes and flexion of the foot. The induced at 7 m.a. gives contraction on the left, but none on the right. The right gastrocnemius, therefore, does not respond to the current. The left gastrocnemius with a strong current gives slight immediate contraction, and then a slow, strong spasm."

Judging from Dr. Buzzard's book already quoted, and from Dr. Bastian's *Various Forms of Hysterical or Functional Paralysis* (p. 123), where views of a different kind are put

[1] *On the Simulation of Hysteria by Organic Disease of the Nervous System*, 1891, pp. 58, 107.

Digitized by Google

forward, and also from the various articles on hysterical paralysis within my reach, the differentiation of the functional from the organic varieties of paralysis is in many cases still very difficult. That is my own experience, and in the present case all I venture to say is, that the phenomena seem to me now to point to organic disease, notwithstanding the temporary recoveries that take place.

II. *A case of myxœdema.*

This patient, 40 years of age, had been under treatment for Bright's disease, as there was undoubtedly a trace of albumen in the urine, a trace which persisted while she was under observation, but which was never accompanied by tube-casts.

The main facts that led to the diagnosis of myxœdema were the physiognomy, the speech, and the absence of œdema. The face presented a puffy, vacant appearance, there was anæmia with a pink flush over the malar bones, and the neck was greatly swollen but did not pit on pressure. The voice was hoarse and cracked.

The affection had been present for about a year, and was characterised by increasing general weakness, swelling, anæmia, and drowsiness, with some loss of memory and irritability, and cessation of menstruation.

Under observation, her chief complaint has been of pain in the back, and, latterly, of pain all over her. These pains have been removed by antipyrin, 10 grs. thrice daily.

She is now greatly improved, having been under treatment by thyroid tabloids, two daily. She is shown simply because such slight cases are very apt to escape observation.

III. *Progressive muscular atrophy with bulbar paralysis.*

Samuel M., aged 41, labourer, was admitted on 30th July, 1898, complaining of loss of power in his right arm. His attention was first drawn to this, three months earlier, by his finding that he could not button his collar. About the middle of May he had to give up the work he was at on account of its being too heavy, and even a lighter job that he obtained he had to retire from about the beginning of July, because he could not hold things with his hand. With the increasing loss of power he had observed the arm growing thinner, and he says that there is a feeling of numbness and stiffness without any pain. For several weeks he had also observed slight difficulty in speech, but none in swallowing. That was all that he himself had to complain of.

Digitized by Google

The right arm presents considerable atrophy of the muscles from the shoulder-blade downwards, particularly well seen in the hand, where the thenar and hypothenar eminences are flat as compared with the left side. The muscles show some fibrillary tremor. While he himself thinks that the right hand alone is affected, it is evident that the left also is involved, though to a less extent. A very striking fact now is slurring of his speech, of which he himself is quite conscious. There is very little difficulty in swallowing. There is now apparently slight right facial paralysis; the tongue on protrusion appears deflected very markedly to the right, perhaps due in part to some atrophy of the right side. He spontaneously states that he is shorter of breath than he used to be, and that he cannot now whistle at all, though formerly he could whistle. Nystagmus has been present at times, but there has been no squint. He is not conscious of any impairment in the legs, but his gait is scarcely that of a healthy man. The knee-jerks are exaggerated, and there is very marked jaw-jerk.

The affected muscles give either a feeble or no response to faradic currents which cause strong contractions in the corresponding muscles of the left hand and arm, while they give a slow, but prolonged (tetanic) contraction with galvanic currents which cause a distinct sudden jerk on the left side.

There is an alternate external strabismus; the other eye movements are normal. The left pupil responds better to light and in accommodation than the right. There are old corneal opacities, more marked in the right. The optic discs are somewhat pale, with their edges slightly broken; fundi otherwise normal.

That this is a case of progressive muscular atrophy there can be no doubt, and the involvement of the medulla oblongata, as shown by his speech, is quite in accordance with what we know of that disease. It is, however, to be noted that the bulbar paralysis has come on unusually early.

IV. *A case of paralysis agitans.*

An electrical instrument maker, 50 years of age, complains of muscular tremor affecting chiefly the left arm and hand. This has persisted for two and a half years, and is practically constant, though increased by voluntary action of the muscles and by excitement. It is ascribed by the patient partly to the constant muscular tension in his fingers and hands rendered necessary by the delicate nature of his work, and partly to a severe emotional shock at the time of onset.

The tremors of the left arm and hand are readily seen, and

Digitized by Google

there is slight tremor of the left leg, which began eighteen months after the arm was affected. A careful examination of the right hand and arm detects tremor there also, of which he is not aware. There is no rigidity, no muscular wasting, and little, if any, loss of power. The only sensory phenomenon is an occasional burning heat in the palm of the left hand.

This patient does not present any of the typical phenomena of paralysis agitans, except the tremors. The face is not expressionless, but mobile; there is a little bending forward of the head, but that might readily be accounted for by his position when at work; the gait shows no tendency to propulsion or retropulsion; the muscles are not rigid; and the speech is not unduly quick. It is not simple senile tremor, nor is it due to any toxæmia. The tremor has the characters of that of paralysis agitans, and I have no doubt that the other signs of that disease will manifest themselves in due time.

V. *A case of disseminated sclerosis* (?) *in an early stage.*

Patrick W., æt. 57, puddler, was admitted on 23rd September, suffering from pain in his right fore-arm on movement, and marked tremors. The history bore that, twelve months ago, on awakening one morning he found his right fore-arm and hand quite numb, and also painful. He was unable to go to work for four weeks, from which time up to eight weeks ago he was irregularly at work; for eight weeks past he has done no work on account of inability to use his right hand properly. From the onset there has been no improvement, but rather the reverse. The affection has been limited so far as he knows to the right arm, and he is not aware of any cause for it, unless that he is greatly exposed to chills in the performance of his work.

On examination on admission, the most striking fact was the development of tremors on voluntary movement of the right arm. On attempting to carry a cup to his lips its contents were spilt, the oscillations becoming very great and irregular the nearer the cup approached the lips—it was, in fact, the typical oscillation of disseminated sclerosis. The case was regarded as probably an early stage of that disease, although there was neither disorder of speech nor nystagmus. The grasp of the right hand was, and is, very feeble, but there was no disorder of sensation. The right elbow-jerk was not elicited. The typical oscillation above described was rapidly replaced by a much finer tremor, which is still induced by putting the muscles into action—as, for example,

Digitized by Google

by getting him to grasp one's hand — but he states that even when the arm is at rest on the bed tremors occasionally occur in it. The diagnosis of paralysis agitans has therefore been raised, and this is rather supported by his age and by the facial expression, but not by his gait. No tremor has been observed in the left arm, but it is undoubtedly weaker than normal. Since his admission nystagmus has been occasionally observed. He has slight difficulty in fixing with the left eye. The left pupil is smaller than the right, but both respond about equally to light and in accommodation. A detailed ophthalmoscopic examination could not be made with undilated pupil. The electric reactions are practically normal.

The pain present in this case and the suddenness of the onset suggest a neuritis as a possible cause, but the electric reactions and the presence of the deep reflexes do not support that view. I cannot, however, account for the pain.

I am still inclined to the diagnosis of disseminated sclerosis, the tremors when first seen were so characteristic. This diagnosis is rather confirmed by the occurrence of nystagmus.

VI. *A well-marked case of dermography or factitious urticaria.*

The patient, a man of about 25 years of age, presented himself at the Royal Infirmary Dispensary on account of a cough. On percussion of his chest, Dr. Dunlop was struck with the appearance presented by the skin at the point percussed, and tried writing on the skin, when each letter appeared in large raised wheals.

This is very readily shown, and the wheals persist for a long time, the full duration not being ascertained.

Cases so marked as this are extremely rare, but minor varieties are common; such, at least, is my experience, and I have been on the outlook for them for five or six years, without having seen more than about three as pronounced as the present case.

Dr. Alex. Robertson said that the absence of certain hysterical stigmata in the first case was in favour of the diagnosis. Bulbar paralysis was not infrequently associated with progressive muscular atrophy. In the fifth case shown, the amount of pain and the suddenness of the onset suggested neuritis. Might the nystagmus not be congenital? If it were not, the disease was probably disseminated sclerosis.

Digitized by Google

In the fourth case, the diagnosis of paralysis agitans was clear, though many of the typical symptoms were absent. The movements did not absolutely stop on resting.

Dr. Hinshelwood said that nystagmus might be congenital, or might be due to errors of refraction. The examination of the eye would assist in the diagnosis between hysteria and organic disease. In atrophy of the optic nerve the visual fields were contracted, but the amount of contraction was fairly constant; in hysteria the contraction gradually increased, and the fields for blue and yellow were the most diminished.

Dr. Walker Downie mentioned the case of a woman of 20 who had suffered from aphonia, apparently functional. She developed pleurisy, and as she recovered, her voice returned, but there were now many symptoms of disseminated sclerosis.

Dr. Middleton, in reply, said that no special inference was to be drawn from the examination of the eyes in the first case. In the fifth, the nystagmus was not congenital, for it was not constant, and there had been no physical defect while the patient was in the army. The amount of pain and the suddenness of the onset were undoubtedly unusual, but neither perineuritis nor neuritis would explain the phenomena. In his experience dermography was not very common. It was usually supposed to be associated with urticaria, but he had seen nothing like the condition he had shown in any case of genuine urticaria. It was more common in neurotic patients.

MEETING II.—21ST OCTOBER, 1898.

The President, DR. G. S. MIDDLETON, *in the Chair.*

I.—A CASE OF HEMIPLEGIA ASSOCIATED WITH DIPHTHERITIC PARALYSIS.

BY DR. W. K. HUNTER.

The first case I have to show is a child in whom a more or less typical hemiplegia is associated with various manifestations of diphtheritic paralysis. And I bring this patient before you, not as an example of a specially rare condition, for hemiplegia is not a very unfrequent accompaniment of the

Digitized by Google

debility which follows the fevers in children, but the clinical picture the little one presents is striking, and I think it will interest you.

The history of the illness, as told by the mother, throws considerable light on the nature of the disease, and I shall therefore give you a short account of it as we have it in the ward journal.

M. G., æt. 7, a schoolgirl, was admitted to Ward 8 of the Royal Infirmary on 14th September, 1898, complaining of loss of power on the left side of the body of three or four weeks' duration.

The present illness seems to date from about the end of July, when patient was sick and vomiting and complained of sore throat. These symptoms, however, attracted little attention, for it was not till a fortnight later that the throat was examined for the first time. The mother at this time noted that the tonsils were enlarged and that there was a greyish-white patch on each. There was also swelling in the glands at the angle of the jaw. A doctor was now consulted, and he pronounced the throat to be "very suspicious." He visited every day for a week, and ordered the throat to be painted every three hours. The mother states that almost from the beginning of the illness the voice had its present nasal quality, and that on swallowing, fluids were returned through the nose.

At the end of this third week of the illness patient was much better, and her parents thought it advisable, though recommended by the doctor not to do so, to take her to the coast for a change of air. But on the second day after her removal she was again sick and vomiting; and five days later she had a "screaming fit," when it was noticed for the first time that the face was drawn to the right side. The doctor was at once called, and he expressed the opinion that the patient had had an apoplectic attack. There seems, however, at this time to have been no loss of power in the arms, for the mother can distinctly remember the day after the seizure the child clasping her firmly round the neck with both arms. Two days later the doctor discovered a loss of power in the left arm and left leg, and he said there must have been a second shock. Since this time the left side of the face, the left arm, and left leg have remained paralysed, the speech has been thick and indistinct, saliva has dribbled from the side of the mouth, and there has been some difficulty in swallowing.

During the illness patient has been cross, emotional, and seemed to see imaginary people coming to strike her. There

Digitized by Google

has been defective control over the bladder and rectum, for she is unable to retain her urine and fæces, and passes both in bed. At no time has any convulsive seizure been observed.

Patient's previous and family histories are good, and they throw no light on the present illness.

On admission to hospital the patient presented a very helpless condition; she was evidently the subject of a wide-spread paralysis. The pupils were dilated, and responded to light incompletely and very sluggishly. There was no contraction on looking at near objects, and, as far as could be made out, the power of accommodation was completely lost. At times there seemed to be a convergent squint in the left eye, but the movements of both eyes were good, and this seemed to negative the idea of paralysis in any of the external muscles of the eyeball. The voice had a distinctly nasal quality, and the soft palate seemed completely paralysed. The palate also seemed insensitive to touch. There was no difficulty in swallowing, and no regurgitation of fluids through the nose. The tongue was protruded in the middle line. Very definite facial paralysis was obvious on the left side when patient laughed or cried. This paralysis affected chiefly the muscles of the lower part of the face, for both eyes could be completely closed. Patient was unable to raise herself in bed, indeed, she could scarce move herself in bed, and when raised she was unable to support herself in the sitting posture. Neither could she hold her head erect, it always falling backwards, forwards, or on to one or other shoulder.

The movements of the right arm were perfectly good, but there was complete paralysis in the left. This left arm had assumed the flexed attitude of hemiplegia, and it presented a certain amount of rigidity. Its muscles were distinctly atrophied, and the whole arm was cold and blue.

As to the legs, there seemed to be some loss of power in both, though less in the right than in the left, but the paralysis in the left leg was never nearly so complete as in the left arm. Patient could in no way support herself on the lower limbs, for when the feet were put to the ground the limbs doubled up under her. There was no paralysis of the ordinary or accessory muscles of respiration. As far as could be made out cutaneous sensibility was intact, but cutaneous reflex irritability seemed, on the whole, lessened. Thus, both plantar reflexes were defective, especially the left, which was almost absent; the right abdominal reflex was quite active, but the left much less so. Both knee reflexes were absent. Urine and fæces were passed in bed. Patient knew when she wished to pass

Digitized by Google

urine, but she could not retain it more than a second or two. The condition of the heart was quite normal.

The electrical reactions were tested on three different occasions, but the patient was so restless and cried so much during the process that the examination was not so complete and satisfactory as one would have liked. The reactions in the right arm seemed about normal, contractions being obtained with 2 m.a. galvanic and 9 cm. faradic. In the left arm the irritability of the muscles was considerably lessened, and it required over 3 m.a. to get a faint response with the galvanic current; at 8 cm. the contraction with the faradic current was very slight. Both legs responded to both kinds of electricity in much the same way as the left arm. In both arms and both legs K.C.C. was always greater than A.C.C. The muscles of the face only responded to strong galvanic and faradic currents, the response being less on the left than on the right side. In none of the muscles, then, could it be said that the reaction of degeneration was completely developed, although in many there was a much diminished electrical excitability, especially for the faradic current.

The patient has now been in hospital for over five weeks, and, although much better than on admission, she is still very helpless. She can now sit up in bed, but not with a feeling of much assurance. The left arm is still quite useless. Both legs can be moved about in bed, but both double up under her on any attempt to get her to stand. The left leg in this respect is more limp and useless than the right. The facial paralysis, though not complete, is still sufficiently apparent. The reflexes are as formerly noted. During the past fortnight there has been complete control over both bladder and rectum.

We have here, then, a patient with paralytic phenomena of wide distribution, but I think the causes of this paralysis are sufficiently evident. There seems no doubt that the child had diphtheria, and that to this disease we may attribute the cycloplegia, the paralysis of the soft palate, the paralysis in the neck and back, the paresis in the right leg, and the loss of control over bladder and rectum. But the paralysis on the left side of the face, in the left arm, and left leg, must, I think, be put in another category, and considered as a hemiplegia due to hæmorrhage, probably into the internal capsule. We know that such hæmorrhages do occur in diphtheria as well as in enteric fever; and the history of the mode of onset of this paralysis certainly points to the lesion being central rather than peripheral. It may be that in some of the muscles on

Digitized by Google

this paralysed side there is a double paralysis—both peripheral and central, both diphtheritic and hæmorrhagic—for the loss of the knee-jerks and the greatly diminished response to faradic electricity make one think there must be a peripheral disturbance of some kind or another in these parts. But, on the other hand, one cannot explain a well-defined hemiplegia of apparently sudden onset as being due entirely to peripheral causes, for such a condition, I think, would be unique. Neither, again, can it be contended that the bilateral paralysis in the neck, back, and lower limbs is a part of the hemiplegia, for the bilateral or "associated" paralysis of hemiplegia is usually only very slight and of but temporary existence.

As to the time of onset of the different diphtheritic paralyses, we have very few data to guide us. The mother took no notice of the pupils; but according to her account there must have been paralysis of the soft palate within the first week of the illness. The neck, back, legs, bladder, and rectum seem only to have become involved after the onset of the hemiplegia, for the child was dressed and walking about two days before the first apoplectic attack. After the second "shock" the child was "very helpless," but there was nothing more occurred, as far as the mother observed, pointing to any new development in the evolution of the disease.

Dr. Adamson asked if the heart was normal, and was told that it was so.

Dr. Middleton did not recall having seen a case of diphtheria followed by hemiplegia. It was unusual in hemiplegia to have the face affected first and the arm and leg after an interval, but the character of the facial paralysis in this instance was not usual in peripheral lesions.

II.—A CASE OF "MALADIE DES TICS."

By Dr. W. K. Hunter.

The second case I bring before the Society to-night is a boy suffering from a condition to which the French have given the name *maladie des tics.* It is just about a year ago that Dr. W. R. Jack drew our attention to this disease in a paper read before the Society on 6th December, 1897. The case then shown created much interest and no little discussion, and this is my excuse for presenting to you so soon again another example of such an interesting condition.

J. M., a boy aged 14, was admitted to Ward 7 of the Royal

Digitized by Google

Infirmary on 14th September, 1898, complaining of jerking movements of the head and limbs of some seven years' duration.

This patient was quite well till seven years ago, when he was frightened by a man chasing him while he was out in the early morning delivering milk. Shortly after this fright the jerking movements set in, and they have never completely left him. At first the movements were very pronounced, and patient was thought to have St. Vitus' dance; but by the end of three or four months their severity lessened, and the movements became much as they are at present.

The patient remained at school till he was 14 years old, but his attendance was always very irregular. He says the noise and heat of the school made him very tired, and often sick. He likewise suffered from headache and giddiness. These symptoms were at one time so pronounced as to cause his doctor to certify him unfit to attend school. Since the age of 11 he has been subject to a pain and weakness in his back, and he says he has often fallen down, his knees seeming to give way under him.

He was quite a good scholar at school, and the fact of his only being in the fourth standard when 14 years old is due to his very irregular attendance rather than to his being unable to learn his lessons.

The patient left school last January and started work in February. Since then he has tried three different situations, but he remained in none of them more than three weeks. His first two places were in weaving mills, but he there broke so many threads by the jerking movements of his wrists that he had to leave. The third situation was with a tinsmith. He says he could do the work here quite well, but he had to leave on account of the pain in his back.

He talks to himself in a low undertone, and at times emits a peculiar grunting noise, for which he has frequently been reproved.

The family history is important. The father is alive and well, though not very robust. The mother, aged 37, has been insane for a good many years, and is at present in Hawkhead Asylum. The patient is the oldest of seven, the youngest being 7 years old. With the exception of one dead in infancy, the other children are all alive and well.

Such, then, is the account of the illness as related to us by the boy's grandmother and by the boy himself. He has been in the wards now for over five weeks, and the observations made during that time tend to corroborate the above history.

Digitized by Google

We have found him a bright, intelligent boy of amiable disposition. He reads well, writes well, and spells well. There is no defect of speech or of any of the special senses. There is no motor paralysis and no area of anæsthesia. The tendon reflexes are active, and there is no ankle clonus. The superficial reflexes are normal. There is no tremor to be made out, and the patient performs the ordinary movements of everyday life without any apparent difficulty. But on watching him attentively for a time it becomes very evident that certain groups of muscles are affected by abnormal spasmodic contractions. These contractions, it is to be noted, though more or less involuntary, are co-ordinated, and similar in every respect to the ordinary voluntary movements of the affected muscles. In the face we note such abnormal movements as winking, corrugation and elevation of the brows, drawing up of the angles of the mouth. There is also a nodding of the head, shrugging of the shoulders, spasmodic flexions at the elbows and wrists, also a jerking movement in the legs not easily defined. These movements are absent during sleep, and, in general, they are unaffected by external influences, although the sudden approach of anyone towards the patient will often provoke a jerk of the head or a shrug of the shoulders. An occasional projection of the tip of the tongue and a jerk of the eyeballs to either side have likewise been noted. There is a voice spasm in the form of a low inarticulate sound which the patient emits at frequent intervals. He can prevent these contractions for a longer or shorter time, but this inhibition is usually followed by more violent jerking in the affected muscles. For instance, he can wind a reel of thread, but if the operation be long, the wrist gives a jerk and the thread is probably broken. The longer he keeps winding, the more frequently the jerks come on. The patient feeds himself quite well, and he has not been known to spill any fluid in so doing.

As regards the mental condition, apart from the feeling of sickness, headache, pain in the back, occasional stifling sensation, and difficulty of concentration, there are few of the other stigmata found in this disease. The patient talks to himself a very great deal, and he emits at intervals a low grunting sound; but there are, as far as we can find out, no "fixed ideas," no use of obscene words, no repetition of words, no special tendency to mimicry, and no necessity for doing sums in arithmetic. Efforts have been made to find out what he talks to himself about, but without a satisfactory result.

Digitized by Google

That, then, gentlemen, is the record of the case as it has presented itself to us, and I think you will agree with me when I call it a case of *maladie des tics.* That it is not simply a case of habit spasm is apparent when we consider the duration of the trouble, the age at which it set in, the wide distribution of the movements, the voice spasm, the mental phenomena, and the heredity. Neither is it a case of chorea—it was recommended for admission to hospital as a case of chorea. But the spasmodic contractions here are co-ordinated, and quite different in character from those of chorea, and they do not interfere in any way with voluntary movements.

In conclusion, I have to acknowledge the courtesy of Dr. J. Lindsay Steven in permitting me to show these two cases here to-night. They were admitted into his wards last month while I was on duty, and it is by his kindness that they still remain under my charge.

Dr. W. R. Jack said he thought there could be no doubt about the diagnosis. The absence of *idées fixes* and of the other phenomena detailed by Dr. Hunter did not in the least invalidate it, as these were often late symptoms of the disease, and sometimes did not make their appearance at all.

Dr. R. S. Thomson said that the boy had for two months been a patient of his in the Western Infirmary. At that time he did not talk to himself, this symptom having developed subsequently. In examining the case with Dr. Love, they had both agreed that it differed widely from chorea, and must be relegated to the class in which Dr. Hunter placed it.

Dr. Hunter replied.

III.—CASE OF ERYTHROMELALGIA.

By DR. JAMES CARSLAW.

The patient was a young woman, aged 24, who had been admitted to the Western Infirmary in June, 1898, with gastric symptoms and anæmia. There was a story of loss of colour and failing strength, with breathlessness and palpitation. There had been some swelling at the ankles, and some irregularity of menstruation, and the hæmoglobin was reduced to 60 per cent. The patient's previous health and her family history were both uneventful, except for the fact that she was

Digitized by Google

said to have had pains in the back, arms, and legs, at the age of 13, which were called "rheumatics." There was no evidence of cardiac disease.

Under dietetic and tonic treatment the patient steadily improved, and after three weeks was allowed to get up. However, after being up about a fortnight, she complained of pains in her legs, and was put back to bed. On examination of the limbs there was found an unusual condition—a painful swelling of the legs, principally between the knees and ankles, and not pitting on pressure. The pain was not specially related to the course of the lymphatics nor to the lymphatic glands. A difficulty was noticed in pinching up the skin, all the more distinctive because it was absent on the dorsum of the foot. There was a feeling of burning heat in the parts affected. This condition persisted, extending, perhaps, further up the limbs, but still leaving the dorsum of the foot practically free; and latterly the patient had begun to have the same feeling in the hands and fore-arms, although there was nothing very definite to be observed in the arms in the shape of swelling. There had been practically no change in the patient's condition during the previous month, and it seemed quite clear that she had never suffered in the same way before, and that any swelling of the feet that had occurred had been simply œdema in association with the anæmia.

The condition of the patient in detail was as follows:—She was suffering from a burning heat in the legs from the middle of the thighs to the ankles. This was aggravated by standing or walking, even by hanging down the limbs, and she was always easier in the horizontal position. However, even in the horizontal position the burning feeling might come on, though not so severely as when she was up, almost indicating that the condition was paroxysmal. She had a similar feeling of burning heat in the hands and fore-arms. In addition, there was marked redness of the limbs, with dilatation of numerous veins, and with the hand one could at once appreciate an increased surface temperature, and also the thickening of the cutaneous and subcutaneous tissues without pitting on pressure. The patient had no paralytic symptoms. There was no loss of sensation of touch, or of pain, or of heat and cold, although the electrical reactions were slightly altered. The reflexes were normal. There was no ataxia, and there had been no definite hysterical manifestations. There was no spinal tenderness, and there were no trophic changes in the limbs. Indeed, apart from the condition of her limbs, the patient appeared to be quite well. The temperature had all

Digitized by Google

along been normal, and her weight had steadily increased from 7 st. 8 lb. on admission to 9 st. ½lb. The diagnosis of erythromelalgia had been made, and that in an early stage.

Erythromelalgia was first described as a separate disease by Weir Mitchell in 1872, and in his original paper, and in subsequent papers (notably in an article in the *American Journal of Medical Science,* July, 1898), he has narrated several cases observed by himself and several reported by Graves, Paget, and others. As described by Weir Mitchell, this affection occurs chiefly in men; begins usually when the health has been depressed by some constitutional disease; affects principally the feet, usually the soles of the feet or the heels; and rarely occurs in the arms. There is usually great complaint of a burning pain, and with this there is increased redness, and perhaps swelling. The condition is much influenced both by posture and by temperature, easier when the limbs are horizontal and in the cold, but worse when dependent and in heat. An important diagnostic sign is increase of the surface temperature with the attacks, a point which was corroborated in the present case. From time to time new cases have been reported, principally in America and on the Continent, more or less like Weir Mitchell's, and the condition has been found along with distinct paralytic symptoms, so that the probability of its causation being some peripheral or spinal lesion interfering with the vasomotor system has become more and more evident. The disease usually runs a chronic course with alternating improvement and relapse, and is rarely amenable to treatment. The chief points of difference between the present case and Weir Mitchell's type were the distribution of the condition rather between the ankles and knees than in the feet, its presence in the arms, and the prominence of the brawny thickening of the tissues. The condition was considered as of special interest in that it had developed under observation in an infirmary, and was unaccompanied by any other nervous phenomena. It was contrasted with the transient attacks of local œdematous swellings which constitute angio-neurotic œdema. Moreover, the patient's condition was regarded as in many ways exactly the opposite of what is called Raynaud's disease—another vasomotor disturbance.

Dr. John Love said that he had twice seen the case, and had found that in the legs the faradic response was distinctly diminished, and that with the galvanic current A.C.C. was equal to K.C.C. This was of interest in view of Weir Mitchell's

Digitized by Google

recent opinion that the disease was due to a terminal neuritis, although he had been previously inclined to think it of spinal origin. Dr. Collier's present view was that the disease was spinal, as he had seen several cases in which it was associated with gross organic lesions of the cord.

Dr. Middleton mentioned that he had seen one case in which treatment, although continued for months, had produced no improvement.

IV.—NOTES ON A DISEASE OCCURRING IN LASCARS, RELATED TO VARIOLA AND VARICELLA, BUT DIFFERING FROM BOTH IN CERTAIN POINTS.

By Dr. R. S. Thomson.

The cases, a short report of which I have been asked to bring before you to-night, are of especial interest at the present time, when the question of influence of vaccination on small-pox is exciting so much interest both in the profession and among the laity. Statements of a startling kind with regard to the successful vaccination of small-pox cases during the course of the attack or of convalescence come to us from India, and those who are interested in the matter will find a reference to similar points in the minority report recently issued by the Commission on Vaccination. Here I would wish to draw a clear distinction between cases of small-pox in which we find the disease running concurrently with vaccination, and those in which vaccination is said to have been carried out successfully after the disease had run its course. These two conditions differ very essentially. In the first case, the patients in whom variola and vaccinia are running a concurrent course have not so far developed immunity, whereas in those cases where the attack of variola has been successfully passed through, immunity to that disease has been fully acquired, and not only is this immunity established against small-pox, but, so far as my own experience entitles me to believe, against vaccinia likewise. In the small-pox hospital at Belvidere I have vaccinated during the last few years 52 cases of small-pox. In these the operation was carried out either during the earlier eruption stage or during early convalescence, but in no single instance was I able to produce any reaction on the skin more than what might have been expected to follow a slight superficial abrasion. To my mind the conclusion is obvious: cases which vaccinate successfully during or after a reputed attack of small-pox are at least open to grave suspicion, and

Digitized by Google

as such reports come to us exclusively from tropical countries, notably India, the question is raised whether we may not have to deal in these climates with a disease which is not small-pox, though it presents many points of close analogy. The cases, a report of which I wish to bring under your notice to-night, in my opinion are examples of such a disease occurring in Lascars. It may be asked how it happened that physicians in tropical climates should be unaware of the existence of such a disease, but I think the explanation is a very simple one. Cases such as we are now considering, if presented to us in the course of an outbreak of small-pox, would almost certainly be diagnosed as cases of that disease occurring in a modified form, but when a group of such cases comes under our notice during a period of freedom from small-pox, then we are provided with what I might call a "pure culture" of the disease, and the diagnosis is consequently comparatively easy.

Sixteen cases of this disease were admitted to hospital in the spring of the present year from a steamship trading between Calcutta and this country. In addition to them one Lascar took ill during the earlier part of the voyage, but was completely convalescent when the ship reached Glasgow. A few days after her arrival, and when the ship was undergoing extensive repairs and alterations, a number of the crew fell ill with a disease which was certified to be small-pox, and as a consequence the patients were promptly isolated in the small-pox hospital. Thorough disinfection was carried out in those parts of the vessel occupied by the Lascars, and the precautions taken such as are usually adopted on a vessel infected with small-pox. In addition to the first cases sent into hospital, others were admitted later, and the whole number formed, as it were, three distinct groups, separated by variable periods which corresponded evidently to a period of incubation, seeing that owing to the precautions taken it seemed unlikely that anything but personal contact could be made responsible for the spread of the disease. The affection was obviously one of little infectivity, seeing that in addition to the Lascars affected there were other 52 Lascars living in the forecastle, while about 250 workmen were brought intimately into contact with some of the infected persons while cooking or while otherwise employed about the ship. On the first outbreak of the disease all the Lascars were revaccinated, and revaccination was offered to the workmen but was uniformly refused. Two of the Lascars were unvaccinated. In addition to these points of interest regarding the condition as to vaccination of those on board the ship, it must be noted that three of the affected

Digitized by Google

persons had already suffered from severe small-pox, two of them quite recently. On the supposition that this disease is small-pox, it would be necessary to provide some adequate explanation for the facts—(1) That the two unvaccinated Lascars escaped attack; (2) that 250 persons, none of whom had been revaccinated, likewise escaped attack; and (3) that 3 persons who had already had small-pox, 2 of them comparatively recently, should have suffered from so uncommon a thing as a second attack. While admitting that, on the supposition that the cases were small-pox, all these circumstances *might* occur, yet I venture to think that such a combination is about beyond the range even of probability. In addition to these facts it is important to remember, regarding the relation of this disease to vaccination, that of the 16 Lascars who suffered from the disease, 5 were revaccinated during the crusting stage, of whom 4 were successful and 1 failure, while all the remaining cases had been successfully revacccinated from two to four weeks before the onset of the affection for which they were admitted to hospital. These facts are entirely contrary to my experience of the behaviour of small-pox.

The most important feature of the disease was the eruption, which appeared in some cases concurrently with the onset of the general symptoms, and in others apparently on the second day. The first stage of the eruption consisted of papules, hard and shotty at first, more palpable than visible, and which on further development became conical and of a deep red colour. This eruption was distributed mainly on the back of the trunk and chest, but it occurred also in fair abundance on the scalp and face, and much more sparsely on the limbs. In some cases the bulk of this papular eruption persisted without change throughout the whole course of the attack, disappearing without showing any signs of vesiculation. In some cases, on the first, second, or third day of the eruption, a certain proportion of the papules changed with great rapidity into vesicles, well-marked vesicles being sometimes present at a very early period. True pustules were not observed, though some of the vesicles became sero-purulent. After the lapse of about forty-eight hours the vesicles began to dry in in the centre, when they presented a somewhat umbilicated appearance, the vesicles in the earlier part of their existence being free from umbilication. There was a wide and well-marked areola around the vesicles, and this persisted till crusting was well advanced. Forcible separation of the crusts left a bleeding surface, and when the crusts became detached naturally, a

Digitized by Google

rosy-red and deep cicatrix, which was quite free from pigment, was left behind, having a very close resemblance to a fresh small-pox scar.

No eruption was noticed in any of the cases on the palms or soles, but in the majority the palate and fauces presented a variable amount of eruption in addition to well-marked catarrh, and in some of the cases great complaint was made of the pain and discomfort in the throat.

The temperature ran a course of five or six days, was of a markedly remittent type, and reached 104° in the more severe cases. There was no secondary fever. The general febrile symptoms were very marked in some of the cases; very severe headache, with sleeplessness, vomiting, and backache, were observed in several. Albumen was found in the urine in only one case. There was no delirium, and none of the patients died.

From what I have said, I think that you will agree with me that while the disease we have been considering presents certain relationships to small-pox and chicken-pox, yet it cannot be regarded as either of these, but is a third disease, probably identical with that an outbreak of which was described over thirty years ago by Dr. Izett Anderson, of Jamaica. He observed 115 cases in the prisons and penitentiaries of Kingston during the absence of small-pox in that town, and under conditions favourable to the production of what I have already called a "pure culture."

Remarks by Dr. John Brownlee.—Dr. Brownlee said that he had examined the cases during their whole course along with Dr. Thomson, and that he had little to add to his description. He had seen a considerable number of cases of small-pox while resident physician in the small-pox hospital, and also had had an opportunity of seeing a number of adults suffering from chicken-pox. He was strongly of opinion that the affection from which these Lascars were suffering was quite distinct from either of these diseases. It was interesting, in this connection, to notice a reference in the report of the Buluwayo Hospital in South Africa to a disease known as "Kaffir small-pox." This, it was said, did not attack Europeans, and the opinion of the local medical men seemed to waver between the diagnoses of modified small-pox and severe chicken-pox. Though this disease might not be identical with that which Dr. Thomson had just described, yet the fact of this notice in the Buluwayo report showed that there was some element of difficulty. He had also recently met a

Digitized by Google

physician who had returned from Natal, who mentioned that he had seen such a disease, which, there was no doubt, was not small-pox, but regarding its place in the nosology there was a difference of opinion as to whether it was severe chicken-pox or a third disease. It was not at all impossible, reasoning from analogy, that there might be a disease allied to small-pox confined to one race of mankind alone. Sheep-pox, for instance, attacked sheep alone, and could not be communicated even to the most closely allied species.

Mr. H. E. Clark said that the small infectiousness of the diseased persons appeared striking, as the white sailors had not contracted the disease.

MEETING III.—4TH NOVEMBER, 1898.

The President, DR. G. S. MIDDLETON, *in the Chair.*

I.—CEREBELLAR ABSCESS SUCCESSFULLY TREATED BY OPERATION.

BY DR. T. BARR AND DR. J. H. NICOLL.

T. B., æt. 26, came to the Out-patient Department of the Ear Hospital on 17th May, 1898. He had had *purulent discharge* and *deafness* in connection with the left ear for ten years. During the past year the discharge had been more copious. In addition, he had, for a month, suffered from the following symptoms, all of which were present at the time of his applying for treatment:—*Pain* in the *ear*, *severe headache* (general), *giddiness*, and distinct, but not absolute, *facial paralysis*.

On 25th May, a week later, he returned. All his symptoms were aggravated, and, in addition, he suffered from *vomiting*, and *tenderness* on pressure over the *mastoid* and upper part of posterior triangle of *neck*. His temperature was 97·6°, and his pulse 56. His *breath* was foul, and he was distinctly *apathetic* and *drowsy*. He was seen by Dr. Barr, and at once admitted for operation.

The following day Dr. Barr opened the mastoid cavity. The knee of the lateral sinus lay unusually far forward, and

Digitized by Google

was exposed by the burr. It appeared healthy. The antrum, of small size, was found high up, situated in very dense sclerosed bone, and filled with pus and granulations. It and the middle ear were thoroughly cleared out, and packed with iodoform. After the operation he lay for a lengthy period drowsy, and subsequently passed a very restless night.

During the two following days he became still more apathetic and dull—though, when shaken up, his headache and sickness appeared quite as troublesome. Nystagmus was noted, and the left pupil was found to vary, being at times, though not constantly, larger than the right, and sluggish in reaction. He yawned repeatedly. Dr. Ernest Thomson, who at this time examined the eyes, reported slight optic neuritis in the left eye, and a suspicion of optic neuritis in the right.

On 29th May, three days after the mastoid operation, Dr. Nicoll saw the patient with Dr. Barr. At that time the patient was nearly, but not completely, comatose. The left pupil was dilated (nearly twice the size of the right), and very sluggish in the light test. The facial paralysis was very evident. The temperature was 97·6°, and the pulse 96. While, therefore, the patient presented most of the *general* symptoms of lesion (presumably abscess) in the encephalon, there were present no clearly *localising* signs of that lesion, unless the yawning. This, however, while noted, did not appear, in the semi-comatose condition of the patient, sufficient to warrant a diagnosis of cerebellar lesion.

Later in the day Dr. Nicoll operated, Dr. Connal administering chloroform, and Dr. Barr co-operating. In the absence of definite localising evidence, the already free mastoid aperture made by Dr. Barr, three days previously, was still further enlarged. This was done chiefly backwards around the sinus and upwards towards the floor of the middle fossa. Everywhere the bone presented the white denseness of old sclerosis. Nowhere could any "lead" be discovered in the form of a track of pus, granulations, or necrosis traversing the bone.

The temporo-sphenoidal fossa was then opened in the usual situation (Fig. 1—*1*, p. 208). The dura bulged somewhat, and appeared to some extent hypervascular, and, on incising this, the cerebral cortex bulged in the aperture. The temporo-sphenoidal lobe was explored with the canula in various directions to the depth of 1 to 2 inches, with negative result.

The cerebellar fossa was then opened at the spot indicated (Fig. 1—*2*, p. 208). On removing the bone the dura at once bulged, white, in the aperture, evidently under considerable pressure, and, on incising this, the cerebellar cortex also presented

Digitized by Google

the marked bulging and pallor characteristic of pressure. The exploring canula, on being inserted into the cerebellum, tapped an abscess cavity at a depth of about half an inch from the cortex. From the abscess there drained a quantity of excessively fœtid pus. (No exact measurement could be made; and the quantity was variously estimated by those present at from half an ounce to 1½ oz. Cover-glass preparations and cultures, made by the West of Scotland Clinical Research Laboratory, both failed to yield demonstration of the presence of micro-organism.) A rubber-drainage tube was placed in

FIG. 1.
(For references, see text.)

the abscess cavity, extending 2 inches from the scalp, where it was secured by suture.

Within a few days marked improvement had taken place, all the patient's symptoms becoming less pronounced. At each dressing the abscess cavity was gently douched with weak carbolic lotion.

At the end of six weeks the patient was practically in every way well, except that at each dressing there escaped both from the drainage-tube and the middle ear a certain quantity of slightly fœtid pus. On 9th July, therefore, Dr. Nicoll again operated, making an aperture into the cerebellar fossa through

Digitized by Google

the posterior aspect of the petrous bone (Fig. 1—*3*, p. 208). This passage externally opened into the mastoid cavity, made by Dr. Barr, just in front of the knee of the sigmoid sinus. Internally, as the illustration indicates, it entered the cerebellar fossa through the triangular area of the posterior aspect of the petrous bone bounded by the sigmoid sinus behind (and below), the internal auditory meatus (with the auditory and facial nerves) in front, and the tentorium cerebelli (and superior petrosal sinus) above. At this point, at the inner end of the passage cut in the bone, the dura was incised and an aperture made through the cerebellar cortex into the abscess

FIG. 2.
(For references, see text.)

cavity. Through this channel the abscess was drained as well as by the pre-existing drainage route in its posterior aspect established at the former operation.

The result of this second opening was a marked diminution in the amount of the discharge. At each dressing the abscess cavity was gently douched through, the weak carbolic lotion being always injected by the posterior aperture. At the end of five weeks the discharge had all but ceased from the abscess, though it continued from the middle ear.

Fig. 2 (p. 209) represents the condition of parts at this date. In each of the two apertures is placed an arrow-headed probe,

Digitized by Google

the points of which meet in the abscess cavity. Probe No. 1 lies in the anterior drainage channel, steadied by the lightest touch of the nurse's finger. (To define it in the photograph, the end was covered with black varnish, part of which has become smeared on the helix.) Probe No. 2 lies in the posterior drainage channel, the external end of the drainage tube, with its restraining scalp suture, being shown. The arrow-head of this probe is indefinite and badly defined in the photograph. This is owing to the constant movement resulting from the cerebellar pulsation. It was found impossible to steady both probes by the finger without hiding too large a portion of the patient's head. The distance between the two apertures is 1¾ inch, which, however, in the photograph is not apparent, owing to the "fore-shortening" produced by the patient's head having been turned too far forward. The large mastoid operation cavity has become largely filled up by granulation tissue. Running upwards from the mastoid cavity, over the squamous bone, is the scalp scar of the incision made for exploration of the temporo-sphenoidal lobe. This scar pulsates, owing to the deficiency of the cranium beneath it at the point where the bone was removed over the middle fossa.

At this date, five weeks after the second drainage operation, drainage was discontinued through the anterior channel, which within the following two weeks ceased to be patent into the abscess cavity. The scalp suture was also removed from the posterior tube, which was subsequently shortened slightly from time to time as the contraction and filling up of the cavity gradually expelled it.

During the following weeks, though the patient was in every way well in general health, and the tube practically free from discharge, it was not entirely withdrawn, as the middle ear constantly contained small quantities of pus, which apparently escaped from the internal ear. It was not, therefore, considered advisable to allow the abscess drainage channel to close.

On 23rd September a bony sequestrum was discharged from the internal into the middle ear, and removed by forceps through the mastoid cavity. The sequestrum was of irregular shape, and of the size of a large pea (one-third inch by one-quarter inch). The tube was at this date withdrawn, and the posterior wound permitted to close, which it did in a few days.

Fig. 3 (p. 211) represents the patient at this stage. The facial paralysis has quite disappeared, he walks—out of doors and

Digitized by Google

up and down stairs—without giddiness, reads and writes, and has not a symptom of his former trouble, with one exception, viz., that he still has some slight discharge from his middle (internal ?) ear.

FIG. 3.

This Dr. Barr treated. At the present date he has returned to his occupation, having no trace of his late illness except that his old deafness remains (though the ear discharge has

Digitized by Google

ceased), and that, in the meantime, there are pulsating areæ in the two situations where the scalp covers the bony gaps over the temporo-sphenoidal lobe and cerebellum respectively.

Instances of recovery from cerebellar abscess are not of frequent occurrence. In 1896 Dr. Acland and Mr. Ballance published in the *St. Thomas's Hospital Reports* a paper on cerebellar abscess containing a most full and exhaustive account of the literature of the subject up to that date. They state—(1) That every case of cerebellar abscess not operated on has proved fatal; (2) that, up to the date of the paper, there had been published ten (possibly eleven) cases of recovery after operation, and sixteen cases of death after operation. "These numbers," however, the authors remark, "do not accurately represent the percentage of success after operation, since it is within our knowledge that many fatal cases have not been published."

Experience of such cases goes to prove that (1) early operative interference in the way of discovering and subsequently draining the cavity offers the only chance of recovery in cases of intracranial pyogenic lesions; (2) that the results in such cases of operative interference have been more favourable in temporo-sphenoidal than in cerebellar abscess; (3) that the cause of death in cerebellar abscess is, in a large majority of the cases, dropsical distension of the lateral ventricles (with œdema of the surrounding brain tissue). This ventricular dropsy appears to be the result of obstruction of the veins of Galen, produced by thrombosis originating in their lumina or extending thence either from the superior cerebellar veins or from the straight sinus.

Dr. Walker Downie said that the case illustrated the danger of chronic suppuration of the middle ear. Such cases were often neglected until distinct inflammatory mischief had set in, which might spread to the interior of the cranium. He saw a case of the kind eighteen months ago, where the patient did not continue treatment, and developed a short time ago, after a chill, symptoms of earache and tenderness over the mastoid process. The patient was operated upon by Professor Macewen, and a mastoid abscess and a large cerebellar abscess were found. The patient was now going on well.

Dr. J. G. Connal had seen Dr. Nicoll's patient at the Ear Hospital, and sent him into the house. The symptoms were as already detailed. He had noted the variability of the left pupil.

Digitized by Google

Dr. Nicoll, in reply, mentioned that the high mortality in cerebellar as compared with cerebral abscess was due, not to the difficulty of reaching the abscess, but to the distension of the lateral ventricles, consequent upon thrombosis of the veins of Galen.

II.—A CYSTIC GOITRE REMOVED BY OPERATION.

BY DR. BEATSON.

The patient was a girl of 21, who had always enjoyed excellent health. In the summer of 1897 she noticed a swelling of the left lobe of the thyroid gland, which gradually increased. She was admitted to the Western Infirmary in the summer of this year, when the question of exophthalmic goitre was discussed. There was, however, no sign of it, except a slight degree of von Graefe's symptom, and Kocher's method of removal was performed on 3rd August. The recovery was good, and the resulting deformity small. Chloroform was used, although Kocher never gave it in thyroid operations. No difficulty was experienced in its administration.

III.—A FATTY TUMOUR REMOVED FROM THE SUPERIOR MEDIASTINUM.

BY DR. BEATSON.

The specimen, which was about the size of an orange, was removed from the superior mediastinum of a man of 45. It presented just above the manubrium sterni, where a slowly increasing tumour had been noted to be present for five years. It had caused no inconvenience. From its consistency the tumour was supposed to be a cyst, but upon operation (on 23rd October) the supposed cyst-wall was found to be the deep cervical fascia. When this was incised, fatty lobules protruded, and the tumour was easily shelled out. Dr. Beatson had never seen a similar case, nor had he found one on record.

Mr. H. E. Clark said that the tumour, which had not yet been examined microscopically, might possibly contain elements connected with the thymus gland.

Dr. Middleton expressed his interest in the former case, and said he supposed there was enough of the thyroid left to prevent the occurrence of myxœdema.

Dr. Beatson replied.

Digitized by Google

IV.—TWO CASES OF LARGE MENINGO-ENCEPHALOCELE REMOVED BY OPERATION.

A. BY DR. JAMES ADAMS.

This was a case occuring in a child of 6 days old. When seen there was a large bilobed swelling protruding from the posterior fontanelle, which proved to be a hydro-encephalocele. The sac was on the verge of rupture. It was therefore tapped on the following day, and 6 to 8 oz. of blood-stained fluid were removed. There was still a large mass left, and the sac was therefore opened and the distended and protruding left lobe of the cerebrum was trimmed down. The sac was then closed. The child remained well for three days, when its breathing became affected, and it died in six hours.

B. BY DR. J. H. NICOLL.

This case was similar to the last, the child being, however, only 3 days old. The sac had been wounded in parturition, and there was slight leakage. The tumour was excised, and the child died on the fourth day.

Mr. H. E. Clark said that in such hopeless cases speculative treatment was justified, and much might be tried that would not be justifiable in ordinary cases. Excision was the most likely method of treatment in cases of meningocele, and leakage was the most frequent cause of death in cases of excision, as the sac was so thin that the ligatures often gave way.

Dr. Macgregor Robertson said that the cases reminded him of those of two rabbits operated on by Christiani, from which the cerebral hemispheres had been entirely removed. They behaved thereafter like ordinary rabbits, except that they tended to revolve in circles. They lived for a week or ten days, and then died. The human animal at birth was like the adult lower animals in regard to cerebral function.

Dr. Adams replied that he had been afraid to give chloroform. The sac was fairly thick at the base, and he had not been troubled with leakage. The temperature had not risen even before death.

Dr. Nicoll, in reply, described the steps of his operation.

Digitized by Google

V.—NÆVOID TUMOUR OF THE INTESTINE ENCLOSED IN A DOUBLE INTUSSUSCEPTION, INVOLVING OVER FIVE FEET OF BOWEL, SUCCESSFULLY RESECTED FOR ACUTE INTESTINAL OBSTRUCTION.

BY DR. J. H. NICOLL.

Miss A., æt. 20, seen in consultation with Drs. M'Lennan and Middleton on the morning of 28th September.

Symptoms, which had set in suddenly twenty-four hours previously, were:—*Acute abdominal pain* (general, but most severe in epigastrium)—*hiccough*—*eructations*—*vomiting* (copious, but not distinctly stercoraceous)—and absolute *constipation* (not even flatus passing). Pulse, 90; temperature, 100·6°.

A fortnight previously she had had a similar attack, less severe, and lasting only a few hours; and during the whole of that fortnight she had had pain in the epigastrium, coming on shortly after meals, and lasting for an hour.

Physical examination.—Abdomen distended. Left side resistant, tender, and dull. Right side less resistant and quite tympanitic. *Per rectum*, Dr. Middleton detected fluid in Douglas' pouch. The patient was conveyed in an ambulance to the M'Alpin Nursing Home, and at two o'clock I operated.

Operation.—On opening the abdomen a quantity of brownish serous fluid escaped, and the sausage-shaped mass forming the specimen was discovered. To reduce this intussusception I made prolonged efforts by manipulation. Failing in this, I punctured it with a canula and evacuated some fæculent mucus, and again attempted reduction, but unsuccessfully. I then incised the outer tube and inserted two fingers, but again failed to obtain reduction. An incision was then carried through the second tube. From this long coils of intestine escaped, but reduction remained impossible. I therefore excised the entire intussusception, which, hardened in spirit, forms the specimen. The divided intestinal ends were united by circular enterorrhaphy, and the abdomen closed.

Further history.—The patient made an uneventful recovery; was removed home at the end of three weeks, and is now—four months after operation—in perfect health.

Specimen.—Figs. 1, 2, and 3 (pp. 216, 218, 219) represent the arrangement of parts. The specimen, which has been examined and reported on by Drs. R. M. Buchanan and

Digitized by Google

Teacher, it is intended should be preserved in the Museum of the Pathological Institute of the Western Infirmary. The *tumour*, on microscopic examination, proved to be what its naked-eye appearances suggested, viz., a nævoid growth. It contains two calcareous phleboliths of the size of split peas.

Remarks.—The following points in the case appear worthy of note :—

1. *The specimen.*—The position of the tumour is remarkable.

FIG 1.

DIAGRAMATIC REPRESENTATION OF ARRANGEMENT OF PARTS.

1—1', tumour growing in wall of intestine enclosed in first or short intussusception ; 2—2', second or long intussusception enclosing the first intussusception and loose coils of intestine ; 3, mesenteric ; and 4, free—borders of intestine.

According to the various theories as to the production and increase in extent of intussusceptions the tumour, as the cause of the intussusception, ought to have occupied a position at the extremity of the intussusception, near 2'.

2. *The cause of the impossibility of reduction of the intussusception.*—This was, as reference to the diagram (Fig. 1, p. 216) will show, the presence of the tumour, which, in the position it occupied, acted in the same way as the cork of a bottle which has been accidentally pushed through the narrow orifice down into the widening portion of the neck. Only

Digitized by Google

after its bulk had been reduced by the hæmorrhage consequent upon resection, could it be pulled out of the neck of the sheath to the position shown in the photographs.

3. *The extent of small intestine resected.*—Dr. R. M. Buchanan and myself measured fully five feet of intestine. The specimen almost certainly, however, contains several inches more, as it was impossible to fully extend the bowel for measurement without destroying the unique arrangement of the parts.

4. *The mesentery.*—There was nothing in the appearance of the intussusception (which externally measured only sixteen inches) to indicate that the vessels of over five feet of mesentery were crowded into the concavity of the curve of the intussusception. Hence the first cut of the scissors in dividing the mesentery gave rise to smart hæmorrhage; and the subsequent ligaturing seriatim of the vessels consumed considerable time.

5. *The method of clamping the divided intestinal ends.*—This was done by Drs. A. M'Lennan and Kay by means of simple digital pressure. Mechanical clamps, though useful when operating without assistance, are open to the double objection that, when firmly applied, they are apt to produce subsequent gangrene of the part of the bowel compressed, while, when loosely applied, they are apt to slip and permit escape of fæces into the peritoneum.

6. *The method of uniting the divided intestinal ends.*—This was by means of Czerny-Lembert suture, in part continuous. The one advantage claimed for all forms of mechanical apparatus for uniting the divided intestinal ends is speed, and the consequent lessening of shock. In cases where the patient is so much collapsed that the matter of a few minutes more or less in the duration of the operation would appear to be of vital importance, and in operation at the hands of inexpert or unskilled operators, speed must be admitted to be the prime consideration, and must be permitted to override all others. For a time, indeed, the fashion was to use mechanical means of union in all cases, and the "button" in some form or other promised to become the routine method. A decided change in opinion has of late been manifesting itself, however; and at present, to judge from current surgical literature, not a few operators hold that, while the "button" offers increased speed, and therefore ought to be at hand for use in desperately collapsed cases, it affords speed at the expense of other and not less important factors in the case. The considerations which have led to this

Digitized by Google

change of opinion are mainly four:—(*a*) The records of a number of cases demonstrate that, in the use of the "button," the operator has simply substituted for the intestinal obstruction produced by the original cause that due to the presence of the "button." (*b*) Certain former enthusiastic advocates of the "button," as the result of further experience, now advise suture in addition—the divided intestinal ends being united by the "button" and sutured over that. (*c*) Many modern surgical text-books are at pains to point out that the

FIG 2.

PHOTOGRAPH OF SPECIMEN.

× Disc of paper placed on tumour—which has been pulled out of the upper end of the double intussusception. (Its original site is shown in the diagram, Fig. 1, p. 216.)
On the free border of the intestine is seen the incision made to facilitate the attempt at reduction.

mortality statistics of abdominal operations stand in need of revision—that a number of the cases which are stated to die after abdominal operations from "prolonged shock," and from "secondary shock," in reality die from profound systemic septicæmic absorption from an infected abdominal cavity which, as Erichsen explains, is the seat of a peritonitis so acutely fatal that the patient dies before there has been time for the development of signs of peritonitis sufficiently marked to be recognised as such *post-mortem*. (*d*) The various forms of "button" were first introduced to practice

Digitized by Google

for the most part on the strength of laboratory experiments, the results of which conclusively prove the superiority of "button" over suture in uniting divided intestine. To those familiar with laboratory experiment there is nothing conclusive in these results as regards man, the facts being that the intestine of dogs and rabbits is so thin that successful suture, *i.e.*, suture without penetration of *all* the intestinal coats (with consequent septic peritonitis), is, as a rule, impossible; whereas, in the much thicker intestinal wall of

FIG. 3.

Photograph of specimen, after windows have been cut in the first and second tubes of the large intussusception. Through these windows some of the coils of contained intestine are protruding.
× The tumour—which has been incised for examination.

man successful suture is easy, and becomes still more so when the intestine is thickened by inflammatory congestion, as it is in many of the cases requiring operation. Further, it is well-known that the results of "button" operations in man have been by no means so good as those obtained in animals. Nor is this to be wondered at. In the laboratory the operator has a healthy animal and an empty intestine, with very little matter to be passed through the lumen of the "button." In an operation for intestinal obstruction in man, on the other hand, he has to deal with an intestine loaded with retained

Digitized by Google

and putrid contents, pints of which have to pass through the narrow lumen of the "button" under the reviving, and frequently excessive, peristalsis of the bowel. Under these circumstances it can hardly be surprising that obstruction of the lumen, premature detachment of the "button," intussusception of the bowel enclosing the "button," and similar accidents are of frequent occurrence.

I am one of those who believe that, while the "button" ought, in one form or other, to be at hand for those cases in which speed at all costs is the one prime consideration, its use should be restricted to such cases; and that in the majority of cases simple suture offers advantages, in the way of security of union and freedom, from mechanical obstruction of the bowel, which outweigh the advantages claimed for the greater speed got by using the "button." Moreover, it is by no means certain that, in the hands of an expert operator, union by simple suture, especially if continuous, occupies much more time than union by use of the "button," particularly if, after the halves of the "button" have been sutured in place and "locked," security has to be attained by sutures placed outside the apparatus.

In ordinary resection cases I employ the Czerny-Lembert suture, usually continuous. In cases where the intestinal walls are much thickened by inflammatory swelling and the bowel above is loaded with large quantities of fæcal matter which have to be subsequently passed over the line of suture, I have made use of a method which I described to the Glasgow Medico-Chirurgical Society in January, 1896. The principle of the method is the removal of a collar of mucous and submucous coats from the distal end, the placing of the proximal end (with or without removal of its peritoneal coat) inside the distal, and securing it there by two rows of suture (continuous or interrupted). The description of the method was subsequently published in the *Glasgow Medical Journal* and in vol. i of the *Transactions of the Glasgow Medico-Chirurgical Society*. In both of these publications I added a note to the effect that Robinson, of Toledo, had, in the dog, carried out a method of suture which, while accomplished by means of a rubber bobbin or tube, was more or less similar. Of Robinson's experimental operation in dogs I was unaware when I carried out my operation in man, and subsequently described it to the Society. The method has just been re-discovered by Dr. Skelly, and published in the *Annals of Surgery* for September, 1898, the diagrams illustrating his descripton being practically identical with those kindly made

Digitized by Google

for me in 1895 by Dr. J. Campbell M'Clure, and exhibited to the Society when I described the method in January, 1896. A proceeding which has suggested itself to three independent workers, has probably something to commend it. I believe it to be useful in the cases I have indicated, viz., those in which the intestinal walls are thick from congestion, and the lumen much loaded above the line of suture.

Dr. James Adams agreed that the use of buttons and of clamps should be entirely discarded. It would be interesting to see how the patient would thrive in the future, after the removal of so much bowel.

Mr. H. E. Clark had at first been charmed with Murphy's button, as, compared with the suture, it saved time. Apart from that, he thought that the fewer mechanical appliances employed the better for the patient. He had since found the button causing ulceration and septic peritonitis, and was inclined to agree with Dr. Nicoll in condemning it.

Dr. Adams mentioned that Dr. Alexis Thomson had had a successful pylorectomy, in which he employed Murphy's button, but the button was not passed for thirteen months after the operation.

MEETING IV.—18TH NOVEMBER, 1898.

The President, DR. G. S. MIDDLETON, *in the Chair.*

I.—CASE OF CARCINOMA OF THE TONSIL.

BY DR. J. G. CONNAL.

Dr. J. G. Connal showed a case of carcinoma of the tonsil, portions of which were removed on four occasions for the purpose of facilitating the act of swallowing. There was no pain complained of.

Dr. Walker Downie said that the case was of interest, as adding to the number of cases of primary cancer of the tonsil on record. When he had shown a similar case eight years ago, it was maintained by others that cancer of the tonsil was always secondary to cancer of the tongue. Cases which had been placed on record since then, however, showed that this was not so.

Digitized by Google

Mr. H. E. Clark said that such cases were not inoperable in the early stages, and that even in the later stages operation might relieve the pain and dysphagia for some time. Even in this case, although there was great glandular enlargement, the mass was free; but, on the whole, an operation was inadvisable.

II.—A CASE ILLUSTRATIVE OF THE EARLY OCCURRENCE OF EYE SYMPTOMS IN EXOPHTHALMIC GOITRE, WITH REMARKS.

BY DR. JAMES HINSHELWOOD.

The patient is a young married woman, 24 years of age. She was quite well up till two years ago, when she received a severe shock, having witnessed the death of two young men by drowning. After that she became very nervous, and suffered considerably from left hemicrania. The pain was confined to the left side of the face, the neighbourhood of the left eye and temple, extending to the vertex. About the beginning of June she noticed prominence of the left eye, and about three weeks thereafter she further observed fulness of the right. She was married at the end of June, and since then the prominence and staring appearance of the eyes have become gradually worse. In order to get advice about this peculiar appearance of her eyes she came to Charlotte Street Eye Infirmary, where she was first seen on 7th November, 1898.

When first seen there was marked exophthalmos of both eyes, with retraction of the upper lid, widening of the palpebral aperture, and absence of winking, thus giving the patient that staring, startled appearance which is so characteristic of Graves's disease. On asking the patient to look downwards, Graefe's symptom was very well marked. With the eye symptoms alone there was therefore no hesitation in forming an opinion as to the nature of the disease from which the patient was suffering, The diagnosis was confirmed by further examination of the patient. She admitted that since the eyes became prominent she had become much more nervous, and that she suffered, though not to a great extent, from palpitation. These symptoms had, however, troubled her so little that she had not sought any medical advice until she came to the Eye Infirmary regarding the prominence of her eyes. On taking her pulse then and on other occasions, it was found to range from 120 to 132 per minute. There was no cardiac

Digitized by Google

murmur. On examination of the thyroid only a very slight prominence was observed, not any greater than is frequently seen in young women in perfect health, and certainly not so marked as to be pronounced pathological.

She was put upon gradually increasing doses of antipyrin, beginning with 5 grains three times daily. When she was shown to the Medico-Chirurgical Society, after a fortnight's treatment, there was a decided improvement as regards the eye symptoms. The prominence of the eyes and the retraction of the upper lid were decidedly less marked. The dose had been gradually increased to 15 grains three times daily. The nervousness, according to the patient's statements, was distinctly less, but the tachycardia remained the same.

Sir Wm. Stokes, in an article in the *British Medical Journal* of 29th October, 1898, remarks that two distinct forms of exophthalmic goitre may be recognised, and that for purposes of prognosis and guide to treatment a distinction should be made between those cases commencing with enlargement of the thyroid and those commencing with tachycardia. In the cases commencing with enlargement of the thyroid he regards the symptoms as due to toxic substances secreted by the thyroid, and states that therefore little, if any, benefit is as a rule derived from internal medication, but that great improvement, and sometimes complete recovery, can be effected by partial removal of the enlarged gland. Sir Wm. Stokes, however, does not state any opinion as to the results of internal medication in the other class of cases, where the enlargement of the thyroid is not the primary symptom, but he evidently regards these cases as not likely to be benefited by thyroidectomy. Now, a very large number of cases belong to this category, and in a large proportion of these the eye symptoms are the first manifestations of the disease in the patient. This fact has been impressed upon me by my experience at the Eye Infirmary, where such cases present themselves. In another case shown by me to the Medico-Chirurgical Society, and reported in the *British Medical Journal*, 25th June, 1898, the first symptom was unilateral exophthalmos, followed by slight swelling of the thyroid, but without tachycardia. Possibly such atypical cases belong to quite a different category and have a different etiology from the classical type of the disease in which the enlargement of the thyroid is the first symptom, followed usually in regular sequence by tachycardia, palpitation, and, last of all, exophthalmos. Certainly the toxic theory will not

Digitized by Google

account satisfactorily for these atypical cases in which enlargement of the thyroid is a secondary symptom. Nor can an affection of the sympathetic explain satisfactorily all the eye symptoms met with in these cases. If the exophthalmos, and the retraction of the upper lid (Stellwag's symptom), and Graefe's symptom are due to an affection of the sympathetic, how is it that the fibres supplying Müller's muscle are alone affected and those supplying the iris escape? In my case of unilateral eye symptoms there was no difference in the size of the pupils of both eyes. In that case also the disappearance of Stellwag's symptom while Graefe's symptom remained unchanged proved conclusively that these symptoms are entirely distinct and dependent upon different causes. While Stellwag's symptom may be explained by an affection of the smypathetic, another cause must be sought to explain Graefe's symptom, which is really a disturbance of the co-ordinated movement of the simultaneous descent of the upper lid and globe of the eye, and which is probably due to a central disorder of the oculo-motor nuclei. This view is strengthened by the comparative frequency in exophthalmic goitre of paresis of the external ocular muscles, and particularly of the internal recti. From a study of the eye symptoms we are led to the conclusion that the changes producing these are in the oculo-motor nuclei, and from the negative evidence of pathological anatomy, that the disturbance is one of function and of the nutrition of the nerve elements as in epilepsy and chorea. It was this view of the disease which led to the administration of antipyrin, which has been given with success in the treatment of epilepsy and chorea. Our experience of it is as yet too limited to draw any important conclusions, but certainly the favourable effects evidenced in these two cases after its administration are highly encouraging.

Dr. Alex. Robertson said that the nomenclature of this disease should be altered, as it was Parry, of Bath, who had just directed directed attention to it. It might, therefore, be called Parry's disease. It was well-known to begin in different situations, and at one time hyperthyroidism had been thought to be its cause. The speaker had all along been inclined to regard the medulla as the seat of the disease, and asked whether a lesion in that situation might not be regarded as the cause of the increased growth of the thyroid gland. He had for some years treated it by passing an electric current through the medulla from behind forward, through the nose and cervical spine, and he had thought the treatment of use. As

Digitized by Google

the disease might be cured spontaneously, one should form a guarded judgment as to the effects of treatment.

Dr. W. K. Hunter thought the the symptoms pointed to a lesion of the sympathetic nerve, and that the results of the French operation (resection of the nerve) were in favour of this conclusion. Resection of part of the thyroid gland was very dangerous, possibly owing to the sudden escape of thyroidin into the circulation.

Dr. J. C. Renton said that the reasons for the origin of the disease were various. Shock was frequently a factor in the etiology. He had noted improvement in some cases under the administration of thymus gland.

Dr. Napier mentioned a case in which thymus gland had proved useless in his hands.

Dr. Middleton said that no one view as yet accounted for all the cases. It was difficult to accept Sir W. Stokes' attempt to classify them according to their mode of origin, as they often could not be separated in that way. It was also difficult to be positive as to the result of treatment, as some of the cases might recover or relapse spontaneously.

Dr. Hinshelwood, in reply, said that, according to Stokes, cases beginning with enlargement of the thyroid gland were suitable for operation, while those beginning with exophthlamos were not. Such cases were often first seen at eye infirmaries. With regard to treatment, he did not wish to claim too much for any particular drug.

III.—THE RELIEF OF PAIN IN THE BACK NOT DUE TO ORGANIC DISEASE.

By DR. W. F. SOMERVILLE.

Dr. W. F. Somerville read a short paper on the relief of pain in the back not due to organic disease. He laid stress upon the value of regulated movements.

Dr. Napier considered that the pain in these cases was often the result of muscular fatigue, and was often relieved by the measures which had been mentioned.

Dr. J. C. Renton said that many such cases were due to adhesive conditions existing in the muscles, which might be entirely relieved by systematic exercises. Mechanical treatment ought not to be neglected.

Dr. Alex. Robertson hinted that the improvement might, to a certain extent, if not entirely, be the result of suggestion.

Digitized by Google

IV.—A FURTHER CONTRIBUTION TO THE STUDY OF WORD-BLINDNESS.

BY DR. JAMES HINSHELWOOD.

Dr. Hinshelwood's paper will be found *in extenso* in the *Lancet* for 14th January, 1899.

Dr. Alex. Robertson said that two distinct groups of symptoms must be recognised—letter-blindness and word-blindness. Their localisation was merely a further differentiation of the old localisation theory. We still knew too little to speak without a certain degree of reserve upon such a point.

Dr. Ernest Thomson asked if the patients could read words consisting of one letter only.

Dr. Love mentioned that there had been a great improvement in the agraphia of one of the patients referred to. He agreed that cases of letter-blindness were not so rare as was supposed. He was inclined to adopt the view of the subdivision of the centres. This subdivision was not confined to the auditory and visual centres, as Baginsky had observed the converse of the condition known as astasia-abasia, elementary movements having been lost, while the more complex movements were preserved.

Dr. Middleton agreed with Dr. Robertson that it was inadvisable to be too dogmatic. The majority of the cases were not clearly defined, and it was difficult to suppose, in the case of foreign languages, that each was assigned a little compartment to itself. So far, there had been very few *post-mortem* examinations bearing upon the point.

Dr. Hinshelwood replied that clinical observation came before pathology. His dogmatism was not that of ignorance, but the result of careful study. His views were theoretical, but had been arrived at by induction from clinical observation.

Digitized by Google

MEETING V.—2ND DECEMBER, 1898.

The President, DR. G. S. MIDDLETON, *in the Chair.*

I.—ENDEMIC GOITRE IN LANARKSHIRE, WITH OBSERVATIONS ON THE PATHOLOGY OF THE DISEASE.

BY DR. DAN. M'KENZIE.

Although an examiner at one of the recent "finals" in Glasgow objected to the statement of a student that goitre occurs in the endemic form so near his centre as Larkhall, the disease does exist there. With little trouble I have brought together and detailed, during the last five years, some ninety cases occurring in my own practice. I spent some little time in going over the literature of the subject, and embodied the result of my work in a Thesis for M.D. presented to Glasgow University in April, 1898.

In my paper to-night I shall not go over the distribution of the disease in Europe, Asia, and America,[1] but (1) shall touch only upon its endemic occurrence in Scotland; and (2) shall make a few remarks on the pathology of the disease.

I. *Endemic goitre in the Scottish Lowlands.*

The centres of goitre in Scotland compared with many of the countries of Europe, particularly those bordering on the great mountain ranges of the Alps, Apennines, and Pyrenees, are few in number and small in superficial area. In the interior of Perthshire, and on the east coast of Fife, endemic goitre is said to be present, but the greatest endemic centres are found in the Lowlands. In 1862, Dr. A. W. Mitchell[2] described it as occupying "the greater part of Roxburgh, the upper parts of Selkirk and Peebles, the eastern parts of Ayrshire (where it touches Lanark and Dumfries), the upper district of Lanark, the whole of Kirkcudbright and Dumfries, the west of Berwick, and the east parishes of Wigtown. It

[1] See A. Hirsch's *Handbook on Geographical and Historical Pathology,* translated by C. Creighton, M.D., New Sydenham Society, 1885, p. 122 *et seq.*

[2] A. W. Mitchell, M.D., "On the Nithsdale Neck or Goitre in Scotland," *Brit. and For. Medico-Chirurg. Rev.,* April, 1862, lviii, p. 502.

Digitized by Google

reaches its intensity in the upper valley of the Nith," where Dr. Chalmers, of Thornhill, reports it affects "half the women."

A glance at the map of Scotland will show that this fairly large area is in and around the Lothian Hills, roughly speaking.

Dr. Jackson writes to me (1897) from Sanquhar, where Mitchell reports that the disease reaches its intensity, that goitre is still common in that district, but that the individual goitres are small, and cause no trouble. The only part of Lanarkshire where Mitchell knew of its occurrence was in the extreme south of the county. I can now supplement that knowledge both from my own observation and from reports sent me by medical men practising in the district.

Endemic goitre exists in varying degrees of intensity in the valleys of the Clyde and its tributaries (particularly in those of the west side) in the middle and upper wards of the county. It attains its maximum severity in the coal mining districts of Larkhall, Dalserf, Stonehouse, Wishaw, and Carluke, and in the agricultural districts of Strathaven, Lesmahagow, and Blackwood. It dies off immediately north of Larkhall somewhat abruptly, so that cases seen in Hamilton are importations from our neighbourhood. Drs. Goff and Grant inform me that it is quite absent from Bothwell and Blantyre. In Strathaven the endemic prevalence of goitre is as great perhaps as with us in Larkhall, affecting particularly the farming classes there, among whom it is found to the remote western boundaries of the county and to the adjacent parts of Ayrshire. Dr. D. Dougall, of Strathaven, to whom I am indebted for this information, also states that it is increasing in severity. In Lesmahagow and Blackwood parishes the numbers affected with goitre are considerable, and according to Dr. J. Lindsay, there is no sign of amelioration there. From the extreme south of Lanarkshire conflicting reports reach me. From some sources I am told that goitre is quite absent; from others that it does exist, though to a slight extent. From what Mitchell says, however, and from conversations I have had with men in practice there, I think we are right in saying that the disease is probably prevalent in those parts, but, owing to the slight enlargement of the gland, is not observed unless specially looked for.[1]

In and around the town of Larkhall I find about 25 per cent of the female inhabitants are goitrous in such a way

[1] I have to express my thanks to the gentlemen mentioned in the text, and also to Dr. John Millar, of Newmains; Dr. Mackenzie, of Abington; and Dr. Adams, of Lanark, for kindly supplying me with details of the endemic in their respective districts.

Digitized by Google

as to attract attention; in a much larger percentage the gland will be found larger, fuller, and more obvious to the palpating finger than usual. Men are rarely affected, children of both sexes occasionally. I have seen two congenital cases. In one infant the enlarged gland filled up almost the whole space between chin and sternum in such a way as almost entirely to obliterate the natural hollow here. The gland subsided to quite a small goitre in about three months under suitable treatment.

Of the whole population, perhaps 10 to 15 per cent are goitrous, the great majority so slightly as to escape their own notice. I have, however, seen some very large tumours.

About 98 per cent of the cases occur in the mining and labouring classes.

The most severely smitten parts are those in the Avon valley and towards Strathaven westwards, and the largest goitres are found in people whose forefathers have lived here before them.

I have seen one or two cases of cretinism, but not in such connection as to suggest its origin from the same cause as goitre, *i.e.*, they were probably cases of sporadic cretinism.

In going over the parish records I find only one death attributed to "goitre;" I have seen one other myself.

I think, after considering all the facts of the case, that the endemic is less severe and wide-spread than it used to be.

II. *Etiology of goitre as an endemic.*

Endemic goitre has been, like the Low Countries for Europe, a battleground for ardent medical controversialists of all ages. Each epoch of medicine has assumed its favourite theory to be the cause of goitre, and each observer has supposed it to be due to the physical feature which differentiated his district from immune regions around. St. Lager[1] tells us that he can number no fewer than three hundred and seventy-eight authors and forty-two different views of its causation! So perhaps I may owe the subject an apology for burdening it with another, if indeed it is a new one.

We shall lay aside all the more ancient views, such as rarity of air, absence of sunlight, of iodine, presence of lime salts in the drinking-water, &c., &c., long ago shown to be untenable.

The modern view, that goitre is caused by a *contagium vivum* of some kind occurring in the soil of the affected

[1] St. Lager, *Etudes sur les causes du Crétinisme et du goître Endemique*, Lyon, 1868 (now out of print).

Digitized by Google

localities and reaching man by the drinking-water, may be pretty well looked upon as proved. For no other theory of causation can account for—

1. The occurrence of the disease within sharply demarcated areas.

2. The fluctuations in the severity of the endemic (observed when watched over a large number of years).

3. The fact that boiling the water of a "goitre well" renders it harmless.

4. The occasional total disappearance of the disease from a district after the introduction of good drainage.

As to what the nature of the organism of goitre may be we are yet in the dark, but the many points presented by goitre in common with malaria suggest that the *contagium vivum* is one of the protozoan group. I observe in a recent number of the *British Medical Journal*,[1] that Professor Grasset, of Montpellier, states he has found an organism in the blood of persons recently goitrous, with characters something like the parasite of malaria as described by Laveran. Going upon the same lines I made, during the year 1897, many examinations of the blood of goitrous people with a uniform want of success.

Although the features of most endemics of goitre show clearly that the drinking-water acts as the vehicle for the poison, I find that goitre as it exists now in Larkhall has no connection with our water-supply. The towns of Larkhall and Bothwell (separated from each other by about seven miles) have had the same water-supply for the last sixteen years. No water is introduced into the Bothwell supply other than from the same source as that of Larkhall, yet we find Larkhall affected with goitre and Bothwell quite free from the disease. I therefore attribute the Larkhall endemic to an infection conveyed directly from the soil to the body by eating with unclean hands, &c. The influence of the old surface wells is clearly proved, for those of the inhabitants whose conservatism forbids them to employ the "gravitation" water are all goitrous.

We are still ignorant of the causes which lead the organism of goitre to prefer certain localities to others. All the older theories which were at one time supposed to account for the prevalence of the disease have been found wanting. At the present moment we are awaiting definite information as to whether any particular geological formation or formations

[1] "A Hæmatozoon in Goitre," *British Medical Journal*, 24th September, 1898, p. 915.

Digitized by Google

have an influence on the endemic. Bircher,[1] as a result of one of those painstaking investigations so peculiarly Teutonic, concludes that goitre in Switzerland occurs only on the trias, eocene, and marine sedimentary formations, while freshwater sediment, and Jurassic formations, with crystalline, chalky, and volcanic rocks, are free from the disease. It also occurs, he says, on Silurian, Devonian, and carboniferous rocks.

Kocher,[2] of Berne, on the other hand, in 1889, after a series of investigations no less painstaking, comes to the conclusion that the rocks excluded by Bircher are really affected. Kocher attributes the presence of the disease to a "mixing up" (*beimischung*) of the rocks. What exactly a "mixing up" of the rocks may mean, I fear geology does not inform us. One suggestive point of Kocher's, however, is that where goitre occurs there is generally much organic matter on the rocks.

From some of the characteristic features of goitre endemics we may, I think, infer a little as to the probable habits of the goitre organism.

Epidemics of goitre have rarely been observed, and then only in districts previously goitrous. Large epidemics of goitre, sweeping suddenly over a large part of the world and retiring as suddenly, do not occur. So we may take it that the organism is of slow growth. Its definite confinement to certain districts, where it is found over long periods of time and from which it almost never spreads, shows that it requires some special conditions for its existence. What these conditions are we do not yet know. We connect them only in the vaguest possible manner in some way with the soil, and possibly with certain rocks or geological features. The divisions between a goitrous and a neighbouring non-goitrous country (see remarks on Larkhall endemic) are cleanly cut, so that the organism when removed from its normal habitat must quickly perish or be rendered inert.

The water of many goitre-wells, the surface drainings of many goitrous soils, and the discharges of many goitrous individuals must find their way into rivers, yet we never hear of the banks of rivers being affected with the goitre endemic from the source to the sea; proving that, although the organism lives and is generally conveyed to man in drinking-water, it is easily destroyed by admixture with purer water.

[1] Bircher, *Der Endemische Kropf u. seine Beziehungen zur Taubstummheit u. zum Cretinismus*, Basel, 1883, p. 14 *et seq.*

[2] Kocher, *Vorkommen u. Vertheilung des Kropfes im Canton Bern*, Bern, 1889.

Digitized by Google

We have no knowledge as to whether it spreads from man to man directly or through a medium.

III. *Etiology of goitre in the individual.*

In my opinion, the goitre virus when introduced into the body induces an increase in the internal secretion of the thyroid gland. This theory is supported by the character of the symptoms, by the microscopic appearances of the enlarged gland, and by many peculiar facts in the treatment of the disease. These I shall run over in the order named.

Symptoms.—It is a striking fact that, apart from the oft-times troublesome and sometimes dangerous pressure symptoms resulting from the presence of a bulky tumour in the neck embracing and compressing the trachea, &c., the patient is free from symptoms. A woman, for example, with a moderately-sized or even a large goitre is thereby not at all incapacitated for work if pressure symptoms are absent, as they often are. That is to say, that the thyroid gland, which recent research has shown to be intimately connected with the economy, is affected in such a manner in endemic goitre as to have no harmful effect upon the general condition. Contrast this with the profound alteration occurring in exophthalmic goitre and in myxœdema.

After looking over much of the literature on the subject, and watching my cases closely, I can find only a few doubtful evidences of general disturbance, as distinct from pressure symptoms, in goitrous patients. These are—

1. Irregularity of the pulse; sometimes found. This may arise from interference with the vagus by pressure.

2. Flushing and heats. Vasomotor disturbances quite as often found in non-goitrous women.

3. Goitrous asthma—a peculiar form of dyspnœa, sometimes ending in sudden death. Has been attributed to some general constitutional disorder, but we may quite as reasonably look upon it as due to suddenly arising interference with the recurrent laryngeal nerve.

4. I have noticed in most cases a peculiar sallow or yellow tint on the face. This feature occurs likewise in cretinism. I have seen no account of it elsewhere (except Prof. Grasset's "cachexia").[1]

These, taken together or separately, however, do not form a characteristic clinical picture leading one at once to search for a goitre.

[1] "A Hæmatozoon in Goitre," *British Medical Journal*, 24th September, 1898, p. 915.

Digitized by Google

You may remark that endemic cretinism, which never exists save in association with goitre in the endemic form, is a constitutional disturbance of the severest type. But endemic cretinism introduces one or two new features into the situation which, while altering our conception of the whole, do not interfere with the question of endemic goitre, for goitre is often found as an endemic without cretinism.

A glance at the symptomatology, therefore, teaches us that the enlarged thyroid of endemic goitre is of such a nature that it does not induce any important constitutional disturbance.

Turning now to the *pathology*. As you know, goitre begins generally about puberty. The thyroid gland, in the first instance, is the seat of a hyperplasia of the gland follicles. In the normal thyroid of an adult the follicles are regular in size and shape, almost always round, lined by a single layer of cubical epithelium, and separated from each other by normal connective tissue. The follicles are uniformly packed with colloid.

In the infantile thyroid the follicles are less regular in size, but are, as before, all more or less round. The cells under high power are seen to be larger and more granular than in the adult gland, and line the follicle in more than one single layer. Colloid material is entirely absent.

In the fœtal thyroid the whole is infinitely more cellular, and the cells are even larger than in the infantile gland. The division into follicles by formed connective tissue is much less marked, and they appear as clumps of cells separated from each other by newly-formed connective tissue. Colloid is absent.

In the thyroid of endemic goitre the follicles vary enormously in size. They are no longer uniformly round, but present a wavy outline. The cellular contents of each follicle are not limited to a single layer of cubical cells. There is marked cell-proliferation, and cell-groups crowding in upon the colloid material from the wall of the follicle are often seen. The amount of colloid contained by the different follicles varies enormously. The interfollicular connective tissue is more or less all over packed with round cells.

In the normal gland the cells lining the follicles are cubical, and in one single layer. In goitre the cells are enlarged, irregular, and highly granular. Generally speaking, with the exception of the round cell infiltration and new formation of fibrous tissue, the whole appearance resembles that of the

Digitized by Google

fœtal gland. But a more striking similarity is to be seen in some sections. Large areas of hundreds of epithelial cell-groups arranged like fœtal follicles are found. Their cells are large, columnar, and rounded, with a strongly marked granular nucleus. As a rule, they fill up the whole follicle, although colloid matter is to be seen in one or two. These cell-groups or fœtal follicles are situated in the meshes of a newly-formed connective tissue rich in spindle cells. The general shape of these follicles is round, but some are very irregular in outline. In their midst, here and there, are dense groups of round cells. This is an area of newly-formed follicles, the "fœtal adenoma" of Wölfler.

As a whole, the appearances are those of high glandular activity, and tally with the description of the enlarged thyroid of endemic goitre as being a "hyperplasia of the follicles of the gland with a corresponding increase in colloid material."[1]

The appearances found by Victor Horsley[2] and Murray,[3] in cases described by them as "compensatory hypertrophy" of the thyroid gland, bear such a close resemblance to what I have just described that, in my opinion, the enlargement of the thyroid gland found in endemic goitre, with its hyperplasia of glandular elements, is of the nature of compensatory hypertrophy.

Wölfler[4] has shown that in the normal thyroid gland embryonic masses of thyroid cells are found here and there, particularly towards the periphery of the gland, and these under certain stimuli are capable of taking on a kind of normal growth. Such a change as he describes probably occurs normally in pregnancy when the gland enlarges to cope with the increased metabolic changes of that period.

The primary parenchymatous enlargement of the thyroid in goitre is peculiarly liable to rapid secondary changes in the direction of—

1. Increase of fibrous tissue, a sequel of the round cell infiltration. Cirrhosis of the gland occurs, and the follicles

[1] Jas. Berry, M.B., "On the Pathology of Goitre and some other Diseases of the Thyroid," *Transact. Pathol. Soc., Lond.*, 1890, vol. xli, p. 258.

[2] Victor Horsley, "Physiology and Pathology of the Thyroid Gland," *British Medical Journal*, 5th December, 1896, p. 1623.

[3] Geo. R. Murray, "Discussion on the Pathology of Exophthalmic Goitre," *British Medival Journal*, 3rd October, 1896, p. 894.

[4] Wölfler, "Ueber die Entwickelung u. den Bau der Schilddrüse mit Rücksicht auf die Entwickelung des Kropfes," Berlin, 1880, and "Ueber die Entwickelung u. den Bau des Kropfes," *Archiv f. Klin. Chirurg.*, Bd. xxix, 1 and 4 Heft.

Digitized by Google

are seen small, distorted, compressed, and often entirely obliterated by the great growth of dense connective tissue. This process does not go so far as in the myxœdematous gland.

2. Cyst formation from dilation of follicles and subsequent coalescence of dilated follicles to form one or two huge cysts. All very large goitres are cystic.

3. Colloid increase. The follicles are large, and the whole gland contains colloid material in excess.

4. Vascular goitre, in which the blood-vessels dilate and intercommunicate, forming a huge spongy plexus of large venous spaces. In such a goitre I found colloid material lying free in the lumen of the blood-vessels.[1]

According to Gutknecht,[2] vascular goitre develops from a hyaline or colloid degeneration of the tissues.

From the pathology, then, it has been shown that the microscopic appearances of the gland are similar to those found by Horsley and Murray in compensatory hypertrophy.

If we assume that the organism of goitre affects metabolism in such a way as to demand an increase of the thyroid secretion, we can explain the occurrence of this hypertrophy.

A few facts from the *treatment* of goitre support this theory.

Goitre in the early stages, before the onset of secondary changes, may be successfully treated by thyroid or colloid feeding. Here the increased demand for thyroid secretion is met with from without, and the thyroid gland becomes smaller in size. If the treatment is stopped, the gland is liable to enlarge again.

Iodine is our sheet-anchor in the treatment of goitre. During the course of iodine administration in goitre, a series of phenomena, bearing upon this idea in a very interesting and suggestive manner, has been observed. A general loss of weight and fat, weakness, palpitation of the heart may occur, ultimately going on to a dangerous wasting and decline of vital powers if the iodine is not stopped. These symptoms were originally attributed to the iodine, but they do not correspond with iodine as it is usually seen. It was noticed that they happened oftener with small than large doses (probably because the small doses led to a quick reduction in the size of the gland and the amount of gland-secretion, while large doses were used in the more serious cases). This, coupled with the discovery of *cachexia strumipriva*, led

[1] Dr. A. G. Auld (*British Medical Journal*, 25th January, 1896) found colloid material in the same situation in diseased suprarenal capsules.

[2] Gutknecht, "Die Histologie der Struma," *Virchow's Archiv*, 1895, Bd. xci, 2 and 3 Heft.

Digitized by Google

Lebert[1] to believe that these were symptoms due to the withdrawal of the thyroid secretion consequent upon the reduced size of the gland. That is to say, that the normal thyroid secretion, such as the iodine would leave untouched, is insufficient for the needs of the body in the presence of the goitre virus.

I have observed when treating goitrous patients with thyroid gland that they can stand a very much larger dose of the remedy than a normal individual can.

The occurrence of cretinism along with goitre may be explained in the light of this theory. If, during the growing period of life, the thyroid gland atrophies or is diseased in such a way as to interfere with its functions, sporadic cretinism results. If in a goitre district the demand instigated by the virus for a larger supply of the gland secretion cannot be met with during the growing period, even although the gland may be enlarged and working at full pressure, cretinism will again result.

The only drawback to this theory is that in adult life myxœdema ought to be common in goitrous localities. But we are only now becoming acquainted with myxœdema, and, possibly, as the knowledge of myxœdema becomes more widespread, we may hear of its prevalence in goitrous regions. I know of only one case of goitre and myxœdema.

To sum up, the modern view of goitre is that it is a disease caused by a *contagium vivum*, limited to certain areas for some unknown reason, existing in the soil and reaching man by drinking-water or unclean hands. I should add that the organism when introduced into the body induces an increased demand for thyroid secretion, which the gland hypertrophies to supply. Mikulicz[2] holds opinions similar to mine, but does not seem to go so far.

And the proofs I have adduced in favour of this idea are—

1. The gland enlargement is accompanied by no constitutional disturbance.

2. The microscopic appearances of the primary changes are those of a gland hypertrophied and active.

3. Treatment by thyroid is followed by reduction in size of the gland, which stops if the remedy is stopped.

4. The successful removal of a goitre by iodine treatment

[1] Lebert, *Die Krankheiten der Schilddrüse*, Breslau, 1862, p. 143.

[2] Mikulicz, "Thymus-fütterung bei Kropf u. Basedow'scher Krankheit.," *Berliner Med. Woch.*, 1895, Nr. 16.

Digitized by Google

has been followed by symptoms due to deprival of increase in gland secretion.[1]

Sporadic goitre may also be explained in a similar manner.

Dr. J. Lindsay Steven said he was interested in the account of a goitre endemic so near Glasgow. He thought Dr. M'Kenzie had been wise in differentiating the symptoms due to pressure of the gland from those which might be the result of constitutional disturbance.

Dr. Charles Workman thought Dr. M'Kenzie had material in this subject for many years of work. He wondered why, if a goitre endemic existed so near Glasgow, they did not see cases of goitre oftener in the wards of the infirmaries.

Dr. Alex. Robertson said that in his opinion the older views of goitre being due to some chemical change in the water, &c., must be given up, and that the *contagium vivum* theory held the field alone.

Mr. H. E. Clark considered that the *contagium vivum* idea was in nowise proved, and that it was simply a theory of these times when everything is put down to the action of a germ. Dealing with the geology of goitre, he said he was disappointed that Dr. M'Kenzie had not told them the geological features of those parts of Lanarkshire where he had found the endemic.

Dr. R. M. Buchanan criticised Dr. M'Kenzie's account of the symptoms. He asked if examinations of the pulse-rate, continued over a lengthened period, did not show an increase in the rapidity of the pulse, and whether Dr. M'Kenzie had not observed some degree of mental lassitude or lethargy in goitrous patients.

Dr. M'Kenzie, in reply, said that he had not observed any undue rapidity of pulse-rate in goitrous people, but had not devoted special attention to this point. He had already alluded to irregularity of pulse, a not uncommon feature. As a rule, he found goitrous women quite as active intellectually as their neighbours. The geology of goitre was in his opinion not yet clear. Larkhall was situated upon the southern rim of the great coal basin of Central Scotland. The thicker coal seams give out just north of the village, and the transition to carboniferous limestone occurs about 1 to 2 miles to the south. In addition to the coal beds, red and grey sandstones, shales, and fireclays are found. Intrusive basalt is met with here and there. He thought that the *contagium vivum* theory was

[1] For further information on this and other points, see Ewald's *Die Erkrankungen der Schilddrüse, Myxödem, u. Cretinismus*, Wien, 1896.

Digitized by Google

proved, and alluded to the many points held in common by goitre and malaria.

II.—MICROSCOPIC SPECIMENS, ETC.

BY DR. DAN. M'KENZIE.

Dr. M'Kenzie also showed microscopic specimens of (1) normal adult thyroid, (2) fœtal thyroid, (3) goitrous thyroid, showing newly-formed follicles, (4) cystic dilatation of follicles in goitre, (5) compressed and distorted follicles from hyperplasia of connective tissue, (6) follicular cells in goitre crowding over colloid material. He also showed photographs of goitrous patients, and of (1) an enlarged thyroid of endemic goitre (*post-mortem*); (2) contorted and compressed trachea from the same case.

III.—PROFUSE HÆMATEMESIS DUE TO "PORE-LIKE" EROSION OF THE GASTRIC ARTERIES—NO ROUND ULCER—EXULCERATIO SIMPLEX OF DIEULAFOY.

BY DR. J. LINDSAY STEVEN.

In the following remarks I intend to call your attention to a lesion giving rise to sudden profuse hæmatemesis, which, though perhaps not an uncommon one, is probably not often thought of in connection with severe bleedings from the stomach. Further, the nature of the cases in which this lesion occurs, from the great ease with which it may be overlooked even at the *post-mortem* examination, may be erroneously explained, or perhaps not explained at all. It has recently been my lot to have had under my care a number of cases of very severe hæmorrhage from the stomach, so severe as in all of them at once to threaten the lives of the patients, and as two of them unfortunately came to a *post-mortem* examination, I have thought it right to bring before you the clinical and pathological notes in detail. The usual causes of hæmorrhage into the stomach are so well known that, whenever we meet with a case, we almost invariably think of one or two well recognised lesions, such as simple perforating ulcer, malignant ulcer, or hyperæmia due to portal obstruction. To none of these categories, however, do the cases I am about to demonstrate belong. Any of the lesions I have mentioned may give rise to profuse and sudden effusion of blood into the cavity of the stomach, and it is natural that we should think of them

Digitized by Google

when such cases occur, and equally so that we should be surprised when the autopsy shows that they are not present. In both of my cases, during the lives of the patients, perforating ulcer was regarded as the most likely cause of the hæmorrhage, but in neither of them was an ulcer of the ordinary type present. Even a cursory examination of the literature of hæmatemesis convinces us that this is not an uncommon experience, and in not a few cases the apparently healthy state of the stomach as demonstrated *post-mortem* has led the observers to suppose that the bleeding may have been due either to vaso-motor disturbance or to exhalation from the vessels. It is in the hope that the details I am now to submit may throw some light both on diagnosis and treatment that I bring these cases before you.

CASE I.—*Profuse hæmatemesis due to "pore-like" erosion of a branch of the gastric artery—Arrest of the bleeding under rectal feeding and subcutaneous saline injection—Death soon after from exhaustion due to uncontrollable diarrhœa.*

Mrs. G., æt. 28, a housewife, was admitted to Ward 8 of the Royal Infirmary on 24th October, 1898, complaining of a vomiting of blood which took place on Saturday, 22nd October.

Up till four weeks before admission the patient had enjoyed good health, and, in particular, no history of gastric symptoms before this time could be obtained. Four weeks before her admission she first experienced anorexia and pain after food, the pain beginning seven or eight minutes after a meal, lasting for about an hour, and not being very severe. A week before admission a paroxysm of pain occurred about 4 o'clock in the morning, obliging her to get out of bed. In about half an hour she became sick, and vomited profusely for the first time. She was ignorant of the character of the vomit, but she noticed no blood-stains on her clothing afterwards. The vomited material had a bitter taste. All that day the pain in the stomach was very severe and anorexia complete. The pain remained severe during the following week, and though going about, she was very weak and unable to take food. On Friday, 21st October, she did much housework, and on Saturday, although feeling very weak and sick, she continued at her household duties till about 1 o'clock in the afternoon, when she was forced to lie down. Shortly afterwards she began to vomit blood, the blood being put up in two large gushes, amounting in all to about 1 pint. She was admitted on Monday (24th) without any recurrence of the hæmatemesis

Digitized by Google

having taken place in the meantime. The bowels were naturally constipated, and she had never observed anything resembling blood in the motions.

On admission she was found to be a sparely-built woman, on the whole fairly well-nourished, but presenting considerable pallor of the skin and mucous membranes. The tongue was clean, but there was a slightly fœtid odour in the breath. The pulse numbered 100 and was somewhat soft. The respirations were 24, and unembarrassed. The temperature on admission was 98° F. There was no tenderness on pressure in the epigastrium, and nothing abnormal either here or elsewhere in the abdomen could be made out on physical examination. The heart and lungs presented healthy characters, as did likewise the urine, which contained neither albumen nor sugar.

The foregoing account is from the clinical report by Dr. George Coats, house physician. I saw the patient at 9·30 P.M. on the evening of her admission, and entered the following account of her condition in the ward journal:—

24th October.—During the afternoon the patient rested in bed without apparently being very ill in any way. About 8·10 P.M., while endeavouring to pass urine, she suddenly became sick and vomited violently. The vomited material consisted almost entirely of bright red blood, a large portion of which went on the floor. The part seen by Dr. J. Lindsay Steven measured 12 oz., and consisted almost entirely of pure blood-clot mixed with a little curdled milk which she had been receiving in small quantities at intervals of an hour or two since 2 P.M. When seen at 9 P.M. the patient was quite collected, and not giving the impression of extreme collapse. She does not complain of thirst; since Saturday (22nd October), however, she has had slight occasional dimness of vision and lightness in the head.

The pulse is small, but of very fair tension and regular in force and rhythm, numbering 90 per minute. The tongue is quite clean, although the breath is still rather fœtid. Pallor is more marked on the face than on the lips, which are fairly coloured. The abdominal wall is relaxed, suggestive indeed of slight emaciation. No tenderness anywhere discovered, and no fulness or hardness at any point. The patient is quite decided that her gastric symptoms are only of four weeks' duration, and that, with the exception of the hæmatemesis on the 22nd, she had only vomited once before this, as described in Dr. Coats' report. She thinks that on this first occasion it was bile she vomited, from its bitter taste.

Digitized by Google

A detailed physical examination is impossible, but Dr. J. Lindsay Steven is of opinion that, as regards the hæmatemesis, the heart and lungs may be regarded as normal. She declares that she is not the subject of a chronic cough. She cannot blame anything for causing her illness, but her circumstances are rather poor.

The treatment then ordered was as follows. She was to receive absolutely nothing by the mouth except small pieces of ice occasionally. In the event of failure of the pulse, brandy *per rectum* was to be administered; one-sixth of a grain of morphia hypodermically if she were restless; and in the event of a recurrence of the hæmorrhage, Dr. Coats was instructed to practise subcutaneous injection of saline fluid to 1 pint.

25th October.—General condition very satisfactory. Pulse of very fair tension, the patient not being in any way collapsed. A fair amount of sleep during the night, and, except of debility, no complaint to make. This morning, in response to an enema, a large quantity of tarry material, partly formed, partly loose, was passed from the intestines. Nourishment by means of nutrient suppositories and enemata every three hours was commenced to-day.

She remained very well until 28th October, receiving nothing but small pieces of ice by the mouth. During the visit on that morning I witnessed an attack of hæmatemesis, in which 15 oz. of pure bright blood were evacuated. After this the patient was very collapsed, and she was treated by the administration of 20 minims of turpentine and half an ounce of brandy *per rectum*, one-sixth of a grain of morphia hypodermically, and the injection of 1 pint of saline solution subcutaneously.

During the afternoon of 28th October the patient had two additional hæmorrhages, amounting in one to 1½ oz., in the other to 4 oz., and saline injection was again practised in the evening.

3rd November.—The patient progressed very satisfactorily from the period of the last hæmatemesis until 1st November, having been fed during the whole period of residence entirely by the rectum. On 31st October a moderate diarrhœa set in, and on the 1st of November it had been determined at the visit to begin milk by the mouth in 1 drachm doses. Until this morning the bowels have been moved seven or eight times each day, the motions being normal in colour, but exceedingly offensive—without any tarry condition. A slight elevation of temperature also on the night of 2nd November

Digitized by Google

and morning of 3rd November (a maximum of 101·2° being reached) took place. During this period of fever and diarrhœa the pulse has ranged from 120 to 130.

There has been no return of hæmatemesis.

7th November.—Since above note patient has become progressively weak, and she died this afternoon. The diarrhœa mentioned above proved uncontrollable, laudanum and astringents having little effect on it. Latterly the bowels have been running practically constantly. The pulse has ranged between 120 and 140, but for two days has been sometimes imperceptible. A very offensive smell was exhaled from patient. Temperature rose to 100·6° just at death. Hiccough was present for about twenty-four hours before she died, but was not severe.

Summary of post-mortem examination.—The peritoneal cavity, as a whole, presented healthy characters. Examination of the peritoneal aspect of the stomach wall and of the pyloric and duodenal regions, both anteriorly and posteriorly, revealed no trace of abnormality. The œsophagus and duodenum presented quite healthy characters; the mucous membrane of the stomach also, as a whole, was quite normal in appearance. On the posterior surface, about 4 inches above the pylorus and 1½ inch below the lesser curvature, a very superficial abrasion, about a quarter of an inch in length and one-eighth of an inch in breadth, was discovered.

There was no thickening of the floor or edges of the abrasion, and no redness around it. In the middle of the abraded area two pin-hole openings were observed, through which a bristle was directly passed (as is now seen in the preparation) into one of the primary lateral branches of the gastric artery. This might very readily have been missed from the very healthy character of the mucous membrane surrounding it. Evidence of slight catarrh of the intestines was present, but no blood was found in them.

There was considerable œdema towards the bases of the lungs, and old fibrous adhesions over the lower lobe of right were present, but the other organs presented nothing abnormal, with the exception of great anæmia.

CASE II.—*Profuse hæmatemesis due to "pore-like" erosion of a branch of the left gastro-epiploic artery—Laparotomy—Death due to hæmorrhage, about 96 oz. of blood having been lost while under observation in the ward.*

W. S., 38, a vanman, was admitted to Ward 7 on the 17th April, 1898, on account of a severe vomiting of blood which

Digitized by Google

had suddenly come upon him while walking in the street, and apparently without warning of any kind. An ambulance attendant who saw the blood estimated its quantity at from two to three pints. He was much collapsed when admitted at 10 P.M., but was quite clear that the blood had been vomited and not coughed up, the evacuation having been preceded by distinct sickness.

On the morning of the 18th I made the following note:—

No further external hæmorrhage occurred from the time of admission until about 8 o'clock this morning, when he felt sick, and asked for the bedpan. Vomiting and movement of the bowels occurred practically simultaneously. The vomited matter consisted almost entirely of pure blood diluted somewhat with thin, watery mucous fluid, but coagulating rapidly into thin large clots. Vomiting occurred twice, with an interval of about half an hour, the total quantity being about 40 oz. The motion consisted of black, tarry-looking matter, and was probably about 2 pints in quantity; since this he has retched twice, but has not vomited. At the visit this morning, the patient is found to be pale and somewhat drowsy, the pupils being contracted, evidently the result of hypodermic of a quarter of a grain of morphia administered at the time of the hæmatemesis.

The tongue is pale, and coated with a buff coloured fur; the pulse is quick, small, compressible, numbering about 120 per minute. The heart sounds are feeble, only the second being easily heard; there is no murmur.

The chest is well formed, and no abnormality of the lungs is detected. It is not considered advisable to palpate the abdomen freely, but a superficial physical examination of the epigastric region reveals nothing abnormal, and the patient makes no complaint of pain on manipulation. On enquiry, one or two details of clinical history are elicited:—For some time past, he does not know how long, he has been occasionally liable to severe spasms of colicky pain in the bowels, each attack not lasting long. He said nothing to anybody about these attacks. During the week before admission he had been idle, and had probably been drinking more than usual. The hæmatemesis took place without warning whilst he was out walking with his brother. He is perfectly clear that he vomited the blood, and did not cough it up, and that the vomiting was preceded by a sense of sickness.

During this morning, since the vomiting, he has been somewhat restless, but has made no complaint of pain.

20th April.—The patient had remained fairly well till this

Digitized by Google

morning, when, at 8 A.M., 21 oz. of fluid blood were vomited. Careful physical examination of the abdomen was absolutely negative. The pulse remained of fair volume, but was easily compressible, numbering 110 per minute. Pallor is very great. Temperature subfebrile in character, ranging between 99° and 100°.

21st April.—During the day smaller quantities of blood had been constantly put up, and the total evacuated since yesterday morning at 8 A.M. is 43½ oz. Mr. Pringle saw the patient in consultation with me this forenoon, and it was agreed then that if further evacuation of blood occurred operation should be undertaken, with a view, if possible, to securing the bleeding point or surface. One ounce of blood was brought up about 4 P.M., and at 8 P.M., in my presence, Mr. Pringle performed laparotomy, examining the stomach externally, and, after opening it, exploring the interior with the finger, but nothing could be found. The transverse colon was distended and dark-looking, apparently from blood in its interior. The patient died about an hour and a half after the completion of the operation. The total amount of blood vomited during residence in Ward 7 was 96 oz., in addition to a number of tarry motions.

On 22nd April, 1898, I was present while Mr. Pringle performed a *post-mortem* examination, and his description of the stomach is as follows:—There is a sutured wound in the anterior wall of the stomach, about 1½ inch from the pylorus. The stomach is empty. About 2 inches to left of the wound, 3½ inches to 4 inches from the pylorus, and 1½ inch up from the greater curvature is a small depressed area about the size of a threepenny piece. In the centre of this area an oblique opening into a vessel (a large branch of the left gastro-epiploic artery) is seen, into which a bristle can be passed 2 inches in one direction and 1 inch in the other. There is no thickening of the stomach around the depression, and the serous coat over it is absolutely natural in appearance. The other abdominal organs presented healthy characters. The depressed area scarcely deserved the name of an ulcer. It was a mere superficial abrasion, which might altogether have been overlooked had it not been for a minute blood-clot adhering to its surface. With this exception the mucous membrane of the stomach presented quite healthy characters.

The medical treatment adopted in this case was precisely similar to that adopted in Case I, with this exception that subcutaneous injection of saline solution was not practised.

The occurrence of the two cases which I have just described,

Digitized by Google

and the specimen from the first of which I have demonstrated, made a profound impression upon my mind, chiefly on account of the minuteness of the lesion capable of producing such disastrous results. That such a lesion may not be at all an uncommon one I can well believe, but that it has not been very frequently described is at once apparent from a glance into the literature of hæmatemesis. In consulting the various accounts of profuse and fatal bleeding from the stomach which were available to me, I find a certain number of cases on record in which no lesion could be found at the *post-mortem* examination, the mucous membrane of the stomach being regarded as healthy. Now, it is quite possible that in such cases there may have been a minute pin-hole opening of one of the arteries which had escaped notice. In certain other records, to the titles alone of which I have been able to obtain access, I judge that the lesion giving rise to the hæmorrhage was of a nature precisely similar to that I have been describing in this lecture. Thus, Chiari, of Prague (*Prag. Med. Wochenschr.*, 1882, vii, 489), describes a case of fatal hæmatemesis under the following heading:—"Fatal bleeding from the stomach resulting from the erosion of a submucous vein within an abrasion of the mucous membrane only the size of a large barleycorn." Again, Ferrand (*Bull. et Mem. Soc. Med. d. hôp. de Par.*, 1895, 3, S. xii, 309-312) describes a case of "abundant hæmatemesis without ulcer properly so-called," a mode of description perfectly applicable to both of my cases. In the *Pathological Transactions*, 1870, vol. xxi, p. 162, Dr. Murchison described two cases of fatal hæmatemesis from very minute ulcers perforating a small artery in the coats of the stomach. Dr. Murchison writes with regard to them—"They are remarkable, not only for the minuteness of the ulcers, which were little more than hæmorrhagic erosions, but also for the absence of the usual symptoms of ulceration of the stomach. Neither of the patients had suffered from vomiting prior to the occurrence of the hæmorrhage." But, beyond all doubt, one of the most important communications on this very serious lesion is that by Dieulafoy in the *Bulletin de l'Academie de Médecine*, 3e serie, tome xxxix, 18th January, 1898, p. 49, entitled "Exulceratio Simplex." The paper contains an account of seven cases which are similar in all essential details to those I have brought under your notice. Two of the cases were under his own care, and one was saved by opening the stomach and securing the bleeding point. In both of these cases he had expected to find the simple ulcer of Cruveilhier; he *had* found only an exulceration, more or less extensive and exceedingly

Digitized by Google

superficial, which had penetrated an artery by an opening sufficient to allow a pin to be introduced. Two of the seven cases were subjected to careful histological investigation by Dieulafoy's assistants, and the details will be found in the paper. It is sufficient to indicate that only the mucous membrane and the muscularis mucosæ were involved in the abrasion, which did not involve, except very partially, the submucosa, and that in one case the perforated artery was found to be quite healthy. Small miliary abscesses were detected in the neighbourhood of the abrasion, which Dieulafoy regarded as the initial stage of the lesion. As regards diagnosis the lesion was to be distinguished, in his opinion, from tubercular, syphilitic, and typhoid ulceration; and while proposing the name "exulceratio simplex," Professor Dieulafoy writes that as regards the essential nature of the lesion he regards it as the initial stage of the simple ulcer of Cruveilhier.

I shall conclude this lecture by making a few observations upon certain practical points bearing upon the diagnosis and treatment of the lesion I have been describing.

As regards diagnosis, the first point to be commented upon is the exceedingly profuse character of the hæmorrhage, which in both of our cases from the first threatened the lives of the patients; and, in the second, may be said to have been the primary cause of death. That such exceedingly profuse hæmorrhage may occur in the simple perforating ulcer cannot be doubted; but, on the whole, I think it is not so likely to occur, as the morbid condition of the tissues in the wall of the round ulcer is more likely to induce a thrombosis, which may either prevent the hæmorrhage altogether, or, when it does occur, may more readily lead to its arrest.

The second point of diagnostic importance is the comparative absence of antecedent gastric symptoms. That this also may be characteristic of the development of the round ulcer cannot be doubted; but in most cases a careful enquiry will reveal the existence, usually during a considerable period of time, of some of the symptoms of round ulcer. In our second case it may be admitted that these were entirely absent; in the first, gastric symptoms had only been present for four weeks altogether, and became urgent for the first time about a week before the first hæmorrhage. Further, it can hardly be said that the symptoms detailed in the clinical history were characteristically those of the round ulcer.

Hæmorrhage, sometimes of a very profuse kind, from the stomach may result from the presence of malignant ulcers,

Digitized by Google

from hyperæmia due to portal obstruction arising from cirrhosis of the liver, or from varicose veins of the stomach. As regards the two former conditions, difficulties of diagnosis are not likely to be great; as to the latter, I have no personal experience, but I should think that the difficulties of detecting the true source of the bleeding during life would be considerable.

With regard to the nature of the "pore-like" erosion of the gastric vessels which has been made the subject of this lecture, I am very much inclined to agree with Dieulafoy in thinking that the lesion is probably the initial stage of the simple round ulcer of Cruveilhier.

The treatment of the condition must always be a matter of the gravest concern to the physician. Our first case shows, I think, that under medical measures the bleeding may be arrested. But possibly this may be effected only when the vital powers are so exhausted that the ultimate recovery may for long be a matter of doubt. So it happened in our case. No doubt surgical interference with the view of securing the bleeding point would be the best method of dealing with such cases; but even here the result must often be problematical. To be of service the operation must be done early, and sometimes this is not possible. But perhaps a greater difficulty is the uncertainty of finding the bleeding point when the stomach is opened. Our cases show that the lesion is not one which is liable to occur in any particular region of the viscus, and this still further increases the difficulties in the way of a successful result. However, Dieulafoy has had one successful result, and I must say that if a case similar to the second reported in this lecture were to occur to me again, I would recommend an operation at the earliest possible date.

Mr. H. E. Clark said that the cases were of great interest from the operative point of view, but increased the difficulties of the subject. The lesson to be derived from them was that if no ulcer were found after opening the stomach, the operator should explore along the line of the main arteries. This, however, would be a matter of extreme difficulty, considering how difficult it was to see the erosion at the autopsy. The artery lay in the stomach wall, and the peritoneum, &c., would have to be cut through. Dr. Steven had described and defined the site of a new form of hæmorrhage.

Dr. Workman had recently seen appearances precisely similar to those which Dr. Lindsay Steven had described in quoting from Dr. Murchison. He thought them a very early stage of gastric ulcer. There had probably been at one time a

Digitized by Google

superficial ulcer, leaving the wall of the artery bare and weakened. The condition, he thought, was analogous to that of aneurysm of the branches of the pulmonary artery.

Dr. Alex. Robertson was surprised that Dr. Steven had referred to the condition as extremely rare. He had read of cases which were characterised by an extreme paucity of symptoms.

Dr. W. G. Dun asked how Dr. Steven carried out the procedure of subcutaneous injection of normal saline solution.

Dr. Adamson inquired as to the etiology of the condition. An ordinary gastric ulcer must begin somewhere. It was quite possible that it might begin over a vessel, and that the "pore-like" erosion might therefore correspond with a very early stage of gastric ulcer.

Dr. Middleton was under the impression that such cases were very rare.

Dr. J. Lindsay Steven replied to Dr. Dun that his method was to use a hollow needle attached to indiarubber tubing, to the other end of which a funnel was affixed. After the skin had been washed, the saline solution (1 drachm of salt in 1 pint of water), at a temperature comfortable to the hand, was introduced. He had practised the injection in the arm, but it was better done in the thigh, where there was more subcutaneous tissue. The immediate result was to improve the patient's pulse. He thought Dr. Adamson's suggestion very feasible.

IV. — MULTIPLE TUBERCULAR TUMOURS OF THE BRAIN — ENLARGEMENT OF THE RIGHT CRUS CEREBRI — GREAT ATROPHY OF THE RIGHT THIRD NERVE.

BY DR. J. LINDSAY STEVEN.

J. A., æt. 7, schoolboy, was admitted to Ward 7 of the Glasgow Royal Infirmary on 20th July, 1898, complaining of drooping of right eyelid and weakness of left arm and leg. He was a puny, delicate boy, illegitimate; his mother being a little unhealthy-looking woman. Two years ago he suffered from measles.

The drooping of the right eyelid was first noticed four months before admission, after he had been struck on the eye by a piece of coal thrown at him by a playmate. Three weeks before admission the left arm became weak, and eight days later dragging of left leg was first noticed.

Digitized by Google

At the time of admission, there was almost complete ptosis on the right side; dilatation of right pupil; inability to move the eye towards the middle line; a peculiar high-stepping action of the left leg and foot in walking, and a spasm of the left arm and hand rather suggestive of athetosis. It was noticed that he never attempted to use the left hand, and had a habit of keeping it hidden under the bedclothes. With right hand the dynamometer registers 13 kilos.; with the left, 10 kilos.

The peculiarity in walking is probably due to drooping of the left foot.

On more careful examination of the eye, it became clear that the whole right third nerve was paralysed, the only movements performed being those of the external rectus and superior oblique. The right pupil, though distinctly dilated, still contracted to light stimulus. No facial and no hypoglossal paralysis.

Over left hip there were two very evident patches of scrofuloderma verrucosum.

Heart and lungs normal, and no enlargement of liver or spleen can be made out.

A diagnosis of multiple tubercular tumours of the brain, with involvement of the right third nerve, was made, and the progress of the case during residence lent support to this view. Progressive emaciation set in; sickness and vomiting became frequent after he had been six weeks in the ward, and about the same time paralysis of the left side of the face was observed. Distinct atrophy of the left arm took place, and the tendon reflexes both in the left arm and leg became exaggerated.

In the month of October, slight clonic convulsions in the right arm and leg, and tonic general convulsions supervened.

He died comatose on 27th October, 1898. The temperature, which had been practically normal during the whole residence, rose a few points a day or two before death.

At *post-mortem*, in addition to general miliary tuberculosis, numerous caseating tubercular tumours of the brain were discovered—the smallest the size of a hazel-nut. One was situated in the right side of the pons; a second in the right lobe, and a third in the left lobe of the cerebellum. A fourth nodule was found in the substance of the right crus cerebri; it had caused great enlargement of this structure. The right third nerve, evidently from the pressure exerted on it by the enlarged crus cerebri, was much diminished in size, being not

Digitized by Google

more than one-third of the thickness of the nerve on the other side. All these tumours are well shown in the specimen exhibited.

Dr. Middleton said that as many tumours might be found as in this case, and yet there might be no head symptoms at all. He mentioned a case in support of his statement.

V.—A CASE OF CIRRHOSIS OF THE LIVER IN A CHILD SIX YEARS OLD.

BY DR. HUNTER AND DR. WORKMAN.

Cirrhosis of the liver in children is a rare condition. It is stated in the *Treatise on Children's Diseases*, edited by Professor Grancher, published last year, that in all medical literature there are records of no more than 130 cases, and that Dr. West had only seen 4 cases in 70,000 sick children examined by him. In view of these statements, I think we need have no hesitation in bringing this case before the Society to-night.

A. C., a boy, 6 years old, was admitted into Ward 8 of the Royal Infirmary on 19th September, 1898, in a moribund condition, and he died two and a half hours after admission.

His illness seems to have dated from about two months before this time, when the parents observed that the abdomen was swollen and that the skin had a yellowish colouration. A little later diarrhœa set in, with from three to four motions in the twenty-four hours. The diarrhœa continued more or less constantly during the two months' illness, and the abdomen gradually increased in size; but the jaundice disappeared after three or four days' duration.

On 13th September, *i.e.*, six days before admission, the patient was sick and vomiting, and he complained of headache. During the next few days the swelling of the abdomen rapidly increased, the breathing became much embarrassed, and it was quite evident to the parents that their child was very ill.

When admitted to hospital, the child, as has been said, was dying. The face was pale, lips cyanosed, superficial veins distended. The respirations numbered 46, the pulse 130, the temperature registered 99° (rectum). The abdomen was greatly distended, and evidently contained a large quantity of fluid. Both liver and spleen were enlarged, each projecting for a considerable distance below the costal arch. Noisy râles were to be heard all over both lungs, and there was dulness with

Digitized by Google

bronchial breathing at the left base behind. The whole aspect of the patient was that of one with chronic valvular disease of the heart; but examination of that organ revealed no evidence of heart disease. The sounds, though short and sharp, were quite pure, and the precordial dull area was not increased. The diagnosis, therefore, arrived at was that of tubercular peritonitis, with tuberculous infiltration of both lungs. But this diagnosis was only provisional, as it did not satisfactorily account for the great enlargement of the liver and spleen, which is seldom so marked in cases of tubercular peritonitis. The true diagnosis, that of cirrhosis of the liver, was not made till after the patient's removal to the *post-mortem* room.

Summary of post-mortem examination.—The body was much emaciated, and there was almost complete absence of adipose tissue. The heart (4 oz.) presented healthy appearances. There was a fresh fibrinous pleurisy on the left side, and the lower lobe of the left lung was consolidated in the stage of red hepatisation. The right lung was congested and œdematous. The spleen (9½ oz.) was greatly enlarged and congested. The liver (23 oz.) was markedly irregular in contour and nodulated. Its right lobe was enlarged; but the left lobe was greatly atrophied, very dense, and looked just like an appendix to the right. On section the organ had much the appearance seen in cases of acute yellow atrophy, the lobules being stained with bile a deep yellow colour. The gall-bladder contained fluid bile. The kidneys (4 oz. each) were much congested. The mesentery contained but little fat, it appeared thickened, and its lymphatic glands were enlarged and caseous. There was marked mucous catarrh of the colon, but the stomach and small intestine presented healthy appearances.

Microscopic examination of the liver showed a pronounced cirrhosis, mostly of the multilobular type, though in places also monolobular. The cirrhosis was most marked in the left lobe, where the glandular tissue was almost completely replaced by inflammatory new growth and vessels. Sections stained with thionin, when examined with one-twelfth oil immersion lens, were seen to contain numerous groups of micro-organisms lying between the columns of liver cells. These micro-organisms appeared to be short, thick rods, and sometimes—probably from irregular staining—as diplococci. The appearances they presented corresponded closely to those of the bacillus coli communis, as recently described by Professor Adami in his cases of cirrhosis of the liver. A similar organism was likewise to be seen in sections of the lungs and kidneys. No culture was taken from any of the organs.

Digitized by Google

In the light of this *post-mortem* examination, then, the whole case becomes as clear as possible, for the signs and symptoms the patient presented were really those of a typical case of cirrhosis of the liver. We had the gradual swelling of the abdomen, the ascites, diarrhœa, the temporary jaundice, enlargement of the liver and spleen, the cyanosis and involvement of respiration. On questioning the parents, too, it was found that the child in the course of his short life had consumed considerable quantities of alcohol. It seems that when a baby he had bronchitis, and was treated with teaspoonful doses of whisky. He then learned to like the drink, for at any time during the past five or six years that the parents were refreshing themselves (and this seems to have been a not unfrequent proceeding), the child seldom failed to claim his share, and, as the father says, it was seldom he was refused a "little drop." It seems sufficiently clear, therefore, that the amount of alcohol consumed was by no means inconsiderable.

Other than this, no cause can be found to account for the cirrhosis. The only other ailments the patient had suffered from were measles three years ago, and whooping-cough four years ago. He had never been a strong boy, but he was able to go to school, and, indeed, he attended school till six days before his death. There is nothing in the family history to suggest syphilis. The father and mother are alive and well, and they have four other children all fairly healthy.

That alcoholism was the cause of the cirrhosis in this case is by no means certain. Pathologists are still in doubt as to the etiology of cirrhosis of the liver. But the association of alcoholism and cirrhosis is so frequent as at least to suggest some causal relationship between the two. It may be that the alcohol lowers the vitality of the tissues, and thus renders them less able to resist the invasion of pathogenic micro-organisms. The bacillus coli communis, as we know, is an organism seldom absent from some of the abdominal organs, and it seems reasonable to suppose (as Professor Adami suggests) that it is the cause of the cirrhosis. In our case micro-organisms were found in the lungs and kidneys as well as in the liver, showing the infection (if such it be) to be more or less generalised. That the liver should suffer more than the other organs in this infection is, however, by no means strange, as the relationship of the liver to the portal circulation will make it subject much more than the other organs to the ill-effects of chronic alcoholism. But these as yet are little more than surmises, and the true cause of cirrhosis of the liver is not yet certainly known.

Digitized by Google

Dr. J. Lindsay Steven had seen two typical cases in children under 6. One of them presented appearances similar to those of acute yellow atrophy.

VI.—HYPERTROPHY OF FINGER-NAIL.

BY DR. EDINGTON.

The specimen represents the terminal phalanx and nail of the left ring finger.

A longitudinal fissure divides the nail into radial and ulnar portions, the former being rather more than half the breadth of the nail. There is very considerable transverse arching of the nail, so that the ulnar portion looks directly towards the minimus finger; the radial portion occupies a dorsal and partly radial position.

The radial portion passes forwards and upwards from the bed, and then arches downwards, projecting 1·5 cm. beyond tip, and 1·25 cm. above the end of the finger. This portion of the nail is nearly 0·6 cm. thick, and at its free extremity measures transversely nearly 0·9 cm. Viewed dorsally, it appears narrower nearer the finger, but this appearance is due to the transverse arching mentioned above.

The ulnar portion is at first flat, and lies in the vertical plane. Running along for 1·25 cm. its surface is somewhat broken, and in the remainder of its course it turns transversely outwards beneath the radial portion. This transverse part is curved round the soft tissues below the nail, and does not project beyond the distal extremity of the digit. It is more ridged than the proximal part of the nail. Viewed from the radial side, the free extremity of the ulnar portion is seen

Digitized by Google

between the soft tissues of the bed and the under surface of the radial portion, and between it and the proximal part of the radial portion is a bud of granulations.

The specimen is from a case of Dr. Hector Cameron's, in which many years ago the matrix was injured. As a result, hypertrophy of the nail, accompanied by ulceration, ensued. Avulsion of the nail was performed about three years ago, but was succeeded by equally faulty nail-formation. On account of the inconvenience caused to the patient by the condition, the terminal phalanx was amputated by Dr. Cameron.

MEETING VI.—16TH DECEMBER, 1898.

The President, DR. G. S. MIDDLETON, *in the Chair.*

I.—TWO CASES ILLUSTRATING THE DURATION OF GENERAL PERITONITIS AFTER THE RUPTURE OF A PERFORATING ULCER OF THE STOMACH AND OF THE DUODENUM RESPECTIVELY.

BY DR. J. LINDSAY STEVEN.

The specimens which I show you to-night are typical examples of the round ulcer of the stomach and duodenum, each of which had ruptured and caused a fatal peritonitis. I also present for comparison with them the specimen of "pin-hole" erosion of the gastric artery which I showed at the last meeting of the Society (see p. 238). It is not, however, to illustrate either the pathology or the clinical phenomena of Cruveilhier's round ulcer that I direct your attention to these specimens to-night. I have a more practical object in view—namely, to demonstrate the exact length of time which may elapse between the period of *complete* rupture of the ulcer and the fatal issue from the resulting general peritonitis. In the first case death took place exactly twenty-five hours and a half after the occurrence of complete perforation; and in the second the patient died about twenty-one hours, at the most, after the first onset of pain. From this point of view the cases are of great practical importance with reference to the surgical treatment of perforated gastric ulcer.

Digitized by Google

CASE I.—*Gastric ulcer, in which death took place twenty-five hours and a half after the occurrence of* COMPLETE *perforation, with evidence of* PARTIAL *rupture having occurred at least twenty-four hours before the onset of general peritonitis.*

Agnes G., 19, domestic, was admitted to Ward 8 on 23rd November, 1898, complaining of pain in the epigastrium of about two days' duration. She dates her stomach symptoms to a period about six months before her admission, previous to which she had always been quite healthy. During this time her complaint was not of pain, but rather of a feeling of sourness after her food. The sourness was felt about ten minutes after a meal, and was shortly followed by vomiting. This occurred more or less after every meal she took, the vomited material being the food practically unchanged. She never saw blood in the vomit, which was likewise never coffee-ground in appearance; and she could not say that she had ever seen blood in the motion of the bowels, although she admitted that they were sometimes dark in the colour. Her appetite was all along rather poor; she took the ordinary food of the house, and she never thought it worth while to consult a doctor.

She was certainly not feeling worse than usual at the time of onset of the acute symptoms.

On Monday, 21st November, immediately after a meal consisting only of tea, bread and butter, partaken of in the evening, she was seized with pain in the epigastrium. It was not very acute, but kept her from sleeping for about two hours after she went to bed, which she did at the time the pain began. She was quite free from it in the morning, and went about the during the whole of Tuesday, the 22nd November, feeling quite well in her general health, but with no appetite. On the evening of Tuesday, about 8 P.M., after taking a meal of tea and bread and butter, the pain recurred. It was much more severe, however, and kept her from sleeping the entire night. A medical man saw her on Wednesday, 23rd November, at 10 A.M., who ordered hot fomentations, and recommended her removal to the Royal Infirmary from Cambuslang, a distance of 4 miles, where she arrived about 2·15 P.M.

She never had any illness until that just described. Her menstruation had always been perfectly regular from the age of 17. She had been in service, but for nine months before admission had been entirely engaged in managing her father's house. She had always had good food.

On my receiving days at the Infirmary I am frequently in

Digitized by Google

the habit of visiting my wards in the afternoon or evening. On the afternoon of the 23rd November I paid a visit shortly after four o'clock, and when about to leave, after having seen one or two urgent cases, my attention was directed to this patient, the gravity of whose condition, owing to great pressure of work during the afternoon, had not apparently been previously fully recognised.

I saw the patient at 5·30 P.M., when it was at once obvious to me that she was suffering from general peritonitis. Her face was pale; the expression somewhat anxious. The decubitus was dorsal, but the knees were not drawn up. At this time she made no urgent complaint of pain; indeed, she was somewhat drowsy, and inclined to doze. The pulse was small and thready in character, numbering about 140 per minute; the respirations were shallow, numbering 64. The pupils were moderately dilated and equal. On exposing the abdomen, moderate, but quite obvious, distension of the abdominal wall was at once apparent. The distension was not uniform, there being a transverse depression an inch or two above the level of the umbilicus, below and above which dilatation of the abdominal wall was very obvious. Percussion was everywhere tympanitic, and on any but the most gentle palpation extreme tenderness was complained of. The hepatic dulness could not be differentiated. The urine was normal.

The possibility of gastric perforation at once suggested itself to me, and the patient was removed from the sideroom, in which she had been placed on admission to the general ward, so that she might be under more continuous observation. At the time of my visit the patient was so ill, and the history of a complete perforation having occurred almost twenty-four hours before so clear, that immediate surgical interference did not recommend itself to me. Hot applications and stimulation were recommended, and instructions were left that I should be informed in two hours of her condition. At the end of this period, however, she was so ill that all question of surgical interference had disappeared, and she died at 9·35 P.M.

Summary of post-mortem examination, which was performed by Dr. Charles Workman, on the morning after death:—

Heart and lungs normal. Liver is slightly enlarged, and shows considerable fatty change. The omentum and loops of bowel are adherent by abundant fresh fibrinous deposit, and the peritoneal cavity contains a quantity of very sour-smelling yellow fluid, which has evidently escaped from the stomach

Digitized by Google

through a rounded opening the size of a threepenny piece, which was at once visible on raising the left lobe of the liver. In the anterior wall of the stomach, about midway between the œsophageal opening and the pylorus and close to the upper curvatnre, there is a round perforating punched-out ulcer, the opening in the mucous coat being wider than that in the muscular coat, and this wider than the opening in the serous coat. Through the opening, the escape of material from the stomach has occurred. The spleen, the pancreas, and the kidneys were normal.

I may also add that the appearance of the peritoneal surface, for about an inch around the perforation, was suggestive of recent adhesions having been formed between the stomach wall and the under surface of the left lobe of the liver. The first attack of pain on Monday, 21st November, was probably due to a partial rupture of these, and one cannot help thinking that under appropriate treatment the final rupture might have been avoided and general peritonitis averted.

CASE II.—*Ulcer of the duodenum, proving fatal from general peritonitis, twenty-one hours after the occurrence of perforation.*

The patient was a nurse-probationer in the Glasgow Royal Infirmary, aged from 25 to 30. Although complaining at times of indigestion for some time before her death, this had never been so severe as to cause her to seek medical advice. On Saturday evening, 9th September, 1893, at twelve o'clock, after holding a fractured limb, which was being set by the house-surgeon, she suddenly complained of severe pain in the abdomen, and had to go off to bed. The house-surgeon of her ward saw her, and regarding her symptoms as probably those of constipation, ordered castor oil and fomentations. On the Sabbath morning, the pain was still severe, and she kept bed, fomentations being continued. At this time I was acting as physician to the nurses of the Infirmary, but was not informed of the case during the day. About 8·30 P.M., however, as the patient had become very weak, I was sent for, and arrived at 9 P.M., to find that she had just died before my arrival. On Tuesday, 12th September, I made a *post-mortem* examination, of which the following is a report:—

External appearances.—The body is well nourished. Rigor mortis firm; *post-mortem* lividity well-marked on back, and in fingers and toes. Pupils moderately dilated and equal. The abdomen is slightly enlarged, and very tense. On cutting through the linea alba, gas escapes with an explosive noise,

Digitized by Google

and on laying open the peritoneal cavity, it is found to contain a considerable quantity of brownish-coloured fluid, in which are floating many large globules of oil. The whole of the intestines are covered with a smooth layer of green-coloured fibrin, which mats the loops of intestine together, and has fastened down the great omentum over them like an apron. Continuous with the smooth adherent omentum, the outline of the anterior portion of the stomach is made out, and in the region of the pyloric aspect of the organ a large opening, with clean, sharp edges, is observed. The opening is in area the size of a threepenny piece, and from it issue the contents of the stomach. Whether this ulcer is within or without the ring of the pylorus cannot be determined from without. On removing the stomach, and laying it open along the lesser curvature, the ulcer is found to be in the duodenum, just outside the ring of the pylorus. It is not quite circular in shape, but its edges are clean, and tolerably sharp. The tissues around this ulcer are thickened from infiltration, and the duodenal opening has led into a cavity, which has evidently gone on getting deeper and deeper, until nothing but the layer of peritoneum has been left. The perforation has been due to the sloughing of this layer.

The gastric mucous membrane is healthy in every part, and of a normal pink colour. The viscus contains half-digested milk in considerable quantity.

The cæcum and appendix are healthy. The amount of peritoneal fibrin in the pelvic region is astonishing, considering the short duration of the disease.

Uterus, ovaries, and Fallopian tubes present quite healthy appearances, but their peritoneal surfaces are covered with fibrin.

The kidneys and liver are healthy, as are also the heart and lungs. The lungs especially are remarkable for their non-pigmented character and their healthy consistence throughout.

What especially struck me in both of these cases was the excessively severe character of the peritonitis, and the general character of the matting of the intestine which had taken place. The principal lesson the cases teach is, that after twenty hours from the occurrence of complete perforation with discharge of gastro-intestinal contents into the general peritoneum, surgical interference must be almost, if not absolutely, hopeless.

Digitized by Google

II.—RUPTURED GASTRIC ULCER—SUTURE.

BY DR. RUTHERFURD.

The specimen showed a healed puckered area in the anterior wall of the stomach close to the lesser curvature, and within 2 inches of the lesser curvature; extending downwards from this on the posterior wall was an ulcerated surface about an inch in diameter, in which another perforation had taken place.

The patient was a young woman of 26, who had for the last eight or nine years suffered from pain after meals, relieved by vomiting. In 1890, and again in the spring of 1898, she was under treatment in the Royal Infirmary on account of this, on the latter occasion under the care of Dr. Lindsay Steven. There was never any hæmatemesis until about ten days before the occurrence of the perforation, during which time, although continuing at her work, she would seem to have vomited a good deal of blood.

On 8th September, about 1 P.M., at the end of an attack of vomiting, she suddenly felt pain in the epigastrium, which gradually became more wide-spread, and she passed into a state of collapse. This was somewhat relieved by the administration of 40 minims of laudanum about 3·30 P.M. She was thereafter sent into the Royal Infirmary under the care of Dr. W. K. Hunter, at whose request Dr. Rutherfurd saw the patient, and proceeded to operation at 9 P.M. (eight hours after the onset of symptoms).

A rather scanty extravasation of watery stomach contents was found, with some reddening of the peritoneal surface, in the upper half of the abdomen. The rupture, which admitted the tip of the little finger, was with difficulty brought within reach, partly because of its position, close to the lesser curvature and about 2 inches from the cardia, but also from the existence of old fibrous adhesions between the stomach and diaphragm. The ulcer was in the midst of an area of leathery induration of the wall, which was difficult to fold in, and in which stitches easily tore through.

The cavity of the abdomen was washed out with hot saline solution, some of which was allowed to remain behind, and a glass drainage-tube was passed down into the pelvis.

After the first twenty-four hours the temperature was persistently above normal, 100° to 101°, and there was discharge of pus from the wound. It was found possible to keep the bowels acting by means of enemata, and to this

Digitized by Google

great care was given. On 28th September, three weeks after the operation, patient had a rigor, after which she gradually collapsed, and died about six hours later.

Post-mortem, very extensive suppurative peritonitis was found in the flanks and under the diaphragm. There was also a recent perforation, as described, in the posterior wall, and extravasation into the lesser sac. While it is possible that this second perforation may have been the cause of the sudden termination of the case, Dr. Rutherfurd was not inclined to think that it was the source of the general infection of the peritoneum, the changes in the lesser sac being comparatively slight compared to what were found in the pelvis and under the diaphragm.

Dr. W. K. Hunter said—The diagnosis of perforation of a gastric ulcer is, as we have just seen, sometimes extremely difficult, but in the case we are now considering this was not so, the history of the illness being so clear as to make the diagnosis comparatively easy.

The patient had been under observation for many years, for when admitted it was found that she had been in the ward twice before. The *first* admission was as far back as *October, 1890*, when she was complaining of pain in the stomach and vomiting after food, the symptoms having been present more or less for over a year. The patient improved very much while in hospital, and was dismissed three weeks later quite well. After this she remained well, except for a few attacks of pain in her stomach, *till August, 1897*. She had at this time to leave off work for three months owing to a return of the old symptoms, but after the three months' rest she was able to go back to her situation, feeling quite well. She remained well, except for occasional attacks of dyspepsia, till *last April*, when she was again admitted into Ward 8. She was now very anæmic (red corpuscles, 3,200,000; hæmoglobin, 15 per cent), and it was thought that the gastric trouble was mostly due to the anæmia, for at no time had there ever been hæmatemesis or blood in the motions, and no distinct tenderness could be made out in the epigastrium. Patient was dismissed about a month later, feeling perfectly well.

Nothing more was seen of her till 8th September, when she was admitted, about 5 P.M., in a very urgent condition. It seems that for about ten days previous to this she had been suffering from pain after food, with vomiting of brownish material—the first history of hæmatemesis. At 1 P.M. on day

Digitized by Google

of admission, at the end of an attack of vomiting, she felt sudden acute pain in the epigastrium, so severe as almost to cause her to faint. The pain gradually increased in extent, and at 3·30 P.M. it was felt all over the abdomen, and the patient was very much collapsed. Forty minims of tr. opii were administered.

When admitted into the ward (at 5 P.M.) she was still collapsed, but seemed under the influence of the opium, for the pupils were much contracted. She lay with the knees drawn up, and seemed to be suffering pain. Temperature was 97°, pulse 100, respiration 40. The abdomen was tender to the touch, and quite flaccid; there was no diminution of hepatic dull area.

The patient was pretty much in this condition when I saw her shortly after 7 o'clock, and although the physical signs were not marked, yet remembering that these might be masked by the opium, and taking account of her former history and the clear story of the sudden onset of the pain, there seemed little doubt as to its being a case of perforated gastric ulcer.

I shall read you the note I made at this time:—During the time which elapsed between admission and the operation patient was examined several times, and the most marked feature in the case was the more or less complete absence of abnormal physical signs. The pulse remained about 100, and was of good volume and quite regular. Temperature at 8 P.M. in rectum, 101°. The abdomen was neither retracted nor distended; it was slightly hard to palpation, giving the impression that the patient was contracting the muscles to avoid pain. There was slight generalised tenderness to the touch, but no acute pain. Percussion note over the abdomen may be described as dull tympanitic. There was no definite evidence of diminution of liver dulness.

Dr. J. S. M'Kendrick said that the mortality in cases operated on within twelve hours was 35 per cent, between twelve and twenty-four hours 75 per cent, and later 84 per cent. Early diagnosis was of cardinal importance. The onset of gastric ulceration was often insidious, and physical signs were not infrequently absent. The pain of perforation was sometimes localised over the appendix and the right iliac region.

Dr. Ritchie referred to a case in which there was doubt as to the existence of malignant disease. There had been no operation. *Post-mortem* a small ulceration was found in the cardiac end of the stomach, and an artery which had been

Digitized by Google

plugged had undergone digestion by the gastric juice. In a second case which he had seen there had been symptoms of perforation, but upon examination pus was found in the liver.

Dr. Carstairs Douglas said that in duodenal ulcer there were often very few symptoms during life.

Dr. Middleton had had little experience of ruptured gastric ulcer, and had not diagnosed the condition during life. He referred to a case which he had already recorded.

Dr. Adamson asked about the occurrence of shoulder pain.

Dr. J. Lindsay Steven replied that he had no knowledge of shoulder pain in either of his cases. Symptoms might often be latent, especially in cases of pin-hole erosion. He would expect the pain to have its seat nearer the site of perforation than the right iliac fossa. The element of time was of the utmost importance in operation.

III.—MYCOSIS OF THE LARYNX, WITH NOTES OF A CASE.

By DR. A. A. GRAY.

The following case is perhaps worth putting on record, as it appears to be in some respects unique:—

W. B., æt. 32, married, consulted me on 10th November, 1897, for hoarseness of many years' duration, and dryness of the throat and a tired feeling after speaking of some months' duration. He suffered from a slight attack of rheumatism ten or twelve years ago, but seems to have recovered without any sequelæ. Otherwise his previous history is good; there is no evidence of syphilis; he has always been very temperate in his use of alcohol, and for the last four years has abstained entirely. There is no history of loss of weight; indeed, during the last two years he has gained 7 lb. There is a slight tendency to constipation. There has been no cough at all.

The family history is not very good. There were originally ten of a family, but of these five only are left; the rest died young, one from "water in the head." The father died from "lock-jaw."

On examination, the pharynx is seen to be somewhat reddened. The left side of the larynx is swollen generally, and particularly in its posterior portions and along the aryteno-epiglottidean fold. The swelling is most marked over the left arytenoid cartilage, and over the upper part of this swelling there is a small greyish-white surface about the size of a split pea, and like a small ulcer in appearance.

Digitized by Google

The left cord is quite fixed. The right side of the larynx is normal in appearance.

On examination of the chest nothing abnormal is found. The urine is healthy.

In spite of the fact that the laryngeal appearance was exactly that of tubercular disease, I hesitated to pronounce it such, because (1) there was no cough at all; (2) there were no physical signs of any disease in the chest, nor was there any reason to suppose he was suffering from phthisis, which, though not always, in the great majority of cases precedes laryngeal tuberculosis; (3) there was no loss of weight.

A definite prognosis was not given, but I extracted a small piece of tissue from the swollen part with forceps in order to examine it for the tubercle bacillus. On the possibility of the affection being syphilitic, iodide of potassium was prescribed. As a local application the patient was ordered inhalations of terebene.

Cover-glass preparations were made from the piece of tissue removed from the larynx, and stained for the tubercle bacillus by the Ziehl-Neelsen method. No tubercle bacilli were found after a searching examination, but a remarkably large number of leptothrix filaments was found.

The patient returned on 8th November, 1897, and appeared to be in good general health. A careful examination was again made of his chest, but no signs of disease could be detected. On examining the pharynx and naso-pharynx there was no sign of mycosis.

The larynx presented almost exactly the same appearance as before. A piece of tissue was removed again, put in an agar tube, and sent up to the Western Infirmary, when Dr. Ferguson kindly made an attempt to cultivate it, but the attempt was unsuccessful, as, indeed, is usually the case with this organism.

On this visit the patient stated that his hoarseness was a little better, but I could detect no improvement myself. I felt justified, however, in giving him a good prognosis in regard to his health, but a poor one as regards his voice, on account of the fact that the cord still remained quite fixed.

As the iodide of potassium had produced an eruption, it was stopped, and creasote inhalations were substituted for those of terebene.

The patient returned again on 22nd December. The general health still remained good; the voice was only slightly, if any, better, but the swelling in the larynx was

Digitized by Google

distinctly less, and the white surface over the left arytenoid was less defined at its margins.

A large mass of pultaceous whitish substance was squeezed out of the swelling with Schrötter's forceps. On examination this was found to consist almost entirely of leptothrix filament.

Menthol inhalations were substituted for the creasote.

I saw the patient next on 4th April, 1898—that is, after three and a half months' interval. He was in as good health as ever, and the voice was somewhat better, but still hoarse. He stated that the tired feeling in the throat which used to come on after speaking was quite gone.

On examination, the swelling and white surface in the larynx were seen to have completely disappeared, and the larynx was normal except for the fact that the left cord was firmly fixed in the middle line.

The patient has remained in the same condition since.

Mycosis of the larynx is in any case a rare affection, but the present case is, I believe, unique, in that the larynx was alone affected. In all the others that I have been able to find, the laryngeal affection was associated with the same condition in the mouth, pharynx, or naso-pharynx.

The particular interest in the case just described is the way in which, so far as appearances went, the disease simulated tubercular laryngitis perfectly. The physical examination and the history of the case, however, and the peculiar absence of cough throughout the whole course, were sufficient to raise doubts about its nature, and the microscopical examination decided the matter definitely.

It must not be assumed that in the case described above the mycosis has been the original cause of the trouble. For my own part, I do not think it was, although to trace the whole sequence of events can only be a matter of speculation. The following explanation appears to me to be the most satisfactory:—Many years ago, possibly about at the time when the patient had his slight attack of rheumatism, the vocal cord became fixed. Such fixation of a part makes it a more suitable nidus for the organism, and it is quite possible that at some comparatively recent period the fungus obtained a footing, and caused the swelling, the congested appearance, and the sense of weariness after speaking. These symptoms disappeared after the cure of the mycosis, although the vocal cord remained fixed, and the hoarseness was unaffected.

The symptoms attributable to the mycosis were slight; but,

Digitized by Google

as I have remarked before, the case is of some importance on account of the close similarity it presented to tubercular laryngitis. The naked eye gave us help in the diagnosis, but the microscope cleared the matter up at once. In view of this fact, it would be of interest to know whether some of the cases of so-called "cured tubercular laryngitis" may not have been in reality cases of mycosis of the larynx associated with phthisis pulmonalis.

As regards the literature of the subject, there is no other record, so far as I am aware, of mycosis of the larynx alone. A few cases, however, are recorded in which it has spread from adjacent parts of the buccal and pharyngeal cavities:—Dubler (*Virchow's Arch.*, Bd. 126, S., p. 454), Labit (*Revue de Laryngol.*, 1893, No. 5, p. 168). The best exposition of the whole subject is that of Dr. Kelly, which appeared in the *Glasgow Medical Journal* of 1896.

MEETING VII.—13TH JANUARY, 1899.

The President, DR. G. S. MIDDLETON, *in the Chair.*

I.—FRESH SPECIMENS.

BY DR. EDGAR.

1. *A ruptured gravid tube removed five days ago.*—The dilated portion was an inch from the cornu of the uterus, measures 1½ inch in length and 1⅜ inch in breadth, and shows an irrregularly circular tear 1 inch in diameter on its posterior surface. The ovary on being laid open shows a large corpus luteum; a tubal mole, measuring 2 inches by 1¼ inch by 1½ inch, was found lying free in the pelvic cavity. Possibly it was separated from the tube while freeing the latter from its adhesions. The pelvic cavity was filled with dark blood. The history is briefly as follows:—Last confinement eight months ago; apparently no pelvic disease; two months' amenorrhœa with no symptoms of pregnancy, but with, at the sixth week, a sudden attack of abdominal cramp-like pains; profuse uterine hæmorrhage on 24th December, preceded for four days and accompanied by severe colicky pains in the abdomen; sickness and marked weakness, but no

Digitized by Google

vomiting nor syncope; the hæmorrhage continued until admission. It is remarkable, considering the size of the rupture, that syncope and death did not occur. On 31st December, what was probably a decidual cast was passed.

Progress since operation satisfactory; temperature and pulse normal.

2. *Fibroid uterus and adherent appendages removed by Howard Kelly's method of abdominal hysterectomy.*—The patient, æt. 37, and unmarried, is a seamstress, and has suffered so much from dysmenorrhœa and metrorrhagia that, for the last year, she has been unable to perform her duties to the satisfaction of her employers. She had repeatedly to give up work, but, as she had herself and mother to support, she could not retire from business.

The tumour is in the posterior wall of the uterus, and has firmly adherent to its posterior surface the enlarged right ovary, which measures 3¼ inches in length, and at the time of the operation was distended with dark fluid blood. There was a hæmatoma in the left ovary also. The adhesions behind and at the sides were very firm, and gave a great deal of trouble during the operation. Both ovaries ruptured while freeing the adhesions.

The operation was performed ten days ago, and patient has made an excellent recovery. There have been no sickness, thirst, pain, nor abdominal distension. Temperature and pulse normal. Stitches removed to-day. Wound healed by first intention.

II.—NOTES ON TUBAL CASES.

By DR. J. K. KELLY.

It is strange to think that as late as 1881—not yet eighteen years ago—the most distinguished English gynæcologist of that time could say that he had then seen only one case of tubal disease in all his life! I don't suppose that any gynæcologist could now be found who does not recognise the Fallopian tube as one of the most frequent sources, if not actually the most frequent source, of pelvic disease. And this is simply what should be expected from the anatomical relations and from the embryological history of the tube. Embryologically, the tube is part of the uterus, and consists of the same structures; anatomically, it is continuous with it, and its cavity leads directly into the peritoneal cavity, so that disease of the uterus, which is so frequent, is naturally transmitted to

Digitized by Google

the tube, and the tube again naturally transmits such disease to the peritoneum. Were it not, in fact, that the peritoneum has a wonderful power of self-protection there would be few women free from peritoneal disease originating from the Fallopian tube. In general practice it is not to be expected that this outstanding importance of the tube as a cause of disease should be by any means fully recognised, seeing that until recently specialists in gynæcology were themselves so divided in opinion. Accordingly, when asked for a contribution, I thought nothing could be more useful to this Society than to show some diseased tubes, and give a short note of their history. The difficulty I found was to choose the kind of tubes to show, and those I have brought to-night are all illustrations of purulent salpingitis. This is undoubtedly far less common than catarrhal salpingitis, which I consider one of the most frequent ailments of women, but it is perhaps the most frequent disease of the tube that calls for operation. The pathological condition is a simple one, but the effects it produces on the neighbouring parts are sometimes of the most complicated character. An early result of salpingitis is usually the closure of the abdominal end of the tube, and this is so far a barrier to the extension of the inflammation to the peritoneum. It is not a very secure barrier, however. Another result is the extension of the purulent inflammation to the ovary, which in some cases becomes a mere pus sac. Then over the tube and ovary thus diseased, uterus, broad ligament, omentum, small intestine, large intestine, and sometimes even the bladder, and on the right side the vermiform appendix, become united into a mass, the individual constituents of which become almost inseparable. It is this matting of all the neighbouring organs around and over the diseased tube that constitutes the sole difficulty in the operation for the removal of the diseased part, and if we could have our cases diagnosed early enough the operation would be simplified, and, I might say, entirely freed from danger.

What, then, are the symptoms and signs that might lead to a diagnosis of tubal disease?

With regard to symptoms, I think there are none which are perfectly reliable, but we may say that a pain localised in or starting from one side of the pelvis, increased on the approach of menstruation, and accompanied by menorrhagia, is at least good ground for suspicion of tubal disease, and would warrant an examination. If with these symptoms, or even without them, we have a small irregular tumour in the region of the tube, if this tumour is not movable apart from neighbouring

Digitized by Google

structures, if it extends towards Douglas's pouch, and especially if it presents a convoluted surface, it is probably tubal. Evidence of pus formation will increase the probability, and a history of an illness—such as a gonorrhœa, a puerperal inflammation, or a tubercular peritonitis—which might have as one of its results a closure of the abdominal end of the tube would raise the probability almost to a certainty.

An analysis of the symptoms in our cases to-night shows that all suffered from pelvic pain; about 82 per cent suffered from dysmenorrhœa; about 64 per cent suffered from menorrhagia, while 45½ per cent suffered from irregular hæmorrhage, and in 18 per cent the menses were reported scanty; about 36½ per cent suffered from dysuria.

1. Mrs. C., æt. 29, iii-para (last child five years ago), three premature. Since an attack of puerperal fever, six years before, has suffered from constant pain in left side, frequently shooting down left leg, at times resembling labour pains. When pain is severe she has a feeling of abdominal distension. Since then, also, she has suffered from menorrhagia and dysmenorrhœa and also from irregular hæmorrhage, which sometimes lasts several weeks.

Physical examination revealed enlarged and tender appendages on left side, passing into Douglas's pouch, and on the right side also the appendages were fixed in adhesions. In this case, however, the condition was obscured by an enormous hypertrophy of the cervix, which had been twice operated on in Edinburgh, under the idea, the patient said, that it was cancerous. We did not consider it cancerous, but, in order to make certain, we had a small piece of it examined before operating on the appendages.

At the operation the tubes and ovaries were found adherent to all the neighbouring structures, but the adhesions were separable without great difficulty.

The specimen has shrunk a good deal, but it still shows the characteristic convolutions of the tubes when closed at the fimbriated ends.

2. Mrs. M., æt. 23, nullipara. Patient has suffered for two years from painful and frequent micturition, from pain in right side of pelvis, and from pain during menstruation, especially at the commencement of the flow. During the past eighteen months she has also had pain in the left side of the pelvis, shooting down the left leg, increased during menstrua-

Digitized by Google

tion, and not relieved by the flow. Menstruation during the last three months has been more scanty than usual.

Physical examination revealed a slightly enlarged uterus, with fundus towards the right in the posterior half of the pelvis. Left appendages formed a tumour above left vaginal fornix, and right appendages were adherent along right side of uterus and posteriorly in Douglas's pouch, where the tenderness to palpation was excessive.

At the operation the adhesions round both appendages were found exceedingly dense and difficult to tear through.

Specimen shows left appendages uppermost, with remains of a peritoneal cyst in outer part. The only place where distinct pus was found was in outer part of right tube.

3. A. G., æt. 25, i-para, seven months ago. In this case symptoms were very little complained of. There was dysmenorrhœa and menorrhagia, but not so great as to disable the patient subsequent to the confinement seven months before admission. A few days before admission sudden severe pain set in on left side, and in the course of twenty-four hours passed all across the hypogastrium, and this pain continued till she came into hospital.

Physical examination revealed a firm cystic mass filling the left side and posterior part of pelvis, with the uterus lying in front of it and considerably enlarged. Pressure on the cyst, especially on the left side, caused pain. Uterus and cyst could be moved together slightly upwards and downwards. The right appendages could not be felt.

At the operation omentum was found adherent over uterus and distended left tube. The left appendages were densely adherent to bowel and pelvic floor, and some pus escaped during the separation of the adhesions. The right appendages were only slightly adherent, and were removed without difficulty.

Specimen shows left tube and ovary in lower part of jar (rather spoiled). The right ovary is slightly cystic, and tube shows acute salpingitis.

4. Mrs. A., æt. 29, iii-para, last six years ago, one abortion three years ago. Patient has suffered for several weeks from pain in lower abdomen, chiefly on right side, labourlike in character, from pain in micturition, from a feeling of bearing down, from irregular uterine hæmorrhage, and from occasional shiverings and sweatings.

Digitized by Google

Physical examination revealed a rounded elastic tumour filling Douglas's pouch, and passing mainly towards right side of pelvis. The uterus was enlarged and carried forward by the tumour, the cervix being close behind pubis. The upper surface of the tumour could be felt *per abdomen*, reaching as high as the level of the anterior iliac spine.

At operation omentum and bowel were found adherent all over right side of pelvis, and the tube was found fixed in the very bottom of Douglas's pouch. The left appendages also were adherent to bowel.

Specimen shows the right tube and ovary fixed together. Near uterine end of tube has been left attached a piece of omentum, which could not be detached without tearing the tube and causing escape of pus. In the abdominal end of tube is a small oval mass formed by the fimbriæ turned in and fixed together.

5. Mrs. K., æt. 32, ii-para, last five years ago. Patient suffered from pelvic inflammation after birth of still-born child three years ago. Since then has suffered from pain in left side and shooting down left leg, from dysmenorrhœa, menorrhagia, painful and frequent micturition. Was curetted in Edinburgh seven months ago without more than temporary relief.

Physical examination revealed matting of appendages on both sides, convoluted tube on left side, enlargement of uterus, and great tenderness to palpation in the vaginal fornices.

At the operation the appendages were removed with great difficulty. Right tube and ovary were surrounded with numerous thin-walled cysts, filled with clear fluid, apparently peritoneal in origin.

Specimen shows the right appendages lowermost, with a few of the cysts still visible; the left appendages show pus cavities, and in the ovary a hæmorrhagic cyst.

6. Mrs. L., æt. 36, iii-para, last six and a half years ago. Patient complained of pain in back and in abdomen, chiefly on left side, and shooting down both thighs. The pain was paroxysmal, and was brought on by exertion. She has lately had uterine hæmorrhage, and pain in micturition. She has never had shiverings or sweatings.

On physical examination uterus was found enlarged. Both sets of appendages were matted together, and the left passed round into Douglas's pouch.

At operation extensive adhesions to bowel and omentum

Digitized by Google

were found, both over the appendages and between them and the uterus.

Specimen shows both tubes and ovaries containing pus, the left appendages being the lower.

7. Mrs. B., æt. 26, nullipara, one abortion four years ago. Patient had suffered since the abortion from pelvic pain, chiefly in right side, worse before menstruation, and somewhat relieved by the flow; from menorrhagia; from dyspareunia. Shortly after marriage, and previous to her pregnancy, she had pain on micturition, and this has occasionally troubled her since.

Physical examination showed uterus slightly enlarged, displaced a little to the left, but in normal anteflexion. Left appendages were slightly enlarged in normal position, but right appendages were considerably enlarged, and passed round towards Douglas's pouch, excessively tender to palpation.

At operation omentum was found adherent to anterior abdominal wall, and the incision had to be carried through it. The appendages were densely adherent to all the adjacent structures.

Specimen is a beautiful example of pyosalpinx.

8. Mrs. M'N., æt. 33, i-para, twelve years ago, three abortions. Patient dated her complaint from fourteen months ago, when she was lifting a heavy bed, and felt something give way in her abdomen. This was followed by cramp in her abdomen and profuse flooding. Since then she has been mostly confined to bed.

She has severe dysmenorrhœa, menorrhagia, and irregular hæmorrhage. She suffers from constant pain, worst on the left side, but passing also round to the right.

Physical examination showed a retroverted enlarged uterus, and the appendages formed cystic tumours on both sides, and passing round to meet each other in Douglas's pouch.

Specimens show tubes filled with pus, ovaries with numerous enlarged Graafian follicles, and in one a large hæmorrhagic cyst.

9. Mrs. W., æt. 38, vii-para, last five years ago; two abortions, last eight years ago. Patient dated her illness only from six weeks before admission. It began with sudden severe pain in right iliac region and shooting down right thigh, and with uterine hæmorrhage, which has continued since then with very little interval. The pain occasionally resembled "after pains."

Digitized by Google

Her strength has rapidly declined, and she has had frequent rigors but no sweatings. The pain has continued, and is excessively severe.

On examination uterus was found enlarged, retroverted, and thrown towards left side of pelvis by a tumour occupying region of right broad ligament. There was a suspicion that this might be an ectopic pregnancy, as the right uterine artery pulsated strongly, and the breasts were secreting. During the fortnight she was in hospital previous to operation, the tumour seemed to vary in size, but rather diminished on the whole. The diagnosis of a hæmatoma of the right broad ligament was made.

At the operation the omentum was found adherent over pelvic cavity. Both sets of appendages were densely adherent to all the adjacent structures, and were removed with difficulty.

Specimen shows tubes containing pus, and ovaries with small cysts, some of them hæmorrhagic.

10. Mrs. M., æt. 39, nullipara, one premature labour thirteen years ago. Thirteen years ago, patient had what she called an "abscess of the womb." Two years later she had "inflammation," *i.e.*, pain in left side of abdomen, with rigors, vomiting, and sweating. Since then she has always had this left-sided pain. It is worse during menstruation. For four or five years she has had menorrhagia. She has frequent shiverings and sweatings, and has emaciated of late.

On examination uterus was found pushed slightly to the left by a round elastic tumour, filling the whole left side of pelvis and passing round into Douglas's pouch. On right side appendages were found adherent along the side of the uterus.

We had no doubt about the diagnosis of pyosalpinx in this case, and proceeded to operate in the usual way, but when we opened the abdomen, we found that the supposed large pyosalpinx was a myoma attached to left side of uterus, and passing out between the folds of the broad ligament. This diagnosis was confirmed by the presence of one or two small myomas close to the angle of the uterus, and as the patient took chloroform very badly, and probably would succumb if we attempted hysterectomy, we resolved to leave the tumour untouched, and closed up the abdomen again. We were all disappointed at this result, and it was mortifying to think that our diagnosis had gone so far wrong. But we were consoled somewhat by the fact that a myoma was not so serious a disease as a pyosalpinx. The patient felt better, and went to

Digitized by Google

the convalescent home nineteen days after the operation; very soon, however, her pain returned as before, and in three months she returned to the ward and asked to have the tumour removed, whatever the risk might be. Accordingly, we reopened the abdomen, and removed, not a myoma, as our sense of sight had led us to suppose, but a pyosalpinx, as both the history and the clinical examination had shown that it must be. There was great difficulty in separating the sac from its adhesions, and a considerable quantity of pus escaped. The right tube was normal, the right ovary contained several follicular cysts, and was adherent in the lateral pouch of Douglas. It was separated from its adhesions, and one or two of the cysts punctured, but as both the tube and ovary were free from pus they were not removed.

Specimen shows the left appendages forming mainly a large pus sac, in which the ovary takes the chief part.

11. Mrs. C., æt. 20, i-para, two years ago. Complaint began about five months ago with slight pain in left side, increased during menstruation. Menses were then rather scanty. Dyspareunia has been present for seven months. Two months ago uterus measured 3½ inches to sound, and her medical attendant made a diagnosis of endometritis, and used the curette to endometrium. Four days before admission she was seized with sudden severe pain in left side, passing across the lower abdomen and accompanied by a feeling of distension; this was followed by vaginal discharge.

On examination uterus was found normal in size. On left side of uterus, and near angle, was a small pulsating swelling with granular surface, and feeling doughy on pressure; below and behind this, and passing towards Douglas' pouch, was a distinctly cystic tumour. On right side the appendages were enlarged and adherent. The tumour in left side slightly increased in size after admission to the hospital, and this, taken with the fact that the patient's doctor had found no tumour there at the time he curetted two months before, made it possible that we might have in this case an ectopic pregnancy, though the absence of uterine enlargement, of cervical softening, of mammary secretion, and indeed of all signs of pregnancy, made us incline to the diagnosis of pyosalpinx, which was confirmed at the operation.

The omentum was adherent at the inner end of each tube, where pus was oozing through from the tubal lumen.

The specimen shows the left tube and ovary in lower part, the tube enormously distended by pus, and the ovary forming

Digitized by Google

a blood cyst, the effusion of blood thus probably accounting for the increasing size of the tumour after admission. The right tube also contains pus.

Dr. J. M. Munro Kerr regretted that Dr. Kelly had not analysed the symptoms of such cases a little more fully. He had not sufficiently emphasised the importance of the fact that both tubes were affected in almost all cases, nor had he sufficiently indicated that the tubes almost always passed downwards and backwards behind the pouch of Douglas. It was essential to a diagnosis to make out the former point, which was almost invariably conclusive in favour of pyosalpinx.

Mr. H. E. Clark had seen nearly all the cases before operation. He had been struck by the great frequency of tubal disease and the relative infrequency of ovarian tumour in Dr. Kelly's wards. The great difficulty of the operation was apparently to be found in the extent of the adhesions. Dr. Kelly's cases were all, it seemed, inflammatory; had he seen many of tubercular origin? Mr. Clark asked also with regard to the mortality of the operation in such suppurative cases.

Dr. H. E. Jones had seen, a few weeks ago, a woman of 24, who had been married for four years. She had never menstruated. Her complaint was of pain in the left side, extending down the leg. On examination, a tumour was discovered in the pouch of Douglas on the right side, while a smaller nodule was present on the left. He consulted a specialist, who thought the tumours due to enlargement of the ovaries. There might, therefore, be exceptions to the rule laid down by Dr. Kerr.

Dr. Kelly, in replying, said that both tubes were usually affected, as the disease was generally communicated from the uterus. When the tumour passed towards the pouch of Douglas, it was still more probably of tubal origin. He had seen several cases of tubercular disease of the tubes. In even the worst of these cases the mortality was not great. Out of the twelve submitted to the meeting, only one had died.

III.—VAGINAL CŒLIOTOMY.

By Dr. Edgar.

Vaginal cœliotomy, colpo-cœliotomy, or colpotomy is an operation now so well known that a description of it is unnecessary. Though, many years ago, Thomas and others

Digitized by Google

occasionally removed ovaries *per vaginam,* it is chiefly to Dührssen we owe the present established position of the operation. He first performed it in 1890, but it is only since 1893 that he has carried out its employment systematically. The points to which I desire to draw attention are (1) its advantages in suitable cases over abdominal section, (2) its indications, (3) its contra-indications, and (4) its dangers.

ADVANTAGES OF VAGINAL CŒLIOTOMY IN SUITABLE CASES OVER VENTRAL CŒLIOTOMY.

1. *Comparative freedom from shock and pain.*—This is probably due to the fact that during the operation the peritoneal cavity is little, if at all, exposed, and the bowels are seldom handled or even seen.

2. *Less risk of sepsis.*—It was formerly thought that it was difficult or impossible to render the vagina aseptic, but both bacteriological evidence and clinical experience prove the falsity of this idea. In none of my cases has there been the slightest degree of sepsis following the operation, and all have ended in recovery.

3. *Ability to rise sooner.*—This is because of what I have already mentioned, and also because the wound heals quickly, and there is no risk of hernia.

4. *No visible cicatrix.*—From an æsthetic point of view, this is a decided advantage.

5. *No abdominal belt required.*

6. *Drainage, if required, is at the lowest point.*

7. *Effective plugging* for oozing of blood from torn adhesions, &c., can be applied and reapplied more easily in posterior colpotomy than in abdominal section.

8. *Other vaginal operations* can be performed at the same time *without re-disinfection or changing the patient's position.* To illustrate this point I may mention that in one case I performed dilatation and curettage of the uterus, amputation of the cervix, posterior colpotomy, removal of a broad ligament cyst, and perineorrhaphy; and, in another, puncture of several Nabothian cysts, dilatation and curettage of the uterus, anterior colpotomy, left salpingo-oöphorectomy, ignipuncture of the right ovary, vaginal fixation of the uterus, and colpo-perineorrhaphy.

Thus, the advantages of the operation are considerable, and in my opinion indisputable. It is a pity, therefore, that the indications are so much more limited than for abdominal section.

Digitized by Google

INDICATIONS FOR THE OPERATION.

1. *Vaginal fixation of the uterus and shortening of the round ligaments after colpotomy.*—These, like the other modes of operative treatment for retroflexion and prolapse of the uterus, are still *sub judice.* One ought to withhold judgment till the various methods have had further trial. In one class of cases, however, fixation of the uterus is certainly advisable, viz., during cœliotomy for removal of both appendages, if the uterus be retroflexed or prolapsed.

I have performed vaginal fixation six times, and ventral fixation by Czerny's method seven times. All the patients recovered with the exception of one of the latter, on whom abdominal section was performed for a large ruptured dermoid cyst. In none of them has there so far been any recurrence of the uterine displacement. My first case of vaginal fixation was performed at the time when it was thought necessary to obtain sero-fibrous union of the anterior surface of the body of the uterus with the vagina. This patient, unfortunately, became pregnant and died at her confinement. During pregnancy there was no disturbance whatever, but when labour ensued, the anterior wall of the uterus was found not to have expanded properly, and the os was at the promontory, and could not be got to dilate fully. Finding that forceps and version were out of the question, I intended at first to incise the anterior lip and lower uterine segment, but was prevented from doing so by the fact that the placenta was attached to this part. I therefore perforated, and applied the cranioclast, hoping that the os would dilate further, and allow the diminished head through. I failed in effecting my purpose, however, and had to resort to Cæsarean section. The patient did not recover from the shock of the operation, and died within thirty-six hours. I regret now that I attempted craniotomy, instead of proceeding at once to Cæsarean section. In the cases in which I have performed vaginal fixation since then, I have invariably used two fixation sutures of silkworm-gut, one at the level of the internal os, and the other 1½ cm. above this. These I have removed after six weeks. All have done well. One had a normal confinement last September. Dührssen considers that with this plan, which is practised by A. Martin, Rühl, &c., relapses must be frequent. He advocates sero-serous fixation of the uterus in the following manner:—After separating the bladder from the cervix, he opens the utero-vesical pouch by a vertical incision, brings down the

Digitized by Google

fundus uteri, passes a silkworm-gut suture through vaginal wall and peritoneum on one side, then into the anterior uterine wall at the level of the tubes, and finally through peritoneum and vaginal wall on the other side. Before tying this suture, he closes the peritoneal opening with catgut. He claims that in twenty cases, where labour at or near full term ensued after sero-serous fixation, only two cases required operative treatment—viz., in one case forceps, in another craniotomy—and states that in both of these the operation was indicated, not by malposition of the uterus, but by rigidity of the cervix. As regards recurrence of the backward displacement, he says that this took place only in cases in which he employed catgut for fixation of the uterus.

2. *Disease or tumour of the appendages.*—In one case, operated upon in December, 1896, and published in the *Glasgow Medical Journal*, August, 1897, I removed by posterior colpotomy a broad ligament cyst of the size of a cocoanut. I was surprised at the ease with which the removal was effected. Recovery was rapid, and the patient has since remained in good health. In one case I removed a small fibroma of the ovary with good result, and in two cases cystic ovaries, also with good result. One cystic ovary I treated by means of ignipuncture. Lastly, in one case I removed both appendages for the rare condition, salpingitis isthmica nodosa, ascribed by Schauta and Chiari to gonorrhœa. In view of the assertion by Hegar and Alterthum that this condition is due to tuberculosis, it is interesting to note that the family history in my case is extremely tubercular. The patient's father died of consumption, five or six brothers and sisters died in infancy of "water in the head," and one brother died at seven years of age of "tubercular meningitis." After opening the utero-vesical pouch and bringing down the uterus, I found both appendages considerably matted and adherent to the pelvic wall. The adhesions were broken through with some little difficulty, and the diseased appendages removed. The special point of interest, however, was the presence of a yellow bean-like nodule embedded in each cornu of the uterus, the interstitial portion of the tube. The omentum was firmly adherent to the two nodules and to no other part. I resected them, and the patient made a good recovery, and is still in excellent health. The sections of the nodules show under the microscope caseating areas. (Shown at the meeting.)

In cases where it is proposed to remove a cyst by vaginal cœliotomy, it is important to make sure beforehand that the

Digitized by Google

tumour is unilocular or paucilocular, is not semisolid, and, if large, has no adhesions at the upper portion. If one be in doubt, it is better to open the abdomen in front.

In pyosalpinx, it is recommended by many leading gynæcologists to remove the uterus along with the appendages, partly because the uterus itself in these cases is always diseased, and partly because bisection of the uterus simplifies the removal of the distended and adherent tubes. I have no experience of this operation. In only one case have I been compelled to perform the radical operation on account of pelvic suppuration. This was done by the abdominal route, and was reported in the *Glasgow Medical Journal*, January, 1898. I saw the patient two weeks ago. She had psoriasis, but was in good health and spirits.

3. *Fibro-myomata of the uterus.*—Hitherto, I have always adopted the abdominal route in removing these tumours, unless, of course, in the case of polypi. Since, however, seeing several vaginal hystero-myomectomies by Doyen's method in Veit and Treub's cliniques last September, I have made up my mind to perform the operation whenever I meet with a suitable case. The tumour which I showed to-night was suitable as regards size, but was much too adherent to warrant the vaginal operation.

4. *Cancer of the uterus.*—The question as to the advisability of operation and as to the kind of operation in such cases is too large for me to enter into in this paper. Out of a very large number of cases, I have so far seen only two in which vaginal hysterectomy was in my opinion justifiable. In both the immediate result was successful. One died eight months after operation from so-called recurrence; the other is still alive seven months after operation. I saw her four days ago, and, though there is recurrence, she states that the constant hæmorrhage, from which she suffered prior to operation, has not returned; whilst the pelvic pains, which were formerly severe, are now slight. She is distinctly stouter and stronger.

5. *Pelvic abscess.*—This, when acute and bulging into the vagina, is best treated by a wide vaginal incision. I have had two such cases. One was a puerperal abscess, which, in July last, I opened and cleared out thoroughly by means of my finger and a douche. Several flaky lumps came away with the pus. Though the sac was larger than a man's fist, the cavity was completely closed in three weeks. I saw the patient yesterday, and found the uterus in good position and freely movable; no thickening, except for a slight cicatrix in the posterior fornix; menstruation normal. The other case

Digitized by Google

had an obscure origin, was of similar size, and was treated in a similar way. In this case the abscess had burst into the rectum on the morning of the operation. During the after-treatment the fæces gave some trouble, but the temperature remained normal. The abscess cavity closed in two weeks, and the recto-vaginal fistula closed in four weeks after the operation. There is now no trace of anything having been wrong.

A third case ruptured into the vagina spontaneously, and did well, but was much slower in healing.

Cases of chronic pelvic suppuration are usually pyosalpinx or suppurating cyst. The best treatment is to remove the offending organ or tumour. In such cases the vaginal route has several advantages over the abdominal—drainage is downwards, not upwards; the matting of intestines and omentum is less disturbed, so keeping the general abdominal cavity shut off; and the pus and the diseased tissue are brought through the vagina instead of through the abdominal cavity. For these reasons the danger of sepsis is less.

6. *Ectopic gestation.*—Cases of pelvic hæmatocele, which bulge into the vagina, should be treated in the same way as pelvic abscess, viz., by a large vaginal incision, thorough evacuation of the contents of the sac, and packing with gauze. During the operation, when my two fingers are in the sac, I always endeavour to palpate the tube bimanually. If it be found to be much enlarged, I think it would be advisable to remove it, though I have never had occasion to do so.

I have treated two cases of pelvic hæmatocele by vaginal incision and drainage, and have assisted Dr. Stirton with thirteen. In my cases the progress toward recovery was rapid and afebrile, and the healing was complete in two or three weeks. Dr. Stirton's cases healed more slowly, because the contents of the sac were not cleared out at the time of operation; but all recovered, except one, which ended fatally on the eighteenth day. I have traced the subsequent history of most of these cases, and have found the condition of the patients satisfactory, not only as regards menstruation, but also as regards pelvic pain and uterine mobility.

I have had other three cases of pelvic hæmatocele which, however, showed signs of absorption, and were treated medically with good result. That all my cases were cases of ectopic gestation, I have little doubt, despite the fact that in none of them had I any positive proof.

Vaginal cœliotomy has been advised also for tubal pregnancy before rupture, and for cases where tubal rupture or abortion

Digitized by Google

has occurred, but no hæmatocele has formed. I have had fourteen such cases, but in all, except one, which was treated medically, I removed the tube by abdominal section. The diagnosis of ectopic pregnancy was confirmed in these cases by the presence of chorionic villi. I have the idea that the alarming arterial hæmorrhage which may ensue when you separate the adhesions, as happened in one of my cases, can be more quickly controlled from above. I may be wrong, as I have no experience in such cases of salpingectomy by the vaginal route. All my cases did well. One has had a normal confinement since, and another is normally pregnant just now. (Since reading this paper, the latter has been confined; labour was natural and easy.)

With regard to extra-uterine pregnancy at mid-term, Dr. Berry Hart, in a paper which was published in the *Scottish Medical and Surgical Journal*, August, 1897, has described four cases treated by extra-peritoneal abdominal section, one of which developed suppurative parotitis, carboluria, and a fæcal fistula after the operation. He states:—"Of course, I quite admit that a vaginal incision into an extra-peritoneal sac, containing only blood, followed by washing out, is excellent treatment; but my difficulty is that if a fœtus and placenta be present, as they may be in an apparent hæmatocele of four months' standing, the arrest of hæmorrhage is very difficult, the tampon infinitely less effective and more dangerous, and the after-treatment much more troublesome." I have had only one such case. This I treated by vaginal incision and removal of fœtus and placenta in October, 1896, and reported in the *Glasgow Medical Journal* for October, 1897. My experience in this case was the exact reverse of what one would expect from Dr. Hart's assertions. The operation lasted ten minutes; the arrest of hæmorrhage was easily obtained; the tampon was so effective that there was absolutely no bleeding afterwards, and recovery was rapid, afebrile, and uneventful. Though at the time of operation the sac reached the umbilicus, and the patient was almost moribund, in four weeks the cavity was closed, and in one week thereafter the patient left the hospital.

She is still in good health.

CONTRA-INDICATION TO VAGINAL CŒLIOTOMY.

The operation is as yet much too recent to dogmatise on this point. Much will depend on the skill and the predilections of the operator; but the limits of the operation ought to be

Digitized by Google

defined as well as possible, because discredit may be cast on a new operation by the selection of unsuitable cases.

Multilocular or semi-solid ovarian cysts, malignant disease of the appendages, large uterine myomata, narrow vagina, and, except in pelvic abscess and hæmatocele, fixation of the uterus, are distinct contra-indications to colpotomy. The question of adhesions is much more difficult, as this depends greatly on the skill and experience of the operator. As a general rule, where the appendages to be removed are adherent to the upper part of the pelvis, it is preferable, unless the radical operation is to be performed, to open the abdomen in front. When the infundibulo-pelvic ligament is tense, it is apt to be torn. In such cases the bleeding from the ovarian artery may require instant removal of the uterus before it can be arrested. Döderlein required to do this four times; Martin, with many more cases, has never required to resort to it.

Tumours which are adherent, unless they are small, had better not be removed *per vaginam*, because of the risk of injuring adherent intestine.

DANGERS OF VAGINAL CŒLIOTOMY.

1. *Hæmorrhage.*—If this be a general oozing, and if interference be necessary, the part can be plugged with iodoform gauze, or, as in my case of ectopic gestation at mid-term, with aseptic sponges soaked in hazeline, much more easily and effectively, and with better after-results, than through a ventral opening. In arterial hæmorrhage, whether from the ovarian artery or, as in one of my cases, from a branch of the uterine artery, the bleeding point must be sought for and secured. This, as I have already indicated, may at times be difficult.

2. *Injury to bladder, ureters, or intestine.*—Several such cases have been reported by Baumm, Olshausen, &c. Apart from the use of clamps, such injuries are generally the result of separation of extensive adhesions. When seen, they ought to be repaired at once.

In conclusion, I regard vaginal cœliotomy, when performed in suitable cases, as a distinct advance in operative treatment. What is required is a definite pronouncement regarding its limitations. This only further experience, carefully reported, will enable us to give.

Digitized by Google

Dr. J. K. Kelly said that, owing to the smallness of the vagina, there was risk of injury to the intestine in such operations if adhesions had formed above. The treatment of pelvic hæmatocele by vaginal incision was not always sufficient, as the abdomen might have to be opened afterwards.

Mr. H. E. Clark said that the present idea in surgery was to see the parts operated upon as completely as possible. In cœliotomy much had to be done in the dark. Adhesions of all kinds were better dealt with from the abdomen, and the same was true of hæmorrhage, especially arterial hæmorrhage.

Dr. Edgar admitted the dangers of the operation in non-selected cases. It was surprising how well one could see what one was doing in vaginal operations. It was sometimes possible to see the parts better than in abdominal operations.

MEETING VIII.—3RD FEBRUARY, 1899.

The President, DR. G. S. MIDDLETON, *in the Chair.*

I.—CASE OF PSORIASIS RUPIOIDES.

BY PROFESSOR M'CALL ANDERSON.

Dr. Hinshelwood showed, on behalf of Professor M'Call Anderson, who was unable to be present, a case of psoriasis rupioides. The patient was a schoolgirl, æt. 9 years, who had enjoyed good health until five months ago, when the eruption appeared, first on the legs, and gradually implicated the body and arms. The case was shown as affording an exceptionally typical example of this condition, first described by Professor M'Call Anderson many years ago. In this variety of psoriasis, a great accumulation of epidermis takes place on the diseased areas, so that on many of the patches it assumes the shape of large conical crusts marked by concentric rings, resembling in shape limpet shells, and from their likeness to the crusts of rupia, Professor M'Call Anderson named this variety psoriasis rupioides. In his opinion, however, this condition has no connection whatever with rupia, except in the shape of the crusts.

Digitized by Google

II.—CASE OF TABES ASSOCIATED WITH DIABETES.

BY DR. JOHN LOVE.

Dr. Love showed a case of tabes associated with diabetes. The ataxia had developed with great rapidity. There had been some improvement under Fränkel's method of re-education.

III.—CASE OF TABES WITH CHARCOT'S JOINT AFFECTION.

BY DR. JOHN LOVE.

Dr. Love showed a case of tabes in which Charcot's joint affection was very typically present in the left knee, and slightly present in the right. It was not a case for amputation, as there was ataxia in the arms, which would interfere with the use of the crutch. It was a question whether excision was practicable.

Dr. Alex. Robertson had not seen a case where tabes was associated with diabetes. If the association were really pathological, it tended to show that there was a defect in different parts of the nervous system. With regard to the second case, it was impossible to distinguish the joint affection in Charcot's disease from rheumatoid arthritis, except by the association with ataxic symptoms.

Dr. W. K. Hunter asked for an explanation of the physiology of the re-education method.

Dr. Middleton said that the first case was interesting as being a reversal of the ordinary association of diabetes and peripheral neuritis. With regard to the second, he had not seen more than six cases of Charcot's disease at meetings of Glasgow societies. Sir James Paget could not find one case in the bones in the London museums, although there were plenty of rheumatoid arthritis. (Dr. Robertson said that he had referred only to the clinical phenomena.) Even the clinical disorganisation was greater in Charcot's disease.

Dr. Love replied that in trophic joint affections the resemblances to rheumatoid arthritis were only superficial, as there was much destruction as well as hypertrophy of bone. An atrophic form of the affection also existed. He could offer no explanation of Fränkel's method beyond the hypothesis of substitution, or the escape of a sufficient number of fibres to carry on the function.

Digitized by Google

IV.—CASE OF PSEUDOHYPERTROPHIC PARALYSIS.

BY DR. JOHN LOVE.

Dr. Love showed a case of pseudohypertrophic paralysis, or at least of muscular dystrophy, beginning at the age of 14. No other member of the family, and no collateral, was affected. The distribution was similar to that of the pseudohypertrophies of Duchenne. The gait was still fairly good, and the patient did not "climb up his legs." This sign was not pathognomonic of pseudohypertrophy.

Dr. Alex. Robertson said that the patient was older than usual for the beginning of such a type of disease. "Climbing up the legs" was usual where the disease began in the calves and extended upwards. He agreed in the diagnosis.

Dr. Middleton said that fifteen years ago he had examined several cases pathologically. One of the conditions in the muscles in pseudohypertrophic paralysis was a replacement of fibres by coagulation necrosis, which he thought might be the first change, giving place afterwards to fatty change. This might explain the hardness of the muscles in this case. There had not been a sufficient examination of the muscles by harpooning in the early stages. "Climbing up the legs" was present in all the early cases he had seen, but was not pathognomonic. The knee-jerks were well-marked in this case, although they were usually absent, even in the early stages.

Dr. Love said that all rules were liable to exception. One could not be absolute either about the knee-jerks or the method of rising. There were exceptions even in the course of the disease. He had seen a lady of 45 in advanced paralysis, in whom the general health was not much affected.

Digitized by Google

MEETING IX.—17TH FEBRUARY, 1899.

The President, DR. G. S. MIDDLETON, *in the Chair.*

I.—SUCCESSFUL CASE OF LAPAROTOMY FOR PERFORATED ENTERIC ULCER, WITH SPECIMENS OF OTHER ENTERIC PERFORATIONS.

BY DR. T. K. DALZIEL.

Dr. Dalziel showed a patient on whom he had successfully operated for perforation of an enteric ulcer in Belvidere Fever Hospital.

The patient, A. E., aged 13 years, was admitted on 19th November, 1898, into Belvidere under the care of Dr. Laird, who reported that she had a history of languor, headache, abdominal pain, diarrhœa, and cough.

On admission, temperature was 103·2°, and patient had the appearance of an enteric case—malar flush; dilated pupils; furred tongue; abdomen distended; slight pain and tenderness in hypogastrium; no gurgling; a pain in right iliac region; no rash; spleen not palpable; complained occasionally of pain in abdomen, but at 6 A.M. on 25th November this became very severe, and temperature rose to 103·6° from normal; pulse, 124; respiration, 60, shallow, rapid, and entirely thoracic. Vomited shortly before 6 A.M. Face pale and anxious looking. Abdomen slightly distended, rigid, and tender all over. Liver dulness normal. Perforation diagnosed, and Dr. Dalziel communicated with. Laparotomy performed at 5 P.M., eleven hours after perforation, and completed at 5·35 P.M.

An incision was made from the umbilicus downwards for a distance of 3 inches. On opening the abdomen a large quantity of turbid fluid escaped, and the peritoneum was found to be in a state of acute inflammation with flakes of lymph on its surface. The perforation was found about 15 inches from the ileo-cæcal valve, and was closed by two rows of fine silk continuous sutures; the peritoneum was freely irrigated with saline solution, and two large rubber drainage-tubes were placed in the pelvis. The tubes were aspirated every half hour by means of a syringe and catheter. During the night patient

Digitized by Google

vomited four times, and complained of severe abdominal pain. On the following day vomited once, had no pain, and expressed herself as feeling much better. Subsequent recovery was continuous and uneventful, and patient was dismissed well on 4th February.

Dr. Dalziel quoted statistics of operations, and suggested that in reasonably early cases it was probable that we might hope to have 25 per cent of recoveries; that 95 per cent of perforations, if left alone, proved fatal. One great difficulty in obtaining cases soon after perforation was the difficulty in diagnosis, as often the more virulent peritoneal infections led to a profound toxæmia, which masked the local signs of early peritonitis. According to Durham, a streptococcus infection was always a severe complication, and of grave prognosis. There was a great difference between the appendix perforations in enteric and those of the ileum—the former being much more favourable, as tending to become limited in their effects by the formation of adhesions due to the fixed condition of the viscus as compared with the movable and moving ileum. Modern surgery recognised the absolute necessity for operation in perforative peritonitis, and enteric cases formed no exception; indeed, in them the necessity seemed even greater, since the patient was little able to withstand the shock of peritonitis. The operative interference was wonderfully well borne by enteric cases. In all cases it was evident that great relief was obtained, and in none could it be said that the fatal issue was hastened.

In all, Dr. Dalziel had operated on eight cases, of which three were moribund and in such a condition that in similar future cases operation would not be proposed. Of the other five, one made an excellent recovery; one lived three and a half days, but, from the extremely acute attack of fever, little hope was ever entertained of recovery; one promised to do well, but died the day after operation from hæmorrhage; while the remaining two were not materially modified in their progress towards death.

Early diagnosis was probably the key to future success, and might be said to depend on sudden abdominal pain, and especially tenderness in the lower part of the abdomen coming on about or in the third week of the fever; vomiting; muscular rigidity; sudden fall in temperature, especially if in the acute stage of the fever, soon followed by a rise; rapid pulse; often a motion was passed with a small blood-clot. Later, evidence of gas in the peritoneum; loss or diminution

Digitized by Google

of liver dulness; abdominal distension; free fluid in the peritoneum. In all stages, a pinched, anxious expression of features.

It was worthy of consideration whether in doubtful cases it would not be well to open the abdomen on the first evidence of localised peritonitis, the so-called pre-perforative stage, of which a further sign might be obtained in the onset of leucocytosis, the value of which was not as yet fully established, but was worthy of careful consideration. The majority of spontaneous recoveries were probably appendix perforations which did not materially differ from ordinary perforations of that viscus. The later in the fever the perforation occurred the greater chance was there of limiting adhesions forming. The exact nature of the peritoneal infection would probably be found to be an important element in determining the issue. The typhoid bacillus itself seemed to play a small part in the peritoneum.

It was interesting that in the case which recovered no cultures were obtained from the peritoneal fluid thirty-six hours after operation.

Mr. R. H. Parry inquired, with regard to the case where there was no peritonitis, if any rigidity existed. He was not now in the habit of washing out the peritoneum and then leaving it alone, but in a recent case, where the lymph was very adherent, he had turned out the entire small intestine.

Mr. A. E. Maylard said that five years ago the successful cases might have been counted on the fingers. The statistics of perforation were of very little value. He imagined that the symptoms of a localised perforation of the appendix would differ from those of a perforation of the free bowel. It was impossible to decide on the method of treatment of the peritoneum until the actual condition was seen. In some cases it was useful to turn out the intestine, and in others to wash out the abdominal cavity. He narrated a successful case of Cushing's, in which the abdomen was opened three times.

Dr. Grant Andrew mentioned a case in which he had operated fourteen hours after the perforation. He had found a general peritonitis. The perforation was easily discovered and closed, but the patient died fourteen hours after the operation. He asked whether it was justifiable to search for a second perforation after one had been found, and mentioned that in some cases the colon was the seat of

Digitized by Google

perforation. As flushing the abdominal cavity was not uniformly successful, he suggested continuous irrigation for forty-eight hours.

Mr. Maylard inquired whether it should be held that a surgeon should be called in in all cases.

Professor M'Call Anderson laid stress upon the importance of operating early and rapidly. He had not seen a successful abdominal case in which the operation had lasted more than two hours. If it were true that 5 per cent of the cases recovered naturally, some of those operated on might have recovered without operation.

Dr. Middleton said that there was a difference between cases treated in hospital and those treated at home. If patients had to be removed to hospital, the result was not likely to be favourable.

Dr. Dalziel replied that he agreed with Mr. Parry as to the frequent occurrence of rigidity in such abdominal cases. When the peritoneum was coated with lymph, the only means of removing the lymph was to turn out the intestines and clear it off, but that process was not in itself sufficient to render the peritoneum aseptic. He thought that the fluid should in all cases be examined bacteriologically. In one case he had sutured three perforations, all of which had evidently occurred at the same time. He could not advocate continuous irrigation, as it did not flush the whole abdominal cavity. A surgeon should be called in on the occurrence of any unusual or acute symptom. He would have no hesitation in operating in private in acute cases.

II.—CASE OF EXTRA-CAPSULAR FRACTURE OF THE FEMUR OPERATED ON.

BY MR. R. H. PARRY.

In this case distinct shortening of the limb was present, and the fragments were impacted. After an incision had been made over the trochanter, the femur was replaced in its proper position. The patient was up in six weeks, and was able to go about in seven. The shortening and other symptoms had disappeared.

Dr. Dalziel discussed the propriety of exposing fractures involving joints. Many of the fractures at the hip-joint might safely and properly be operated on, and with absolutely good results.

Digitized by Google

III.—LARGE NASAL POLYPUS WITH CYSTIC DEGENERATION.

BY DR. J. G. CONNAL.

The polypus was about the size of a large plum. It sprang from the upper border of the right inferior turbinated body by a narrow pedicle, and extended from the anterior nares back to the posterior nares. Anteriorly, the lining membrane was very thin, and this collapsed on the attempt to remove it. The method adopted to extract it was to pass a Krause's snare round it and sever the pedicle. The polypus was then removed with dressing forceps, and the base cauterised with the electric cautery.

The patient, a lady, 47 years of age, said she had some "growths" removed from the right nostril when she was a girl of 13 years, but she was not aware of the present condition. She sought advice on account of a slight dulness of hearing in both ears, and the polypus was discovered in the course of a routine examination of the nose. There were no symptoms of its presence, and no headache. When her attention was directed to it, she said that there might have been at times, during the last eighteen months, a slight feeling of obstruction in the right nostril, but nothing to complain of.

The nose is often remarkably tolerant of foreign bodies. It is not an unusual occurrence to find nasal polypi—even of large size—and the patients will affirm that there have been no symptoms of their presence.

Mr. Parry asked if the growths were simple, and was answered in the affirmative.

IV.—THE HEART FROM A CASE OF MORBUS CÆRULEUS.

BY DR. GLEN.

This heart was obtained from a male child, 5 months old. At birth and during the first two months nothing unusual was remarked as to its appearance or health by the parents. Cyanosis came on and gradually increased during the latter three months, and the child became more and more peevish in temperament, so that when I first saw it about ten days before death the mother's request was for a soporific. Cyanosis was extreme. Temperature was normal, and the pulse regular and frequent. Breathing was frequent, but not markedly

Digitized by Google

laboured. Though of small size there was no emaciation, the limbs being firm, apparently from passive congestion.

On examination of the chest, the area of præcordial dulness was found to extend as far to the right of mid-sternum as to the left. Cardiac pulsations were as easily palpable, and the heart sounds as distinctly audible, in the right as in the left parasternal line; all over the sounds were free from murmur. Anteriorly and posteriorly the rest of the chest gave a clear percussion note. The respiratory murmur was equal on both sides and free from râles. The hepatic dulness was enlarged.

Post-mortem examination.—On opening the pericardium, which was non-adherent, the right upper superficies is seen to be right auricle; this is of about equal size to the exposed ventricular portion.

On removal of the heart the *aorta* is found to be greatly enlarged, having a diameter three times as great as the pulmonary artery. At its origin the aorta lies to the left of, and behind, the pulmonary artery. The valve is competent, and its flaps appear to be of normal structure. The right and left coronary arteries arise from the anterior and the left posterior sinuses of Valsalva; through the latter artery a style has been passed.

The *pulmonary artery*, placed at its origin anteriorly and to the right of the aorta, bifurcates half an inch from its valve into the two branches. The valve is competent, but from the posterior flap a warty vegetation the size of a split pea projects inwards. Both arteries open from a common large ventricular cavity.

In this *ventricle* no vestige of a septum can be traced. The walls are much thickened, but otherwise present healthy appearances. At the base, towards the right, a large auriculo-ventricular orifice is seen communicating with the right auricle. This is curtained by a tricuspid valve, consisting of large equal left and posterior flaps and a small right flap.

The *right auricle* is also greatly enlarged. Superiorly, it receives the superior vena cava, and inferiorly, the inferior cava. The foramen ovale is completely occluded, except for a small opening at the upper left extremity leading obliquely into the left auricle.

The *left auricular cavity* is also of considerable size, and receives the two pulmonary veins. The septum between this cavity and the enlarged ventricle is thickened, and quite

Digitized by Google

imperforate. The only other opening from this sac, as it might be termed, is the communication with the right auricle, an opening which, from its position, direction, and size, would rather favour a flow of blood from right to left auricle than from left to right.

This heart thus presents—(1) A single ventricle, whence blood flows into an aorta and a pulmonary artery; (2) a right auricle in receipt of blood from the systemic veins, and allowing of its flow freely into the ventricle, and also perhaps in limited quantities into the left auricle; and (3) a left auricle communicating with the pulmonary veins and the right auricle. So far as can be judged from the relation of the parts, this latter communication is from right to left.

As only a partial examination was permitted, the other thoracic vessels were not examined. A study of the heart alone makes it extremely difficult, or perhaps impossible, to understand how the circulation was carried on, and sufficient aëration of the blood obtained to allow of life for five months.

V.—HEART WITH A SINGLE VENTRICLE AND A SINGLE AURICLE.

By Dr. R. M. Buchanan.

Dr. Buchanan showed a drawing of a heart with a single ventricle and a single auricle. There was no trace of either the ventricular or the auricular septum.

Dr. Middleton said that the central position of the cardiac dulness was similar to that in a case of his which had occurred some years ago.

Digitized by Google

MEETING X.—3RD MARCH, 1899.

The President, DR. G. S. MIDDLETON, *in the Chair.*

I.—FRESH SPECIMENS.

A. BY DR. J. H. NICOLL.

Vermiform appendix with ulcerative perforation excised from a case where secondary perforation of the cæcum had occurred.—The case illustrates two points—

1. Perforation of the cæcum may occur from the inside—as the result of ulceration (catarrhal, dysenteric, tubercular, malignant, &c.). As Treves has pointed out, it may also occur from the outside—as the result of contact with a perforated or gangrenous appendix. Within the past three years I have brought before the Society two other cases in which there existed what we found in this case. The perforated appendix, which forms the specimen, lay embedded in adhesions against the cæcal wall, and at one part of that wall there existed a blackish-grey area in which a small ulcerative perforation gave vent to cæcal contents. This, Dr. Alex. Maclennan assisting, I closed with sutures, and there is every prospect of the case terminating as favourably as the two referred to.

2. Dr. Kirkland, who sent the patient, a young lady, to me, was led to advise operation because of the recurrent nature of the illness, the patient having had four attacks.

It is interesting to note, as has been frequently pointed out, that in appendicitis absence of fever and pain affords no guarantee that perforation does not exist. This patient had neither. She made a successful recovery, and left the nursing home well on 28th March, three weeks after the operation.

B. BY DR. J. M. M'CALL.

Dr. J. M. M'Call showed the liver and spleen of a dog affected with sarcomatous disease.

Digitized by Google

II.—CASE OF STRICTURE OF THE PYLORUS IN WHICH GASTRO-ENTEROSTOMY WAS SUCCESSFULLY PERFORMED.

BY DR. NEWMAN.

The patient, a female about 35 years of age, was admitted to the Sandyford Nursing Home suffering from symptoms of obstruction to the pylorus for many months. The disorganisation of the process of digestion showed itself by more or less discomfort after meals, a sense of fulness in the region of the stomach, nausea, loss of appetite, pain and flatulence, accompanied by considerable distension of the stomach. The patient also complained of headache, mental depression, and a tendency to refrain from food. Later on vomiting was a marked symptom, sometimes occurring three or four times a week, and on these occasions the quantity vomited was very considerable, causing sour eructations and a burning sensation in the mouth.

The patient placed herself under the care of Dr. Alex. Shiels, and after some weeks her health considerably improved, so that she was able to retain food well, and increased considerably in weight. It was evident, however, to Dr. Shiels that the obstruction to the pylorus was steadily increasing, and he asked me to examine the patient with a view to operative interference. On palpation of the abdomen there was clear evidence of the presence of a swelling in the epigastric region, immediately under the right costal cartilages, moderately movable from side to side, but less so from above downwards. Over the rest of the stomach there was no undue sense of resistance, but there was clear evidence of considerable dilatation. The other abdominal organs and the organs in the thorax were normal. On 4th January, 1899, I opened the abdomen, by an oblique incision, 3 inches below the left costal margin, and extending from the middle line downwards and outwards; the stomach was exposed and the pylorus examined, when it was found to be occcupied by a small, hard, firmly adherent swelling, about the size of a Tangerine orange. There was no enlargement of lymphatic glands. An anastomosis was established between the stomach, 3 inches to the left of the pylorus, and the upper part of the jejunum, by means of a Murphy's button, which came away twenty-three days after. Previous to the operation the stomach required washing out once every forty-eight hours to prevent vomiting; but since the patient has not vomited except from chloroform

Digitized by Google

sickness, her appetite has improved, she has gained weight, and the dyspeptic symptoms have disappeared.

The object of the operation was to establish an opening between the blocked stomach and the small intestine as high up in the jejunum as possible. The operation has been suggested under two conditions—first alone, and second as preliminary to a pylorectomy. In this particular case the objection to a performance of the latter operation was the circumstance that the pylorus and upper part of the duodenum were firmly adherent to the structures around, so that the removal of the disease would be attended with very considerable danger. Of course, one would prefer in all cases of epithelioma to remove the disease; but I have found, in some instances of malignant disease of the alimentary tract, that when a short circuit is established, and food is prevented from passing over the diseased parts, very considerable wasting and diminution in the size of the growth results. When the functional activity of the part is placed in abeyance the nutritive activity is diminished, as is well shown in the next case.

III.—CASE OF TUMOUR OF THE COLON IN WHICH COLO-ENTEROSTOMY WAS DONE WITH A GOOD RESULT.

By Dr. Newman.

The case was one of a large tumour in the ascending colon causing chronic obstruction. The patient, a man, complained of symptoms pointing to obstruction in the colon dating back for many months. The onset of the disease was so slow and insidious that it was difficult to say when it actually commenced. The most troublesome symptoms were indigestion, diarrhœa alternating with constipation, colicky pain, and flatulence, which were most severe when associated with constipation. Occasionally the abdomen became considerably distended, and the peristaltic action of the bowels was greatly increased. For many months the bowels were fairly regulated by the use of medicine and carefully regulated diet. In June last, when the patient was seen by Dr. Shiels, the swelling in the ascending colon was large and extremely tender; but during the autumn, by careful treatment, the tenderness diminished, the swelling decreased, and the patient's general health improved. In December, 1898, movement of the bowels was effected only by the continual use of laxatives.

Digitized by Google

When I saw the patient, on 17th January, 1899, the colon was found to be occupied by a swelling, which extended from the crest of the right ileum to the costal margins, and occupied the abdomen as far forward as a line drawn between the middle of Poupart's ligament and the right nipple. The lower and upper limits of the swelling were elastic, while the central part was firm and hard. The abdomen was moderately distended, and, while examining it with the hand, every few minutes distended coils of bowel became visible as a consequence of increased peristaltic action.

On 21st January the abdomen was opened, and the condition of matters explored. The colon, from the caput cæcum upwards to the margin of the right ribs, was found occupied by a dense hard mass, which was firmly adherent to the parietes. The abdominal surface was smooth and regular, but the whole swelling was quite immobile. An anastomosis was established between the small intestine, close to the caput cæcum, and the patent colon, 4 inches above the mass just described, by means of a large Murphy's button. Since the operation the swelling in the colon has diminished to about one-third of its previous size, but the central part is even harder than formerly. Above Poupart's ligament the induration has disappeared, and there is also a clear space between the swelling and the ribs. The patient has not required any laxative, the bowels being moved regularly once or twice a day.

In this case the most remarkable fact is the rapid diminution in the size of the tumour within six weeks of the anastomosis being established.

IV.—CASE OF ROUND- AND SPINDLE-CELLED SARCOMA OF THE PHARYNX—THE TUMOUR REMOVED BY OPERATION —NO RECURRENCE.

By DR. NEWMAN.

The patient, J. M'N., aged 41, was admitted to the Glasgow Royal Infirmary on 15th November, 1898, complaining of difficulty in swallowing, and pain at the back of the throat. The swelling in the throat was first noticed eight years previous to admission, and since then has slowly increased in size. He was not aware of any sudden increase in the rapidity of its growth; but it seemed, when he was admitted, distinctly larger than when he first presented himself at the beginning of November. The first thing that attracted his

Digitized by Google

attention was an alteration in his voice, which has now come to resemble that of a person with cleft palate. He states that he has had no pain in the swelling.

On examination a distinct tumour was observed on the posterior wall of the pharynx, immediately to the left of the middle line. The swelling was smooth, tense, and on palpation with the fingers gave the impression of being cystic in its nature. As far as seen from the mouth, it appeared to be about the size of a hen's egg; but, on examination with the finger in the mouth, and palpation externally, the tumour was found to extend to the level of the cricoid cartilage. Its uppermost limit was on a level with the tip of the epiglottis. On account of the uncertain nature of the swelling, a portion of the growth was removed and submitted to microscopic examination, when its structure revealed the characteristic appearances of a round- and spindle-celled sarcoma. Tracheotomy having been previously performed, and chloroform administered through a long indiarubber tube, an incision was made through the cheek from the left angle of the mouth to the angle of the jaw. In making this incision, all the soft parts down to the mucous membrane were divided first, and only after all bleeding points had been secured was the mouth fully opened into. This allowed all the blood to escape externally. A ligature was passed through the tongue, and it was pulled well out to the right side. The larynx was plugged with sponges. An incision was then made through the mucous membrane from the uppermost limit of the tumour as far down as the finger could reach; but, even with this, considerable difficulty was experienced in shelling out the tumour with the finger, but by means of forceps the whole growth was separated from its attachments, and ultimately removed. The incision in the mucous membrane of the pharynx was not sutured, but the edges of the wound in the cheek were carefully brought together. The patient made an uninterrupted recovery, and was able to be up and about the ward within five days of the operation. The patient reported himself well on 2nd February and 3rd March.

The most remarkable feature in connection with this case is the long period which the tumour has taken to grow, the rapid increase in bulk occurring only during the last few weeks previous to admission.

A careful study of the history of recorded cases shows that sarcoma of the pharynx, as well as sarcoma in the larynx, remains local for a long time, in very few cases are the cervical glands involved, and it is not common for the viscera

Digitized by Google

to become infected by the disease. In this respect the sarcomatous growths in the pharynx are a marked contrast to those of the tonsil, where secondary formations take place rapidly. The prognosis, therefore, in sarcoma of the pharynx, so long as the primary growth is completely eradicated, is by no means so grave as when the tonsil is the primary seat. Another important fact is that, while in the tonsil the sarcomatous new formation becomes diffuse and infiltrating, in similar growths in the pharynx the neoplasm is distinctly encapsuled. In the present case the prognosis therefore is favourable.

V.—CASE OF INJURY OF THE KIDNEY WITH PROLONGED HÆMATURIA—ULTIMATE RECOVERY.

BY DR. NEWMAN.

The patient, J. S., a man aged 21, was admitted to the Glasgow Royal Infirmary on 17th December, 1898. The patient had attempted to jump on to a train while in motion at Bridgeton Cross station, and had fallen between the platform and the footboard of the train, in consequence of which he received a severe crushing, and on admission complained of pain across the lumbar region and in the abdomen. Beyond some grazing of the skin, there were no wounds nor injury to bones. The patient on admission suffered from considerable shock, and on examination a distinct fulness could be made out over the right lumbar region, and he complained of considerable pain on pressure over the right kidney. The first urine passed after admission was of a dark porter colour, and besides containing a large quantity of blood, it deposited urates; but no blood-clots were passed. During the night after admission the patient was restless, and passed urine at frequent intervals. The amount of blood decreased during the night, and at 6 A.M. the following morning perfectly clear urine was passed, free from blood and albumen. This was the only specimen, however, which did not contain blood, all the other samples being deeply coloured, although not so dark as that passed immediately after the accident. Again, on 19th December, urine quite free from blood and albumen was evacuated, again to be followed by many evacuations of blood-stained urine. The patient was kept at rest in bed, and a careful observation was made of each specimen of urine passed. With occasional remissions for a very short period, more or less blood was noticed from 17th December, when the patient was admitted, until 21st January,

Digitized by Google

when he left the hospital. During the last week of his residence in the house the quantity, however, was so small as to be imperceptible to the eye. The fulness over the right lumbar region slowly disappeared, and when the patient was dismissed he was quite free from pain. On several occasions the urine passed immediately after the temporary cessations of hæmaturia contained small worm-shaped coagula, casts of the ureters showing that the freedom of the urine from blood was the result of plugging of the ureter by a clot. This case is remarkable from the fact that the hæmaturia continued during a long period after the accident. Generally in such cases blood disappears from the urine within at least a week of the accident. There was no evidence of injury of other abdominal organs.

The presence of blood in the urine in such cases does not necessarily denote rupture or laceration of the organ; and, on the other hand, severe injury may be sustained by the kidney without blood at any time appearing in the urine. The latter contingency may arise either as a result of the plugging of the ureter by a clot, or as a consequence of rupture of the ureter from the violence which caused the injury to the kidney, or in rare instances it may be due to the rupture of the kidney being so excessive that the blood escapes into the perinephric tissue only, and not through the ureter to the bladder.

In cases where the kidney is bruised, without laceration of its tissue, hæmaturia may be present for a few days after the accident. The bleeding is not usually prolonged or severe, and the presence of blood in the urine may not closely follow upon the injury; its appearance, indeed, in some cases may be delayed for hours, or even for days, from plugging of the ureter by a coagulum. In the more severe laceration of the kidney the urine is usually highly-coloured and scanty, and blood appears in the first quantity of urine passed after the accident; the hæmaturia may not be constantly present, and may vary in amount from time to time, or it may not appear at any time in the whole course of the case, consequently its absence must not be taken as an indication that the kidney is free from injury. Supposing the ureter to be completely torn across, or the kidney divided through nearly its whole thickness, the great probability is that the blood will escape into the tissues surrounding the injured organ rather than by the ureter and bladder.

Dr. Ernest Thomson asked if Dr. Newman made a lateral

Digitized by Google

incision in the bowel in forming the anastomosis in the first case.

Dr. Middleton had been much interested in the first case. He considered that non-malignant pyloric tumours were much more frequent than was usually supposed. In such cases the operation should prove very useful.

Dr. Newman replied that narrowing of the pyloric orifice was frequently due to spasm. Myoma of the stomach, too, was not very uncommon. It was very difficult to distinguish clinically between malignant and non-malignant tumours of the pylorus. The patient should therefore always be given the chance afforded by an operation.

VI.—FRONTAL SINUSITIS, WITH SEVERAL ILLUSTRATIVE CASES.

By DR. WALKER DOWNIE.

To-night I wish to draw your attention to inflammations of the frontal sinus, and to show several patients in whom the frontal sinus was opened for the cure of various conditions which had led to persistent suppuration.

The superciliary ridges mark the site of the frontal sinuses. They are situated one on each side between the two "tables" of the frontal bone, and in close proximity to the root of the nose. They vary greatly in size and extent in different individuals; and the two sinuses are usually separated from each other by a bony (or partly bony and partly fibrous) partition, which, however, is occasionally incomplete.

Of the three walls which bound the sinuses the outer is the thickest, the orbital or inferior is the thinnest, while the inner or cranial wall occupies an intermediate position. Each sinus communicates with the nasal fossa on the same side through a canal or infundibulum, and this irregularly shaped passage, beginning at the lowest part of the sinus, is directed downwards, and opens into the anterior part of the middle meatus under cover of the middle turbinated bone, and slightly in front of the nasal opening of the antrum of Highmore. Occasionally those two passages, namely, that leading from the frontal sinus and that from the maxillary sinus, communicate with each other or unite to form a common opening. Where such an abnormality exists, secretions from one cavity may pass into the other—that is, fluids from the frontal sinus may flow from the higher into the lower cavity, while pus originating in the maxillary antrum may, by capillary attraction, pass upwards and into the frontal sinus.

The sinuses are lined by a continuation of the mucous

Digitized by Google

membrane of the nose; but, in contrast to the vascularity of the lining membrane of the nares, it is here thin, pale in colour, and firmly adherent to the bony wall.

From those anatomical facts it will be readily understood how an inflammation of the lining mucous membrane of the nose may spread from the nasal cavities upwards and affect the lining membrane of the frontal sinuses. And it is the rule rather than the exception for catarrhal inflammations of the nose to do so.

I presume that we all have experienced the discomfort, to put it mildly, of a headache from "the cold," caused by a congestion and consequent swelling of the lining membrane of one or both sinuses, along with, it may be, the temporary retention within the cavities of the resulting secretions. Fortunately, those cavities, as has been stated, are drained from their *lowest* point, so that, as the inflammatory swelling subsides, the secretion in most instances readily escapes, and pressure and pain are relieved.

Another important factor in the removal of secretions from the frontal sinus is the readiness with which air enters it. This may be demonstrated by getting a patient whose frontal sinus has been operated upon, and portion of the outer wall removed, to blow the nose, when air, forcing blood or mucus before it, escapes freely. When the sinus is inflamed, and there is a tendency for the somewhat tenacious secretions to become retained, air is forced up into the sinus during the act of nose-blowing, and its compression in that cavity usually expels any fluid contained therein.

But occasionally the excretory duct of the sinus becomes occluded. This blockage may be from greater swelling—œdema—of the mucous membrane, the result of a more intense inflammation. This not infrequently occurs during epidemic influenza. In some cases the occlusion is rendered complete by the presence of intranasal new growths, and in others the cause is to be found in some deep-seated inflammatory process, usually syphilitic, implicating the periosteum and bone in the region of the infundibulum. Whatever the cause in any individual case may be, pressure is excited within the sinus by the pent-up pus, when pain, and in many cases deformity, results.

Pain is especially complained of over the region of the affected sinus, but by reflection along the branches of the trigeminus it may be complained of over a much greater area. The pain is aggravated by exertion, by coughing, and by stooping.

Digitized by Google

Deformity.—The contour of the outer wall, which is the thickest, is least readily altered by the pressure from within, but pressure on the inner wall may give rise to symptoms of intracranial tension, as in the first case to be referred to. Should this wall become eroded, a frontal abscess or a suppurative meningitis would inevitably follow. The inferior wall of the sinus being the thinnest is most readily, and is, in fact, most frequently, distended, in which case the eyeball is forced downwards and outwards, as will be seen in the photograph (Fig. 1, p. 302) of Case II.

On inspecting the interior of the nose, creamy pus may be seen occupying the middle meatus on the affected side, and in addition to this purulent secretion some local pathological changes may be observed.

Acute frontal sinusitis leading on to suppuration and deformity is rare. Latent empyema, on the other hand, is of not infrequent occurrence; and in most cases it has existed for many months, and in some for years, before advice is sought.

The symptoms of *latent empyema* are neither numerous nor characteristic.

1. There is first a purulent nasal discharge, invariably, as far as my experience goes, one-sided, not abundant, and occurring intermittently.

2. Pain of a dull character, increased by stooping and occasionally increased by pressure on the orbital wall of the sinus, is complained of, and this pain is worst when discharge is least, and is again relieved by the free escape of pus. One of my patients, who is here to-night, was, as a rule, comparatively free from pain during the early part of the week, but by Friday the pain over the frontal sinus became severe, and increased in severity until well on on the following day, when it was suddenly relieved by the escape of a quantity of pus.

3. In many cases the odour of the pus lodged in the nose is a source of great annoyance to the patient, whose sense of smell is not impaired, although no odour is perceived by those in close association with the patient.

4. On intranasal inspection we may meet with mucous polypi, and where there are no actual outgrowths we are almost sure to find an œdematous swelling of the mucosa over the anterior end of the middle turbinated bone. Under cover of this bone creamy pus will be seen. If this discharge be mopped up, and the part be again examined, a bead of pus will slowly appear and will gradually enlarge as the quantity increases.

Digitized by Google

Now, those same symptoms may be present when there is suppuration in the anterior ethmoidal cells, and without there being any involvement of the frontal sinus; and, also, they may be complained of in many cases of empyema of the antrum of Highmore. By trans-illumination, however, the condition of the latter cavity can be readily ascertained, so

FIG. 1.

that doubt as to the state of the maxillary sinus need not be further considered.

Suppuration, as is known, may affect several sinuses in the same individual; but my experience does not agree with that of Clive, who says that in all his cases of frontal and ethmoidal sinusitis the antrum contained pus. On the other hand, I can say that I have found the anterior ethmoidal cells to be the

Digitized by Google

seat of a suppurative process in five out of six cases of latent empyema of the frontal sinus, and in most cases I believe that the suppurative inflammation originated in the ethmoidal cells.

In operating for the cure of chronic suppuration within the sinus I am guided by this experience; but before describing the *modus operandi* I would mention that, in my opinion, attempts to dilate by means of bougies, or to catheterise the passage from the middle meatus of the nose to the sinus, are futile; and attempts made to tap the floor of the sinus by trocar and cannula introduced through the nose are not only futile, but fraught with great danger.

Operation.—The first stage in the operation is the removal, under cocaine, of the anterior third or somewhat more of the middle spongy bone on the affected side by means of the electric

FIG. 2.

cautery and cold-wire snare. The condition of the cells found in the portions removed varies greatly, and in some of those here shown it will be seen that one cell has developed or become distended, at the expense of neighbouring cells, to form the walls of a large bony cyst (Fig. 2, p. 303). This portion of bone having been excised, the fronto-ethmoidal cells are then, or subsequently, broken down by means of a small curette, and thus not only are infected and freely communicating cells destroyed, but one possible cause of obstruction of the passage from the frontal sinus is removed. When the surfaces operated upon have healed, the patient is placed under chloroform and the sinus is opened through an external incision. One of two incisions may be chosen. First, the incision may be made in the middle line. This was adopted in two of the cases here to-night, and is selected where there is a probability that both sinuses require exploration. In neither case has the scar caused any

Digitized by Google

disfigurement, and in one it is almost imperceptible. Secondly, where one sinus alone is involved, and this is the usual state of matters, an incision along the superciliary ridge, and thus in the line of the eyebrow, is to be preferred. This was employed in the other cases shown. The incision having been made down to the bone, the periosteum is raised over the area of the sinus, and, with the lips of the wound kept well apart with retractors, the anterior wall of the sinus is perforated. This may be accomplished by a hand or dental drill, or by means of a mallet and gouge. The greater part of the anterior wall should be removed in order that the cavity may be satisfactorily examined, and any abnormality present dealt with. The edges of the opening in the bone should be made perfectly smooth.

The sinus, on being opened, is usually found to contain pus, but, on the other hand, it may be empty at the operation. This was found to be the case with the girl, in whom the pain over the sinus increased towards the end of each week, but the lining membrane was greatly thickened and deeply injected, and the operation was followed by entire relief from pain and disappearance of purulent nasal discharge. Limited necrosis of portions of the walls, and accompanied by granulations, was found in three cases; the cavity was packed with mucous polypi in one; and a subacute inflammation of the lining mucous membrane was present in the others.

After the cavity has been cleared, a director is passed downwards into the nose. Patency of the passage is thus ensured, and any remaining ethmoidal necrosis can be curetted. I now never insert any drainage-tube, but I pack the cavity—the sinus—firmly with cyanide gauze, and the end of the packing is brought out through a counter-opening made close to the inner canthus of the eye. The incision is then closed throughout its length, and in each case it has healed by first intention, and in each case the resulting cicatrix is entirely hid by the newly grown eyebrow. The packing is left in position for from seven to fourteen days, and then withdrawn through the small counter-opening.

The following is a summary of the cases shown at the meeting:—

CASE I.—William G., a miner, aged 35, was referred to me at the Western Infirmary on 3rd March, 1898, by Dr. Kerr, of Cumnock. He complained of a purulent discharge from the left nares of four years' duration. This was frequently accompanied by severe pain over the left side of the head, and

Digitized by Google

was specially marked over the region of the left frontal sinus. The pain was frequently so severe, particularly on stooping at his work, that he was compelled to take "idle days," and at night he occasionally became delirious. This latter symptom was at first supposed to be due to indulgence in alcohol, but on careful observation and enquiry that was found not to be the case.

On examination, there was pus lodged in the left naris, and on this being removed the left middle turbinal was seen to be considerably enlarged, there being hypertrophy of bone as well as of the covering mucosa. The right naris was healthy, and the maxillary sinuses, on trans-illumination, were found equally clear.

Under chloroform the sinus was exposed and freely opened on 24th March, 1898, through a median incision. The cavity, which contained pus, was cleaned out, and the anterior ethmoidal cells were broken down and scraped away, and a free communication between the sinus and nose established. The cavity was packed with cyanide gauze, the end of which was left free in the nostril. The wound healed by first intention, and the packing was, at the end of fourteen days, removed through the nose.

Pain was absent almost from the hour of operation, and since operation there has been no return of pain, and absolutely no purulent discharge.

The line of incision is almost imperceptible, there is absolutely no pain, and he has been at work regularly since he returned home from hospital.

CASE II.—Mrs. D., aged 34, was admitted to the Western Infirmary on 26th November, 1898. She stated that in January, 1897, she first experienced discomfort, occasionally amounting to pain, over the right supra-orbital region; and coincident with this she observed an increase in the discharge from the right nostril as compared with the left. Later the supra-orbital region began to swell, and in August the swelling burst. The resulting opening healed, but the part remained swollen, and in November of the same year her family attendant incised the swelling. Pain had never been severe, but she frequently had headaches accompanied by giddiness.

On admission to hospital she was thin and anæmic. There was a considerable swelling over the region of the right frontal sinus, pale, smooth, and rounded, and the right eye was pushed downwards and outwards (see Fig. 1, p. 302). There was a

Digitized by Google

copious discharge of very foul-smelling pus from the right naris. After the interior of the nose had been thoroughly cleansed it was examined, and found, apart from a general injection of the lining mucous membrane, to be healthy, there being no enlargement of the middle turbinated bone, and no evidence of intranasal necroses.

Two days after admission I made an incision in a line with the right supraciliary ridge, and with mallet, chisel, and gouge removed the whole anterior wall of the right frontal sinus, which was extensively necrosed. The cavity was full of very foul-smelling pus. When the cavity had been washed out, it was found that the dividing septum had been destroyed, and that both sinuses formed one common cavity. The communication with the nose was made thoroughly free. No ethmoidal disease was found. The sinus was then packed with cyanide gauze, and the free end passed through a counter-opening near to the inner canthus of the eye, after which the incision was closed throughout its length. Half of the packing was removed at the end of ten days, when the wound was found to be completely healed, and all stitches were removed. The remaining portion of the packing was withdrawn four days later, after which an external dressing alone was applied, and the patient left the hospital on 17th December with wound and counter-opening completely healed.

To-night the wound is seen to be firmly healed, the incision is hid by the eyebrow, there is no pain, no odour, and no pus.

CASE III.—Thomas G., a clerk, aged 26. Some time in 1896 he became conscious of an irritation within the left naris, the result, he supposed, of a cold in the head. This irritation, however, did not pass away, but rather increased and was accompanied by a disagreeable odour preceptible to himself alone. At this time pus began to make its appearance in the left naris, being discharged intermittently or when he bent his head forward. Frontal pain was only felt occasionally, was never severe, and was not increased by pressure over the orbital plate.

On examination, several mucous polypi, springing from the left middle turbinal and almost completely filling the middle meatus, were seen along with a quantity of fluid pus.

In February, 1898, when first I saw him, and on several occasions subsequent to that date, I removed those mucous polypi along with the anterior third of the middle turbinal,

Digitized by Google

and, at a later stage, some necrosed cells at a higher level (fronto-ethmoidal) were scraped away.

Intranasal irritation, discharge of pus, and odour persisted, so I recommended him to seek admission to hospital, where, on 24th June, 1898, I explored, under chloroform, the frontal sinus through a median incision. The sinus, when opened, contained pus, and the orbital plate close to the middle line was found to be necrosed. The cavity was cleaned out, the necrosed bone removed, and the passage to the nose was widened by curetting. The cavity was packed with gauze, the free end being passed into the nose, and the external wound was stitched throughout its length.

On 9th July the wound was firmly healed, and the gauze packing was removed through the nose. The discharge was of a mucous character and devoid of pus, and the patient could not detect any disagreeable odour.

There is now (March 1899) no purulent discharge from nares, but in certain positions of the head he is conscious of a musty odour in the left naris, and occasionally there is a small quantity of muco-pus passing to the pharynx, apparently from the posterior ethmoidal cells.

CASE IV.—Catherine M., aged 22, was first seen on 15th November, 1898. She complained of discharge from the left side of the nose, accompanied by a bad smell, for fully ten months, which followed a severe cold in the head. She has had severe frontal headaches during those ten months, varying in intensity. She said that towards the end of each week the pain over the left eye gradually increased in severity, and that by Friday, and occasionally on the following day, it became intense; when, on the appearance of a free discharge of pus, the pain almost entirely disappeared. She had observed that when headache was severe there was little or no discharge, and that when discharge made its appearance the pain subsided.

On examination, the left middle turbinal bone was œdematous and bathed in pus.

The middle turbinal was operated upon as in the other cases, and on 14th January, 1899, she was admitted to hospital.

Under chloroform, the sinus was opened by an incision over the supra-orbital ridge. There was no pus lodged in the sinus, but the lower aspect of the inner bony wall was exposed and the affected bone surrounded by granulations. These were scraped away, and a free communication with the nose

Digitized by Google

established. The cavity was packed with cyanide gauze, the free end of which was passed through a counter-opening, made a quarter of an inch above the inner canthus, and the wound stitched throughout. The packing was withdrawn through the counter-opening at the end of fourteen days.

There is now no discharge, no odour, and no pain, and the scar is entirely hid by the eyebrow.

CASE V.—Jessie M., aged 22, was first seen in September, 1896, when she complained of severe frontal headache, most marked over the left frontal sinus, with copious purulent discharge from the left naris. Nasal respiration was impaired, and there was frequent complete obstruction of the left naris.

The left naris was found, on examination, to contain several large mucous polypi, and these were bathed in fluid pus. Early in October the polypi were removed with cold-wire snare, and the surfaces freely cauterised at a later date. Although nasal respiration was thus rendered quite free, frontal headache and purulent discharge continued, and she was advised to become an in-patient of the hospital. To this she did not consent till June, and on 22nd of that month (1897) the left frontal sinus was opened through the supra-orbital incision in the manner already described. The sinus was found to be completely filled with polypoid tissue (œdematous granulations), associated with extensive necrosis of the bony walls. The granulations were scraped away, and, as far as possible, the necrosed bone was removed. A drainage-tube was inserted, to drain the cavity, into the left naris, the cavity packed with cyanide gauze, and the wound closed throughout. Ten days after operation she was made an out-patient, and at the end of two weeks the tube and packing were removed. She then felt well, and free from headache.

Four months later she was readmitted to hospital on account of recurrence of headache and suppurative discharge. On 22nd October the wound over the left superciliary region was reopened; the remaining sinus cavity was found to be again filled with polypoid tissue and pus. This was again scraped away, and chromic acid was applied freely over the interior, and the cavity firmly packed with cyanide gauze, the free end being brought out through an opening immediately above the inner canthus. The patient was put on iodide of potassium and iron. The wound healed quickly and satisfactorily, and patient was dismissed within three weeks of date of operation, practically well. She was absent from Glasgow for many

Digitized by Google

months, and on her return early this year she again came to the infirmary with a small fistulous opening over the upper and outer extremity of the left nasal bone. This led down to a small area of necrosed bone, which, on 12th February, was exposed and removed under chloroform. Now the parts are healed, there is no pain complained of, and the nares are free from purulent discharge.

Dr. Newman said that the most important symptom in these cases was the interruption of symptoms rather than their mere presence. The interruption of nasal discharge, for example, was of importance in the diagnosis. He related a case on which he had operated as far back as 1885. The most marked case he had ever seen occurred in a patient suffering from influenza and generalised catarrh. He considered free drainage into the nostrils as of great importance. To obtain this it was often necessary to remove a portion of a turbinate bone.

Dr. Rowan said that of the five cases shown two had squint, but while in one of these the squint was most probably due to the frontal condition, in the other there was probably no connection between the two. He remarked on the condition of the pupil in several of the cases; and Dr. Downie said that in one case the pupil dilated during the attacks of pain, returning to its normal condition when the attack passed. These points, Dr. Rowan continued, were of interest, as showing the connection of the eyes with neighbouring structures, and the importance, while practising one speciality, of not confining oneself too exclusively to it in dealing with the etiology of all morbid conditions.

Dr. Edington asked if Dr. Downie removed the lining membrane of the frontal sinus, and if he expected the sinus to become filled with cicatricial tissue.

Dr. Downie replied that the sinusitis had no relation to squint, as far as he knew. The lining membrane of the sinus was scraped when it was severely affected, but not when it was simply inflamed.

Digitized by Google

MEETING XI.—17TH MARCH, 1899.

The President, DR. G. S. MIDDLETON, *in the Chair.*

I.—SOME OBSERVATIONS ON THE TUBERCULIN TREATMENT.

BY DR. T. M'CALL ANDERSON.

In the recent discussions which have taken place in various parts of the country on the prevention of tuberculosis, one of the most important points insisted upon has been the necessity of preventing tuberculous meat and the milk of tuberculous cows from being consumed; and, with practical unanimity, it was conceded that the injection of tuberculin was a very certain test of the presence or absence of tubercular disease in animals.

Now, what naturally occurs to one is this. How is it that the tuberculin test is confidently relied upon by veterinary surgeons for the diagnosis of tuberculosis in animals, while medical men, with rare exceptions, fail to take advantage of it in human beings when a doubt exists as to the diagnosis? This is, I think, mainly to be accounted for by the scare produced by the results of the rash and inconsiderate way in which tuberculin was used when first introduced, and from failure to recognise the fact that it is a powerful weapon for evil as well as for good. And perhaps some of those who have not had experience of it may have believed that, though useful in the case of animals, it was not to be relied upon in that of man. There can be no doubt, however, that it is just as efficient a test in the latter as in the former. I could give numerous illustrations of this; but one will suffice, which also illustrates its curative influence, though not quoted for that reason:—

Tuberculin as a diagnostic test.—A servant girl, aged 19, was admitted into the Western Infirmary on 15th January, 1898.

Family history.—This was excellent, except that one brother, aged 4 years, was said to have died of tubercular peritonitis.

Patient's history.—Two years before admission a small,

Digitized by Google

dark red, almost livid spot appeared on the outside of the left thigh, which gradually healed in the centre and spread at the edges; the surface was dry and scaly, and there was neither pain nor itching. Shortly afterwards a similar patch appeared below the knee, which ran a like course, but it had healed up before admission, a cicatrix, which was brown at the edges, being left. Nine months before I saw her, pustules formed in the centre and at the upper part of the first patch, which ended in ulceration. The ulcerated surface continued to discharge a thick yellow pus, and undermined the skin, which had a livid tint. The diagnosis lay between hereditary syphilis and tuberculous disease. As I was inclined to think that it was probably tuberculous, I determined to test the point with tuberculin.

Treatment with tuberculin.—The first injection of the old tuberculin was given on 15th January, but there was no decided reaction till the third of 3 c.cm. of 1 in 1,000 on the 20th, which sent up the temperature to 100·4°, while the fourth (same dose) on the 23rd sent it up nearly to 103°, thus leaving no doubt of the tuberculous character of the ulceration. This treatment was therefore continued till the end of February, there having been twenty-one injections in all (the initial injection being 0·001 c.cm., and the largest 0·175 c.cm.), the total quantity used being nearly 1 c.cm. of the undiluted tuberculin. The only other treatment was 3 oz. of cod-liver oil daily, and she was dismissed quite well on 24th March, the whole duration of the treatment being about two months (chart shown).

Another field in which the utility of tuberculin has been demonstrated is in the discovery of unsuspected foci of disease. In a case of phthisis, related further on, the clinical evidences of disease were limited to the left lung, there being no trace of implication of the right; and yet, when the injections were commenced, moist râles appeared over the area of a crown piece near the right nipple, but these soon disappeared as the injections were continued. Again, in a case of lupus of the face, the tuberculin not only inflamed the face but lighted up pain in the right elbow-joint, which, too, soon disappeared. The following case also illustrates this point:—

W. S., aged 28, was admitted on the second week in January, 1891.

History.—He had had five attacks of hæmoptysis within thirteen months, occurring at intervals of two or three months,

Digitized by Google

and he had two *fistulæ in ano* of nine months' duration. An examination of the chest showed entire absence of physical signs, with exception of weakened respiratory murmur at the right base.

Treatment and result.—He was treated with the old tuberculin; 13 injections were given in all, the first of 2 c.cm. of 1 in 1,000 on 16th January, and the last, fifty times stronger, on 17th February. Before dismissal on 13th March the following report was made:—He has had no hæmoptysis for six months, and *râles which appeared along with much pain at right base* after second injection gradually disappeared within a fortnight, and there are now no physical signs. Both fistulæ have completely healed. There has been great improvement in the general health, with an increase in weight of 9¼ lb.

The value of tuberculin as a therapeutic agent is also undoubted, although, of course, there are many cases to which it is unsuited. Its effects are best studied upon cases of external tuberculosis, because there the results can be seen. It is not my intention, however, to dwell upon this, seeing that I brought a series of such cases under the notice of the Society on 13th March, 1891; but I take the opportunity of showing you a case of lupus erythematodes which was cured (patient shown in whom the disease had existed on the cheeks, head, and knuckles, scars being left on the head [with alopecia] and cheeks). This case specially interested me, because most authorities are of opinion that lupus erythematodes is not a tubercular affection, as proved by the fact that there is no reaction to tuberculin. But this case is a proof to the contrary, because not only was the affection removed but there was constitutional, as well as local reaction, as the temperature chart which I now hand round shows.

In the treatment of internal disease, such as phthisis, I am inclined to think that the (new) T.R. tuberculin is safer than the old, while I prefer the latter for purposes of diagnosis, because by its means a distinct reaction can be obtained more readily. Time will not permit of my entering fully into this subject, but I may be permitted to give the notes of the last case in which it was used:—

J. M., aged 34, stationer, was admitted into the Western Infirmary on 1st December, 1897, on the recommendation of Dr. Service, of Mossend.

Family and personal history.—The only flaw in the family

Digitized by Google

history is that one brother died of hæmoptysis at the age of 30. He had never been well since an attack of influenza three years before, and two years ago a short hacking cough set in, accompanied by a muco-purulent expectoration, in which he sometimes noticed blood. About this time also he began to lose flesh, and during the last two years had lost 2 st. For eighteen months he had suffered from night sweats, and during the last six had two attacks of hæmoptysis. For a few months, too, his strength had failed very much, and lately he had been almost unfit for work. Shortly before admission he was seen, after a long interval, by Dr. Service, who wrote—"When I saw him I was greatly shocked at his appearance; he had the appearance of a dying man, and came, as he said, that I might tell him the worst, and how long he had to live."

Condition on admission.—He was found to be pale and emaciated, with no appetite, troubled with night sweats, and with much expectoration, in which tubercle bacilli were found in great abundance by Dr. Ferguson; but there was no fever. There were no physical signs in the right lung. Over the upper lobe of the left lung in front there was moderate flattening and defective movement, decided dulness, marked increase of vocal fremitus, and slighter of vocal resonance, whilst moist râles with tubular breathing were heard on deep inspiration. Tubular breathing was also detected in the supraspinous region, and moist râles between the scapula and the spine. At the base there was slight dulness and feeble breathing; indeed, there was no part of the lung which was altogether free from signs of disease.

Treatment and result.—Dr. Service sent him to me with a view of having a course of tuberculin treatment, and, although I did not consider the case a very hopeful one, I decided to give him a chance with the new tuberculin, the only other treatment being cod-liver oil, up to 3 oz. per day. The first injection of $\frac{1}{1000}$ mg. was given on 12th December, 1897; the largest, $2\frac{1}{2}$ mg., on 26th February; and the last of 1 mg. on 22nd April, 1898, the total amount used being about 31 mg. in forty-seven injections. From the time the treatment was commenced he improved steadily, more particularly as regards his general condition, and was dismissed at his own request on 28th April, when the following report was taken:—"The patient feels in good health; he can now read with comfort for hours, whereas formerly his eyes soon got tired with reading; his appetite is completely restored; the night sweats have long disappeared; his cough and expectoration

Digitized by Google

are almost gone; and he has gained about 1 st. 6 lb. in weight."

After-history.—The last time I saw him was on 14th July, when he visited me at my request. I found that he had not fallen off in any respect, and that he had gained 7 lb. since dismissal, making a total gain of 2 st., his weight now being 12 st. 3 lb., which is his normal weight. He also stated that he could now do an ordinary day's work without fatigue. The improvement in the general was more marked than in the local condition. The expectoration showed that bacilli were still present, but in small numbers, and mostly found lying separately. The right lung remained healthy, while the condition of the left was as follows:—The flattening, defective movement, and dulness in front are not nearly so pronounced, and the râles, though still present, are scanty; while between the scapula and spine they have entirely disappeared, only puerile breathing being heard. The dulness and feeble breathing at the base are hardly perceptible. In a letter which I received lately from Dr. Service, he said —"When I saw him last, at the beginning of this week, he looked better than I have ever known him; he eats and sleeps well, and has hardly any cough. I feel satisfied that, whatever his ultimate fate, he would now have been in his grave had it not been for the treatment which was followed. On my advice he is looking out for a situation abroad."

It will be observed that the tuberculin treatment was not steadily increased, owing partly to a change of assistant during its course, and partly to the stock of tuberculin having temporarily run out. The full dose, too, was not reached, 2½ mg. being the largest injection instead of the maximum of 20 mg., because the patient felt so well as to desire to return home. The improvement, however, was so marked as to show undoubtedly the beneficial effect of the new tuberculin treatment even in pretty advanced cases.

Dr. Service was so pleased with the results in this case that he sent me a somewhat similar one recently, with a request that the same treatment should be tried if thought right. The tuberculin injections have just been commenced, and I bring the patient before you in order that you may examine him for yourselves, and satisfy yourselves of his condition. After the treatment has been carried out I hope to be able to bring him again under your notice, so that you may judge for yourselves how he has fared, although, of course, I cannot

Digitized by Google

guarantee good results any more than in connection with any other kind of treatment. The following is a brief outline of his case:—

A pawnbroker, aged 22, was admitted to the Western Infirmary on 27th February, 1899, complaining of cough and expectoration of a year's duration. His family history is good, except that one brother died at the age of 23 of consumption.

Since the age of 19 he has been intemperate, and seven months ago, while in Ireland with two friends, he was drunk every night for a week on end. He was always healthy, however, until three years ago, when he was laid up in consequence of a severe chill after a bicycle ride. During this illness, which lasted for a fortnight, he had high fever, and complained of great weakness and profuse sweating at night. He seems to have recovered from this attack, and remained well until a year ago, when cough set in, which gradually became more troublesome, and was soon accompanied by expectoration, at first clear and frothy, but gradually becoming thicker and muco-purulent. Latterly he has been losing flesh and feeling very weak, and about a month ago he spat up a small cupful of blood.

On examination of the chest the right lung presented no evidences of disease, but the whole of the left was more or less involved. Over the upper lobe, especially in front, there were flattening, defective movements, dulness and resistance on percussion, increased vocal fremitus and resonance, and coarse moist râles in abundance. There were also dulness and râles over the whole of the lung, diminishing as the base was approached. The sputum contained tubercle bacilli in small numbers. The digestive organs were fairly healthy, and the urine and temperature normal.

His weights were as follows:—

Eight months before admission, . .	10 st. 7 lb.
27th February, 1899 (day of admission),	8 st. 12 lb.
4th March, ...	8 st. 8¾ lb.
11th March (five days after tuberculin treatment was commenced), . .	9 st. 2 lb.

He had no special treatment from the time of admission (27th February) until 6th March, when he began to take cod-liver oil, and the first injection of the new tuberculin was given, the initial dose being 1 c.c. 1·5000.

From this it will be seen that we are here dealing with a

Digitized by Google

typical case of phthisis, and it will be interesting to see whether any improvement results.

It is held by many that, while the immediate results are undoubtedly good in most cases, relapses are very apt to occur after an interval of weeks or months. That is unfortunately true of many diseases, and especially so of tubercular affections. But the main reason for the relapses after tuberculin is, in my opinion, that the exciting cause (the tubercle bacillus) is alone attacked, while the predisposing causes are left untouched. The tuberculin ferrets out the tubercular lesion, inflames the part and destroys the tubercle bacilli, and it therefore exerts its influence locally, so to speak. But it has no beneficial influence upon the constitution, but rather the reverse, especially if it is not skilfully used, so that it is necessary to combine the tuberculin treatment with measures calculated to improve the general health, such as good food, pure air, cod-liver oil, tonics, &c.—*i.e.*, to change the nature of the soil which is favourable to the growth of the tubercle bacillus.

II.—CASE OF PERNICIOUS ANÆMIA TREATED BY ARSENIC AND BONE-MARROW.

By DR. T. M'CALL ANDERSON.

D. M'P., a policeman, aged 48, was admitted to the Western Infirmary on 21st January, 1899, complaining of weakness and shortness of breath of three months' duration. He stated that he had always previously been healthy, and his family history was good. His parents both died at the age of 68, he had four sisters and one brother alive and well, while one sister had died of "consumption" at the age of 19.

He was on night duty at the onset of his present illness, and in his rounds he had many stairs to climb. He noticed about three months ago that he became very breathless after a night's work, and often felt so faint that he had to sit down and rest upon the steps. His feet also sometimes swelled a little; but this may have been due to varicose veins, from which he suffered. He rapidly lost weight, and his friends noticed that he was very pale and jaundiced in appearance.

On his admission he was found to be somewhat emaciated and extremely anæmic. He became breathless upon exertion, but did not otherwise suffer from dyspnœa. His appetite

Digitized by Google

remained good and his bowels regular. The lungs were healthy and the urine normal. There was slight enlargement of the liver. A loud venous hum was present on the left side of the neck; but no murmur, either hæmic or organic, was to be heard over the heart. He had been troubled with dimness of vision for a few days before entering the infirmary; but upon ophthalmoscopic examination the fundi were found to be normal, and there were no retinal hæmorrhages. His normal weight was 12 st. 7 lb. A month before admission it had fallen to 11 st., and on 21st January it was 10 st. 7½ lb. An examination of the blood made on the same day showed that the hæmoglobin had fallen to 25 per cent, and the red corpuscles to 1,500,000 per c.mm. The red corpuscles were found to vary in size, and many microcytes were met with, as well as dumb-bell and flask-shaped forms.

The patient was put upon bone-marrow, in doses of half an ounce thrice daily, and this was continued until the 16th of February, after which arsenic was given in gradually increasing doses. A progressive improvement was noted. There was a gain in weight from week to week, and on the 11th of March the weight was 12 st. The condition of the blood was also improved, the hæmoglobin on the 9th of March amounting to 58 per cent, and the corpuscles to 3,000,000 per c.mm. The patient left the infirmary practically well.

III.—CASE OF GASTRORRHAPHY FOR DILATED STOMACH.

By MR. A. E. MAYLARD.

J. C., æt. 55 years, a stableman, was admitted into the Victoria Infirmary on 6th September, 1898, under the care of Dr. Ebenezer Duncan. He stated that his illness commenced about two years before, by more or less pain in his back. At the time he thought he was suffering from lumbago, but the pain soon shifted to the epigastrium, where it has remained continually ever since. He describes it as of a burning, gnawing character, located just below the ensiform cartilage. Its presence is very constant here, though sometimes passing through to the back. It is somewhat aggravated by hunger, and frequently relieved by the ingestion of food. He never vomited, but suffered considerably from flatulency. The bowels have always been costive, and required aperients. To his knowledge he has never passed blood.

An examination of the abdomen revealed some pain on pressure over the affected area, and the stomach appeared to

Digitized by Google

be considerably dilated, extending an inch below the umbilicus and laterally as far as the left axillary line. The heart manifested a marked mitral murmur. The other organs appeared healthy. His weight is 9 st. 4 lb. While in the medical ward treatment of the usual kind was adopted, embracing lavage; and as no improvement followed, he was transferred to the surgical ward.

On 9th November, 1898, the patient was admitted into Ward III, under the care of Mr. Maylard, with the object of having an exploratory operation performed upon the stomach.

Operation.—The abdomen was opened above the umbilicus, and a digital examination then made by sweeping the fingers over the surfaces of the stomach and around the pyloric region, but nothing of the nature of adhesions or other complications was detected. The stomach was then partially withdrawn through the parietal wound and its anterior wall incised for about an inch in the long axis of the organ, and about midway between its two curvatures. The pyloric orifice and the interior of the stomach were examined with the index finger, but here also the result was negative. No constriction or thickening was felt at the pylorus, the apex of the finger being easily admitted into the opening. The internal lining of the organ, as far as it could be investigated, also appeared normal; no thickening or ulceration. The exploratory incision was then closed by a continuous Lembert suture, and steps taken to lessen the size of the dilated stomach. After withdrawing the organ to as great an extent as possible, a longitudinal fold in the anterior wall was folded in, and the two curvatures approximated and secured by a series of interrupted Lembert's sutures. The stomach was then returned, and the abdominal parietal wound closed by three separate rows of stitches—a peritoneal, aponeurotic, and skin. The operation lasted fifty-five minutes.

He continued to vomit after the operation small quantities of blood-stained mucus, and complained of some pain in the epigastrium. About 1 A.M. the next morning he vomited about 8 oz. of pure blood. From that time onwards till 10 A.M. it was computed that he brought up about 35 oz. of blood. His condition when seen by Mr. Maylard at 10 A.M. was to indicate free hæmorrhage into the stomach from the gastric wound, and the necessity of the immediate removal of the patient to the theatre. An anæsthetic was administered, and the exploratory incision in the stomach at once exposed by the removal of all stitches. It was then found that some small veins were bleeding at the margin of the incision. These

Digitized by Google

were secured, the edges of the mucous membrane stitched together, and a continuous Lembert applied to the peritoneal coat. The gastric plication was resutured, and the abdominal wound reclosed.

The median-cephalic vein was opened, and three pints of hot saline solution injected. The pulse and respiration at once commenced to improve. Before leaving the theatre the patient's stomach was thoroughly washed out until the returning fluid was no longer blood-stained. From this period onward the conditions were those of continued improvement until he left the hospital on 18th January for the convalescent home. He reported himself on 10th February, having put on flesh, taking his food well, and complaining only of occasional "stitchy" sensations about the region of the wound. He felt none of his old pain and discomfort. His weight on 15th March was 11 st. 4 lb., a gain of 2 st. since admission.

(Report of the case as taken by Dr. Charles Fleming and Dr. James M'Haffie.)

IV.—CASE OF MODIFIED CRETINISM.

By DR. ROBERT KIRK.

Dr. Kirk, Partick, showed a case of modified cretinism in a boy 20 years and 6 months old, whose height was 4 ft. ½ in., and weight 5 st. 1 lb. He stated that the lad's father and mother were both dead, and that the latter had probably been the subject of myxœdema, as she was for some years believed to be dropsical, her daughter-in-law informing him that her eyelids were like bags of water, especially in the morning, while a daughter remarked that she had a skin like wax and cheeks like roses. She dropped down dead suddenly when going about the house on her usual duties, an interesting fact in view of the liability to death from syncope in the case of those undergoing thyroid treatment. He founded the diagnosis of cretinism in the present case on the dwarfed stature, the broad squat build, slow compressible pulse, occasional subnormal temperature, &c., and regarded it as an instance of what French writers called *La forme fruste du myxœdème atrophique.*

Perhaps the most interesting aspect of the case lay in certain negative features which it presented; the lad was bright and intelligent, although a good deal below average capacity, and there was not the slightest drawl or slowness in his speech, which, on the contrary, was rapid and fluent.

On these and other grounds Dr. Duncan, Dr. Hinshelwood,

Digitized by Google

and others expressed doubts as to the case being one of cretinism at all; but Dr. Kirk remained confident in his opinion, and hoped that he would have the opportunity of showing the result of thyroid treatment on some future occasion, and this will be looked forward to with some interest.

V.—CASE OF SYNCHYSIS SCINTILLANS ASSOCIATED WITH SYPHILITIC DISEASE OF THE EYES.

By DR. JAMES HINSHELWOOD.

The patient, 51 years of age, is a married woman who has had four children, and four years ago a miscarriage. Ever since her miscarriage, she has been greatly troubled with severe headaches and pains in the limbs. These headaches and pains have always been much worse at night, and particularly for the last year, during which she has rarely had a good night's rest.

On 11th February she came under my observation at the Eye Infirmary, complaining of increasing failure of vision in the right eye during the last three weeks. On ophthalmoscopic examination the fundus could only be seen very dimly, owing to a dust-like opacity of the vitreous; but hyperæmia of the disc could be made out, and a diffuse opaqueness of the retina, especially in the neighbourhood of the disc. The appearances were those of a syphilitic chorio-retinitis. On movement of the eye upwards and downwards a shower of shining particles were seen to diffuse themselves through the vitreous, falling to the bottom when the eye became stationary. The vision in the left eye had been defective for several years. This defect was found to be due to a deposit of exudation and iritic pigment on the central lesion of the surface of the lens, due to a former attack of iritis.

The patient was put at once upon energetic specific treatment, with the rapid disappearance of her headaches and limb pains, from which she is now completely free. Her vision in the right eye has greatly improved, the dust-like opacity of the vitreous has disappeared, and you can now see the fundus with normal distinctness. The brilliant shining particles can now be seen more plainly floating on the vitreous with every movement of the eye, like a veritable shower of gold. These brilliant particles are known to consist chiefly of cholesterine crystals, and sometimes also of groups of tyrosine needles. As at the same time the vitreous is fluid, this condition has been called synchysis scintillans from the glittering caused by

Digitized by Google

the reflection of light from the surfaces of the crystals. These crystals are generally supposed to be the result of fatty and other degenerative changes, which take place in the elements of the vitreous as a result of senile degeneration.

In the third volume of Norris and Oliver's recent *System of Diseases of the Eye*, page 382, we find the statement that "sparkling synchysis is found only as a senile change, never before the age of 60, and usually over the age of 70." The case under consideration destroys the validity of this statement. Our patient is nine years short of 60, and is a well-preserved woman, without a grey hair, and showing no signs of senile degeneration. There is, however, sufficient cause in the syphilitic chorio-retinitis for a profound alteration in the nutrition of the vitreous, and hence for the degenerative changes resulting in the synchysis scintillans.

This case is therefore of special interest as showing the presence of this condition at a comparatively early age, apart from signs of senile degeneration, and also from its association with syphilitic disease of the eye, which would interfere with the normal nutrition of the vitreous, and therefore affords a probable explanation of the condition seen in this case.

MEETING XII.—7TH APRIL, 1899.

The President, DR. G. S. MIDDLETON, *in the Chair.*

I.—ON THE RADICAL CURE OF MASTURBATION.

BY DR. CAMPBELL CLARK AND MR. H. E. CLARK.

Dr. Campbell Clark, in conjunction with Mr. H. E. Clark, read a paper on the above subject, which will be published in the *British Medical Journal.*

II.—DEMONSTRATION IN *X*-RAY RESEARCH.

BY DR. JOHN MACINTYRE.

Dr. Macintyre gave a demonstration of recent work in *x*-ray research, showing some experiments, lantern slides, and instruments.

Digitized by Google

MEETING XIII.—21ST APRIL, 1899.

The President, DR. G. S. MIDDLETON, *in the Chair.*

I.—PATIENT OPERATED UPON FOR CHRONIC BILATERAL PREPATELLAR BURSITIS.

BY DR. ARCHIBALD YOUNG.

Mrs. P., aged 42, a charwoman. Since the age of 24 the patient has been more or less constantly employed as a charwoman—scrubbing shops and offices.

FIG 1.
This shows well the relative sizes and positions of the tumours.

Five years ago a swelling appeared over the right patella, followed soon by a similar, but smaller, swelling over the left. At first painful and fluctuant, these soon became indurated and painless. Not long after there appeared smaller swellings at a lower level, one over each patellar ligament, just above the tibial tubercles. These followed a similar course to the larger ones, and soon became indurated. After the first year

Digitized by Google

none of the tumours gave much trouble, except in so far as their actual bulk rendered them a hindrance in kneeling. On examining the knees, the tumours were found to be related, in the ordinary movements of the limbs, only to their deep attachments, the skin moving freely over them.

FIG. 2.

Operation.—On 29th December, 1898, patient was anæsthetised by Dr. G. N. Turner, and I was assisted by Dr. Peter M'Bryde. The tumours were removed by elliptical incision, the superficial skin being, except in the case of the smaller mass on the left side, removed along with them, in order to prevent redundancy of the resultant cicatrices. In dissecting the smaller tumours away from their close attachments to

Digitized by Google

patellar ligaments, a good deal of trouble was experienced. The wounds were kept dry throughout, and, being treated aseptically, healed by first intention, leaving simple linear cicatrices. Patient was back at work within a few weeks, and kneeling as much as ever without any discomfort.

The following are the measurements of the tumours after removal:—

RIGHT.		LEFT.	
Larger, .	6 cm. × 6 cm. × 4 cm.	Larger,	4·5 cm. × 4 cm. × 2·5 cm.
Smaller,	3 cm. × 3 cm. × 1·5 cm.	Smaller,	3 cm. × 2·5 cm. × 1 cm.

The *minute histological structure* of the tumours was apparent upon examination of a series of microscopic sections. Of the larger tumours the peripheral portions showed a very dense, scantily-nucleated, fibrous tissue concentrically disposed, and, passing towards the more central parts, this gradually gave place to a less fully organised tissue consisting of a very loose network of fibrin, with a quantity of leucocytes in its meshes, and exhibiting a tendency, as one passed from the centre outwards, to assume a striation similar to the external fibrous tissue. At several parts, clear evidences of active organisation were noted. Though less definitely marked, the mode of formation of the smaller tumours was regarded, on an examination of sections, to be of the same nature as in the larger ones just described.

The reasons for bringing forward this case were—

1. The remarkably large size of the prepatellar bursæ.
2. The clear demonstration of the process of their formation obtained by examination of above microscopic sections.
3. The somewhat doubtful origin of the smaller tumours, presumably also bursal in nature, the occurrence of such over lower ends of patellar ligaments being rather uncommon.

Attention was directed to the fact that in ordinary kneeling the tibial tubercles, and lower parts of the patellar ligaments, are always in contact with the ground, while the patellæ are so only when the angle between thigh and leg (popliteal angle) approaches to a right angle; and it was pointed out that, in spite of this, the occurrence of bursal swellings was rare, except over site of the large prepatellar bursæ. The explanation was sought in the theory that, in this particular case, the smaller swellings might probably have resulted from extrusions from a bursa pretty constantly found between patellar ligaments and head of tibia, the occurrence of other bursæ, as, *e.g.*, one met with occasionally over the tibial

Digitized by Google

tubercles, not being regarded as adequately accounting for the smaller masses in this case, having regard to the exceedingly intimate connection existing between them and the ligaments around which they were very closely adherent. So closely did they embrace the ligaments, that the work of dissecting them free was of some difficulty.

Had they originated in connection with pre-existent bursæ superficial to the ligaments, they would not have had, in all probability, so intimate a connection with the ligaments, while remaining so free from superficial attachments to the skin, &c.

It was suggested that further elucidation of the anatomical relations of bursæ, in the neighbourhood of the knee, was to be sought for before a definite statement could be made as to the exact origin of the smaller tumours.

Photographs and a series of microscopic sections were exhibited in illustration of the case.

II.—REMARKS UPON THE OPERATIVE TREATMENT OF INFECTIVE THROMBOSIS OF THE SIGMOID SINUS FOLLOWING CHRONIC PURULENT OTITIS MEDIA: RECORD OF A CASE SUCCESSFULLY TREATED.

BY DR. ARCHIBALD YOUNG.

The operative treatment of infective thrombosis of intracranial sinuses is one even now of only recent date, and although there have been already recorded not a few cases of successful treatment, there seems to me to be still justification for the following record.

The case was brought before the Glasgow Medico-Chirurgical Society upon 21st April, 1899, and as it suggested several interesting clinical, anatomical, and pathological questions, I have ventured to record it at some length.

At the very outset one is met with the difficulty so commonly experienced in such cases—viz., the somewhat obscure diagnosis. Although in thrombosis of the *cavernous* sinus there exist, as a rule, definite enough aids to diagnosis, it is, unfortunately, not so in thrombosis of the *sigmoid*, or, generally, of the *lateral* sinus; and the irony of this is apparent when it is remembered that, even yet, the prognosis in the former is of the gravest nature, while, given early recognition and prompt operation, the prospects of recovery in the latter are now not nearly so remote as they were.

Of course, when an extensive disintegration of the septic thrombus has occurred, and systemic dissemination of the

Digitized by Google

infective material has begun to take place, there appear very soon unmistakable signs of pyæmia—generally shown chiefly in the formation and development of septic pulmonary foci, with resultant abundant foul-smelling sputum (often blood-tinged), frequently repeated rigors, violent temperature variations, and, often, local tenderness and œdema, over mastoid, course of lateral sinus, and down course of internal jugular vein. These signs, with others indicative of constitutional disturbance of a grave nature, are, however, in the very nature of things, of only late appearance in the history of any given case, practically all being explained as indications of a general pyæmia. It may, indeed, be at once admitted that, given any considerable constitutional generalisation of infective material, the value of operative treatment becomes, at least, debatable.

There remain, however, for consideration the doubtful cases, *i.e.*, those in which signs of pyæmia are not at all conclusive; where, *e.g.*, as in the present one, any lesions in the lungs remain of a strictly limited type; where, if infective foci exist, they are of a most minute type, never attaining to any considerable proportions.

The question as to how far infective foci in the lungs can be recovered from is still one admitting of discussion, but it seems at least probable, that foci of a minute size are capable of resolution, and, therefore, it is all the more incumbent upon the surgeon to give even the most unlikely cases every possible chance. The clinical difficulty which arises in the diagnosis of such doubtful cases is certain to complicate the situation, for in the absence, as has been said, of distinct pyæmic signs, the involvement of the sinus is often exceedingly difficult to demonstrate prior to operation. It is all the more important, then, that in all operations upon the mastoid region for any of the sequelæ of chronic purulent otitis media, at least where the smallest doubt exists, a careful investigation of the sinus groove ought to be made, especially if there exist signs of erosion of bone on the posterior wall of antrum. I believe it to be worth while, also, to draw attention to another point bearing upon this, viz., that, as a rule, it is not at all necessary to delay the complete surgical treatment of the part after the opening of an external mastoid abscess.

The superficial tissues admit of very thorough treatment immediately free incision has been made, and it is matter of common experience that the tissues can be very easily rendered aseptic prior to the deeper exploration that must be carried out. Not infrequently one hears of mastoid abscesses in connection with a purulent otitis being treated by simple

Digitized by Google

incision, and, at anyrate, a considerable time allowed to elapse before the complete eradication of the septic accumulation in the middle ear, mastoid cells, and antrum. Such a method of treatment is, I believe, to be strongly condemned, for the risk of serious intracranial mischief is not by any means negatived by the appearance of pus externally. The latter may be regarded in the light of a danger signal, certainly not in the light of a safety valve.

It is important, therefore, that even in apparently simple cases the sinus ought to be carefully and systematically investigated, and that at as early a stage as possible.

As to the actual surgical procedure to be adopted in any case of infective sinus thrombosis, it may at once be acknowledged that, *in advanced cases*, with the clot extending well towards the torcular herophili and down the jugular, nothing but a most extensive clearing out of the sinus contents and of the upper part of the jugular—a preliminary ligation of the latter well below the thrombus having been carried out—is likely to avail.

It is *in earlier cases*, where the clot is still limited to the sigmoid sinus, and specially to the knee of the latter, that there is not a little difference of opinion as to the best method of treatment.

In the case recorded here it will be noticed that the method followed was that of a simple incision through sinus wall, the laying open of the knee of sinus, and the gentle evacuation of the semi-fluid *débris*. No attempt to completely dislodge the whole thrombus was made, and for these reasons. Firstly, any attempt to clear out the whole mass would probably result in the dissemination of a quantity of infective material into the blood-stream, and I deemed it advisable to leave, between the general blood-stream and the infective centre, the protective layer of what we may, I think, regard as non-infective thrombus, rather than in a more radical effort at clearance run the risk of any further systemic infection than might already exist. Secondly, I believe that, by a mere opening of the sinus, with the provision of easy drainage, there is little risk of the products of disintegration of the clot doing any further harm; while, if the more radical method of ablation of the sinus be adopted, a firm packing of the sinus, or, at least, a firm compression of its walls, such as is necessary to control the free hæmorrhage which results, is the very thing to prevent the harmless escape of any septic material which may escape notice, and so inevitably systemic absorption is sure to continue. Besides, it is hardly to be

Digitized by Google

expected that the disturbance of a septic mass, such as is involved in any radical effort at removal, is likely to pass without some infective *débris* being carried into the general blood current.

In the present case I had every reason to congratulate myself upon the result of the method adopted. The simple incision, evacuation of semi-fluid contents, introduction of a light gauze drain, with daily dressing and renewal of this, served every purpose, and there was the added advantage of freedom from anything like free hæmorrhage such as a more extensive interference with the sinus would have involved.

It but remains for me to call attention to *two* points of not a little importance in the treatment of such cases. It will be observed in the full report of the case that, on incision being made, two erosions were met with. The interest attached to these lies in the fact that the larger one led directly into the sigmoid groove, and if one had attempted to follow the directions given in more than one text-book, viz., to use this as a guide to the antrum—it was in position of so-called squamo-mastoid foramen—a rather serious mistake would have been the result. The importance of using only the certain anatomical guide of the post-supra-meatal triangle in opening into antrum is easily apparent.

Again, as to the actual treatment of the cartilaginous meatus and the bony posterior wall of the external meatus, it will be seen that the method adopted in this case is different from that usually followed. Most operators even yet rest satisfied with opening into antrum, evacuating the infective contents as freely as possible, and preserve not only cartilaginous meatus intact but also the small bridge of bone forming the posterior wall of the bony meatus. It has long seemed to me that there was for this no adequate reason, and one could not obtain, if that were adhered to, at all free access to what should be then the common cavity of middle ear, antrum, and mastoid excavation. By slitting up the posterior wall of cartilaginous and carefully cutting through the bony posterior wall, the external meatus was also thrown into the one common cavity, and a much more satisfactory, as well as more rapid, filling up of the parts with healthy granulation tissue was the result.

The idea of preserving such a useless bridge of tissue, and the attempt at irrigation of the narrow, circuitous channel between external meatus and mastoid excavation through middle ear, tympanic attic, and antrum, should, I believe, be now discarded.

Digitized by Google

I may say that, in a subsequent case, I followed the same method of treatment, and in it also I was convinced that one obtained in that way a much more speedy and satisfactory repair than, according to the older practice, could have been looked for. In neither case has any sinus posteriorly or any meatal discharge persisted, the healing process being apparently complete.

George M'K., æt. 2½ years, was brought to the Central Dispensary upon the 9th January, 1899, and seen first of all by Dr. Robert K. Currie, who, recognising the necessity for surgical interference, referred the child to me.

The immediate cause of the child's mother seeking medical advice was the appearance, six days before, of a swelling above and behind the left ear, and a marked alteration in the child's general condition—drowsiness, alternating with fitful restless periods—during the forty-eight hours immediately preceding date of application at the dispensary.

Notes of history of case, as obtained on above date.—The child suffered from measles six months previously, and about the tenth day of illness there was observed a discharge from the left ear, which discharge was never very abundant, and, though varying in quantity from time to time, never entirely ceased until three weeks ago. The discharge, to judge from the mother's statement, seems to have been throughout practically free from any offensive odour.

From the time of the cessation of the discharge, three weeks ago, the mother observed a marked change in the child's general state. He was less bright and lively than usual, his appetite less satisfactory, and once or twice his motions were diarrhœic and exceedingly foul-smelling. At night he usually slept fairly well, but would now and again start up, crying aimlessly, apparently without any external exciting cause. The mother thought that he seemed to be suffering pain.

During the attack of measles, and for some little time after, he had a slight cough; but this had quite passed off until a week or two since, when it once more began to give trouble. For the week immediately preceding his being brought to the dispensary it had been persistently troublesome, but no expectoration had been put up; whether any may have been swallowed the mother could not say. Six days ago—*i.e.*, on the 3rd January—the swelling above referred to made its appearance above and behind the left ear, day by day increasing notably in size, and extending also considerably

Digitized by Google

forward. The accompanying constitutional change soon became aggravated. Pain seemed to be experienced in and around the ear; the child showed great restlessness and fretfulness, occasionally, however, falling into a deep sleep, from which he would suddenly awaken with a cry.

He took little food; what little he did take he usually vomited, and his bowels were with difficulty moved by castor oil. The cough was very troublesome, and sometimes a paroxysm ended in an attack of vomiting.

Notes of condition on same date.—When I saw the child he appeared, as he lay in his mother's arms, to be in a condition, if not of semi-coma, at least of intense drowsiness. He could be roused, but with considerable difficulty. He

FIG. 1.

(From a water-colour drawing).

presented a feature which one becomes familiar with in cases of meningitis, tubercular or purulent, but even more constantly in cases of cerebellar abscess, viz., a persistent, almost spasmodic, opening and closing of the mouth—half-sigh, half-yawn. His pupils were equally dilated, but contracted to light stimuli. There seemed to be no paralytic condition, either of face or limbs. The complexion was pale, and somewhat earthy in hue. The tongue was coated and dry, covered with a brownish-yellow fur. The most notable objective phenomenon was, of course, the large diffuse swelling above and behind the left ear. This swelling was not sharply delimited from the surrounding scalp, but shaded insensibly into the level around. Roughly, it may be said that its upper and posterior borders coincided, respectively, with the temporal ridge on the parietal

Digitized by Google

bone, and the posterior margin of the mastoid process. Anteriorly, it shaded off very gradually into the level scalp. The effect was characteristic (Fig. 1, p. 330). The whole external ear was, as it were, raised bodily from its close bony relations, and projected downwards, outwards, and forwards. Palpation revealed, in spite of the tense temporal fascia and periosteum, the presence of deep-seated fluctuation, the swelling being due to a very large sub-periosteal parieto-squamo-mastoid abscess.

There was no noticeable tenderness on deep pressure over the upper part of the left internal jugular vein, though the upper part of anterior and posterior cervical triangles presented some œdematous swelling. Over the abscess itself the skin was pale, glazed, and tense. Percussion of the skull caused no pain, and the note obtained was of no diagnostic value.

The *temperature* (axilla) registered 100·2° F. The *pulse* was 140 to 150 per minute, weak, and irregular in rhythm. *Respirations* were 46 to 50 per minute. Even during the comparatively brief period of examination the cough was noticed to be very troublesome, but was not accompanied by expectoration.

The chest was at this time only hurriedly examined, but neither then nor at any subsequent examination was evidence of any gross lesion of a local septic character obtained.

Ears.—In the *left meatus* was a quantity of partially dried purulent secretion, with an intensely foul odour. The membrana tympani was practically gone, represented only by a congested turgid-looking fringe inferiorly and posteriorly. The middle ear contained viscid discharge and a certain quantity of granulation tissue. This material had the same foul odour as the discharge in the meatus. At the time of examination no bare bone was felt, either on tegmen tympani or upon the posterior wall.

In the *right ear* nothing abnormal was found.

Eyes.—The fundi were not examined on this date; but next day, while the child was still under the influence of the anæsthetic after the operation, a satisfactory view of both fundi was obtained. Beyond some undue injection of the left disc, little abnormal was noted.

Family History.—The child was the sixth (youngest) of a family of six, of which number the second and third are dead, the former dying at age of 6 months after a short illness of six days subsequent to vaccination, the latter dying at age of 3 years and 2 months from scarlatina. The other members

Digitized by Google

of the family have always enjoyed exceptionally good health. I have seen all, and they are apparently strong, sturdy children, the eldest about 12 years old. The mother and father both come of a healthy stock, but the father seems to suffer from some cardiac affection.

Diagnosis.—It was, of course, obvious that there was here a very large sub-periosteal mastoid abscess, and the evacuation of this was urgently called for. It was, however, equally obvious that this was not the full extent of the mischief.

A definite, or in all respects satisfactory, diagnosis was difficult to arrive at.

The spasmodic movement of the jaw, the drowsiness, the dilated pupils, added to the history of checked discharge, raised in one's mind at once the possibility of intra-cranial abscess, and if such an abscess were present, its seat was in all probability in cerebellum, the points in favour of such a localisation being—(1) the persistently recurring masseteric spasm; (2) the absence of any definite paralytic or pressure signs, such as abscess in the temporo-sphenoidal lobe so often implies; (3) the failure to find, by speculum or probe, any necrosed or denuded bone or actual erosion in the roof of the middle ear, such as one is usually able to observe in cases where intra-cranial extension has occurred in the direction of the temporo-sphenoidal lobe.

On the other hand, (1) the frequency of the pulse, abnormally rapid, instead of slowed—as one usually finds in intra-cranial abscess; (2) the elevated temperature—the elevation, although slight, being in such marked contrast to the striking lowering of the temperature frequently met with in abscess; and (3) the hurried respirations. These points taken together threw considerable doubt upon the existence of an intra-cranial abscess, cerebral or cerebellar, at least uncomplicated.

A localised meningitis might have been quite consistent with the presence of most of the above-mentioned signs, and the presence of an abscess accompanied by a limited meningitis was regarded as possible.

Anything like a generalised septic lepto-meningitis was out of the question, however, considering the absence of any facial paresis, and having regard to the usual route by which, in young children, intra-cranial infection terminating in such a condition usually travels inwards. Any meningitis, if present, was almost certainly a localised condition.

What impressed one, however, more perhaps than anything, was (1) the irritating cough; (2) the history of the aggravation of this during the few days immediately preceding; (3) the

Digitized by Google

peculiar pallor, combined with a slight earthy hue, of the complexion; and (4) the slight œdematous swelling over the upper part of both anterior and posterior cervical triangles. These points, despite the absence of any history of definite rigors, strongly suggested that an erosion of the posterior wall of the antrum had probably taken place into the sigmoid groove, and that there was probably present a localised thrombosis at the knee of the sigmoid sinus.

It was thought to be possible that, in addition, there might be some extension of the septic process backwards into the cerebellar fossa around the borders of the sinus, with, perhaps, the formation of a limited abscess.

Operation.—At 5 P.M. the following evening (10th January, 1899) the child seemed less drowsy than on the previous day, but he had passed a restless night, considerable spells of deep sleep alternating with periods of unrest, when he seemed to suffer pain at the back of the head, and occasionally started up moaning. His *temperature* registered 101·6° F.; the *pulse*, 120 per minute; and *respirations*, 48. Cough was persistent, and the odour of the breath unpleasant.

Dr. Thomas Kay very kindly administered the anæsthetic (chloroform) and I was assisted by Mr. Robert Gilchrist.

The left side of the head was carefully shaved and submitted to the usual routine procedure requisite for aseptic treatment. The lobule of the ear was then drawn forward by the assistant, and an incision made behind the ear in an obliquely vertical direction for about 2½ inches, right down to bone. This incision at once gave exit to a large quantity of brownish-yellow pus, having an intensely fœtid odour, the periosteum being raised from the bone over the mastoid, squamous portion of temporal, and a considerable extent of parietal. There was, therefore, no delay in raising and retracting the periosteum to locate the recognised site for further operation. The pus and *débris* of disintegrated tissue having been cleared away as thoroughly as possible, the margins of the wound were retracted, and the mastoid was more closely examined.

In the situation of the post-supra-meatal triangle an aperture large enough to admit a fine probe was found to exist, and further back was a larger aperture, about a quarter of an inch by one eighth of an inch in size, very close to the position of the squamo-mastoid foramen.

These superficial erosions were of considerable interest, inasmuch as the former was found to lead into antrum and the latter into the sigmoid groove, really thus exposing the sinus externally.

Digitized by Google

The ordinary steps of a mastoidectomy were followed out carefully. A gouge was employed throughout, and the bone, being comparatively soft, was easily manipulated. Following the former of the two above-mentioned erosions, little difficulty was experienced in reaching the antrum, and from that the tympanum. Both of these cavities were found full of broken-down, foul-smelling granulation tissue and pus. The malleus and incus were found embedded in this *débris*, and were removed. The small bridge of bone forming a portion of the posterior wall of the bony auditory meatus was carefully removed, and the cartilaginous meatus being split along this wall, the cavities of external auditory meatus, tympanum, antrum, and the artificial excavation opening into the latter, were thus thrown into one.

The posterior wall of the antrum was found eroded into the sigmoid groove. This erosion and the one externally were converted into one aperture by gouging away the intervening bone, and the sinus for an extent of about half an inch was thus freely exposed. It was found clothed in granulation tissue, a somewhat thick pus covering the latter and issuing from underneath the margins. The sinus and granulations were black and unhealthy looking, and the former, to the finger, felt hard.

It seemed probable that there was, at least, a localised thrombosis at the knee of the sigmoid, *i.e.*, just where the sinus bends downwards and inwards towards the jugular fossa and bulb. The granulation tissue and excessively foul-smelling pus were cleared away thoroughly, but the sinus, despite its ominous appearance, was not then interfered with.

With a view to the possibility of exploration of the cerebellum itself becoming necessary, in the event of signs of abscess declaring themselves more clearly, the bone immediately posterior to the sigmoid groove was carefully gouged away, and the cerebellar dura laid bare over an area of somewhat oval form, and half an inch by three-quarters of an inch in extent. The dura over the tegmen tympani et antri was also laid bare over a somewhat similar area, as the bone in that situation was found distinctly eroded, despite the failure to observe this prior to the operation. The dura in this position was found slightly reddened, but otherwise unaltered. The cerebellar dura at margin of sinus and over the part exposed was red and thickened.

Having thus thoroughly cleared the middle ear and antrum of their fœtid septic contents, and having freed the sinus from the granulations clothing it, these parts were rendered, as

Digitized by Google

nearly as possible, aseptic by the introduction of gauze soaked in 1 to 20 carbolic lotion for several minutes, the meatus being also treated in this way.

The superficial tissues involved in the external abscess had also been freely treated with carbolic lotion, and they, with the middle and external ear, antrum, &c., were carefully dried with aseptic gauze. The middle ear and antrum were packed with iodoform and boracic acid (1 to 4), and the same mixture rubbed into the superficial tissues. These cavities were then firmly packed with iodoform gauze from the wound posteriorly, and the sinus, temporo-sphenoidal and cerebellar dura similarly protected. A narrow strip of iodoform gauze was introduced through the external meatus into the common cavity of middle ear, external ear, and antrum. No sutures were used, and no ligatures were required to check hæmorrhage. The whole cavity exter-



FIG. 2.

Note.—The records on this chart only date from the morning after the first operation. *Previous records.*—9th January, 100·2° F.; 10th January, 101·6° F.

Digitized by Google

nally was packed with iodoform gauze, and an external dry dressing of sterilised gauze applied.

The child took chloroform well, but the pulse at the end of the operation, which lasted about an hour and a half, was very weak, and at times difficult to count.

The *prognosis* seemed to be highly unfavourable, both Dr. Kay and myself regarding the prospects of recovery as exceedingly remote.

The *immediate effect of the operation* was, as shown by foregoing chart, a rapid drop in the child's temperature—101·6° F. before operation, it was 98° F. next morning, and 98·4° F. the following evening. The day following, *i.e.*, during the second day after the primary operation, it showed a distinct tendency upwards. The cough was still very troublesome; and it was observed when dressing the part on the day immediately following the operation (11th January), as also upon the 12th, that the sinus, where it was freely exposed, still presented the same ominous appearance. On the evening of the 12th, therefore, when dressing the case with the assistance of Dr. Arthur D. Ketchen, I opened up the knee of the sinus for about three-quarters of an inch and cleared out a quantity of fœtid, dark-greyish, partly disintegrated clot. A small drain of narrow iodoform gauze was introduced into the cavity thus exposed, and the parts externally dressed as before.

Daily dressing was carried out through the next week, and a quantity of foul-smelling *débris* was discharged. The sinus in course of a week or so had quite filled up, however, and the whole wound was then much less frequently interfered with, dressing being thereafter only twice weekly.

The temperature, which, prior to the opening of the sinus, had been showing a distinct upward tendency, continued to rise for two days, its highest register being 102·8° F. It then, however, came gradually down, its downward course marked by certain irregular oscillatory fluctuation, until it practically reached the normal level.

The *subsequent course of the case* was one of almost uninterrupted recovery. From the end of the week immediately following the opening of the sigmoid sinus the cough showed a rapid improvement. It became less and less frequent, and very much less harassing. The wound healed very rapidly, granulating freely and healthily, and is now absolutely healed, the site being marked merely by a linear cicatrix over a distinct depressed area immediately behind the ear. The child's general condition showed a striking improvement. He became bright and lively, clamoured for food (he was, of

Digitized by Google

course, restricted to milk), slept soundly, and seemed quite free from pain. He soon acquired quite a different complexion, put on weight, and now he appears to be in the pink of condition—well nourished and well coloured. There is no discharge from the ear. Hearing is, apparently, little less satisfactory than on the right (unaffected) side.

Note.—The secondary operation on the 12th, viz., the opening up of the knee of sinus, was performed without an anæsthetic.

With regard to the second case, *Dr. Walker Downie* congratulated Dr. Young upon his good result. The symptoms, he thought, pointed to extra-cranial rather than intra-cranial disease, and under the circumstances Dr. Young had done the right operation. He often found it best in young children to leave the sinus alone, but, if it were to be opened, it should be opened freely.

Dr. Nicoll said that palpation was not reliable as a method of determining the condition of the sinus. All cases of septic mastoid disease should be operated upon as early as possible. Many only came under the surgeon's notice when there was a generalised pyæmia.

Dr. Edington, discussing the first case, said that in the dissecting-room he had frequently met with a small bursa in the situation of the lower one described. He asked if the upper bursa lay over the patella, or partly over the ligament.

Dr. Barlow thought that the lower bursa must have been below the ligament.

Dr. Young replied that the smaller bursa lay over the lower part of the patellar ligament, while the upper extended to the upper margin of the patella.

III.—CASE OF INTESTINAL OBSTRUCTION—VOLVULUS AND INTERNAL HERNIA—SUCCESSFULLY OPERATED ON.

By DR. RITCHIE THOMSON.

The relative rarity of recorded cases of successful operation for intestinal obstruction due to volvulus of the sigmoid flexure induces me to bring before the Society the following case, which exhibited a feature of unusual interest in that there was also present a hernia in the recto-vesical *cul-de-sac.*

J. S., a labourer, aged 70, was admitted into Ward 22 of the

Digitized by Google

Glasgow Royal Infirmary on 26th October, 1898, having been sent from Hamilton as a case of acute intestinal obstruction.

Until the onset of his present illness he had enjoyed good health, and never had rupture nor suffered from habitual constipation.

Nine days ago a pain came "like a knife" across the abdomen, a little above the umbilicus, and since then a dull, constant pain, with occasional exacerbations, has continued in that region.

He has had constant desire to go to stool, but has not passed anything, and is quite emphatic that not even flatus has passed for nine days. Vomiting has occurred daily, the pain having been slightly relieved on each occasion.

Physical examination.—The abdomen is uniformly swollen and tense, and gives generally a feeling of increased resistance, which is most marked in the umbilical region. There is no visible peristaltic movement. Percussion yields a tympanitic note all over the abdomen. The right inguinal canal is slightly more patent than normal, but there is no evidence of hernia. Digital examination of the rectum yields negative results, but on trying to give an enema very little fluid can be introduced, and that little is almost immediately ejected. The lungs and heart are apparently normal, and there is little evidence of "shock." The temperature is slightly sub-normal.

On the following morning (27th October) I was asked by Dr. Knox to examine the patient, but was unable to add anything to the information elicited by Dr. Brownridge. The patient had vomited several times since admission, and the distension and abdominal pain had increased, while, in spite of repeated enemata, the obstruction had continued absolute. Operation was therefore decided upon, no diagnosis other than that of complete obstruction of the lower part of the sigmoid flexure having been made.

Operation.—The same afternoon the patient was anæsthetised, and, in Dr. Knox's absence, I performed median abdominal section, with the assistance of Drs. Patrick and Brownridge. The parietes having been divided, and the peritoneum incised, the large intestine immediately presented, and was found to be distended to about three times its average circumference. The distended gut was traced downwards and towards the left, and was felt to become suddenly constricted over the left common iliac artery. Below or to the right of this constricted portion a second similar portion of gut was felt and traced upwards and to the right. This rapidly became distended, and was found to be continuous with the intestine first exposed, so that it was

Digitized by Google

evident that the condition was a volvulus of the sigmoid flexure. An unsuccessful attempt was made to undo the twist without bringing the loop out of the abdomen. On withdrawing the loop from the abdominal cavity it untwisted itself almost spontaneously, and was found to have been rotated from right to left. Towards the end of this manipulation a slight slip was felt, and immediately thereafter a strong fæcal odour was perceived, so that Dr. Patrick and I jumped to the conclusion that the gut had given way at the site of constriction. Careful search showed, however, that the colon was intact and quite free from exudation; but, on following it downwards, instead of it becoming directly continuous with the rectum, the lower part of the sigmoid flexure formed a loop, which was lodged in front of the rectum in a pouch, the orifice of which admitted the tips of two fingers. This loop was withdrawn by gentle traction, and the pouch was then found to admit the fingers for some distance, and to expand considerably just within its orifice. A considerable quantity of flatus was passed at this stage *per viam naturalem.*

To prevent the recurrence of hernia into the pouch, its anterior margin was sutured with catgut to the anterior wall of the rectum, which constituted its posterior boundary. As there was no apparent tendency to retwisting of the upper portion of the sigmoid, no measures were adopted to obviate this contingency. The abdominal wound was united by a single series of interrupted silk sutures including all the layers.

Further course: 28th October.—The patient passed three copious motions and much flatus. The abdomen is quite flat, and the temperature is normal.

18th November—Dressed for the first time. Wound quite healed. Stitches removed. Bowels moved daily.

24th November.—Patient dismissed quite well.

21st April, 1899.—The patient was shown at the meeting. He has been in perfect health since leaving hospital. The abdominal cicatrix has yielded slightly, so that, at its lower end, a slight impulse on coughing can be detected between the recti. There is no actual ventral hernia.

Remarks.—Volvulus is admittedly rarely diagnosed, and this case presents no exception, as I expected to find under chloroform a carcinomatous mass occluding the sigmoid flexure directly or by pressure, and it was only when no such mass could be detected that I decided to perform an exploratory median section instead of colotomy, which I had anticipated.

Digitized by Google

Wahl's pathognomonic condition—a circumscribed area of tympanites corresponding to the location of the twist, and caused by gaseous distension of the twisted loop—was not recognised, and, I believe, was not present, because of the long duration of the obstruction which caused general intestinal distension, and thus masked the special distension which is said to occur in the affected loop as the result of interference with the circulation. In this case the twist was sufficiently tight to occlude the gut lumen at two levels, but was not so tight as to interfere seriously with the venous return, a condition which also accounts for the complete absence of peritonitis, which is so marked and early a complication in cases of volvulus.

The absence of peritonitis and of venous engorgement explains the ease with which the volvulus was untwisted, and also the fortunate absence of any tendency to recurrence of the rotation.

The most interesting feature of the case appears to me to be the co-existence of the hernia in the recto-vesical *cul-de-sac.* This struck me as so unusual that, after removing the sigmoid loop from the pouch, I asked Dr. Patrick to introduce his finger into the cavity in order to verify my observation. The orifice of the "hernial sac," for such it was, was constricted, but not to the extent of causing strangulation of the contained intestine.

With regard to the anatomical anomaly or pathological change by which the ordinary wide-mouthed recto-vesical pouch, usually containing small intestine, was replaced by a deep pyriform fossa with a comparatively narrow orifice and containing sigmoid flexure, I can offer no very adequate explanation, and I shall greatly appreciate any expression of opinion from the members of the Society. In my by no means exhaustive survey of the literature of internal hernia, I have discovered no description of a similar condition. The lateral boundaries of the fossa were, I think, the posterior false ligaments of the bladder, and the presence of an enlarged prostate may have so raised their anterior attachments as to form an unduly deep pouch; but in the complete absence of any sign of old peritonitis, I cannot explain the mesial approximation of these ligaments anteriorly to a degree sufficient to form the well-defined crescentic anterior boundary of the pouch.

In the female, incarceration of intestine in the pouch of Douglas is easily understood, and I have, with the assistance of Drs. Howat and Riddell, operated for acute obstruction

Digitized by Google

due to such a cause, but in that case pelvic peritonitis and pelvic abscess were present, and the small intestine supplied the strangulated loop.

The hernia, I believe, was present in this case before the volvulus, and its lumen having become blocked, it gave rise to the volvulus, of which, according to Grawitz, the immediate cause is an accumulation of intestinal contents above a constricted portion of intestine.

To account for the presence of the lower portion of the sigmoid flexure in the hernial sac while the upper part formed the volvulus, I must revert to the old description of the flexure, which, I take it, was in this case a Sigma bi-loop, and not an Omega loop. The distal segment of the Sigma formed the hernia; the proximal loop became rotated and constituted the volvulus; and the meso-sigmoid, having a broad attached base, and not being of undue length, permitted sufficient rotation to cause complete mechanical obstruction, but not true strangulation.

IV.—CASE OF ABDOMINAL SECTION FOR ACUTE INTESTINAL OBSTRUCTION.

By Dr. Thomas Kay.

Mrs. T., æt. 30, was first seen by me on Friday, 23rd December. About six hours previously she had been seized by a severe abdominal pain, followed almost immediately by sickness and vomiting. The bowels had moved the day previously, but since the onset of the pain there had been no movement of the bowels, and the patient was not conscious of having passed flatus. On examining the abdomen no distension could be observed, but the patient complained of pain on palpation to the right of the umbilicus.

I saw the patient again the following morning. During the first part of the night she had been fairly comfortable, but towards morning the pain and sickness had again set in. No fæces or flatus had been passed. A large enema of oil and water was administered, but only a few small pieces of fæces were evacuated. The patient had numerous enemata of oil and water during the day, administered in the genu-pectoral position, without any result. When I saw the patient again in the evening, she was still complaining of pain, and had occasional attacks of sickness, though not very severe. There was still pain on palpation over the right side of the abdomen, but only slight distension.

Digitized by Google

The patient remained in much the same condition during the night of Saturday, 24th December, thirty hours after the onset of her illness.

On the 25th vomiting was more severe, and distension of abdomen more distinct. Towards evening, forty-eight hours after onset of illness, the vomiting became stercoraceous. The patient was removed to a private nursing home, and I operated at once. I cut down in the middle line, and immediately the peritoneum was opened a coil of distended bowel presented. This had a dark, purplish colour. On following this upwards, I almost at once came upon the obstruction. When the abdominal wound had been slightly enlarged upwards, this was seen to be caused by a fibrous band stretching from mesentery to distal part of lumen of bowel; behind this band a knuckle of bowel was jammed. In trying to bring the parts nearer to the surface, the attachment to mesentery gave way. The collapsed bowel distal to the obstruction was at once seen filling out. I applied a ligature, and removed the other end of the fibrous band as close as possible to the bowel. The abdominal cavity was carefully examined to make sure there was no other obstruction, but none was discovered. Numerous hard enlarged glands could be felt in the mesentery. When the patient came out of chloroform she vomited a large quantity of stercoraceous material; afterwards there was no more sickness. Early next morning she passed flatus, and a few hours afterwards had a motion. She continued to make satisfactory progress, and left the home perfectly well at the end of four weeks.

A microscopical examination of the band revealed ordinary fibrous tissue.

V.—SEVERAL CASES OPERATED ON FOR SPINA BIFIDA, WHICH PRESENTED UNUSUAL FEATURES.

VI.—A CHILD—AND PHOTOGRAPHS OF A SECOND CASE—WITH NOTES OF A THIRD—WHERE THE LESION WAS ORIGINALLY DIAGNOSED AS SPINA BIFIDA, BUT IS PROBABLY CONNECTED WITH THE NEURENTERIC CANAL.

BY DR. J. H. NICOLL.

It is intended that particulars of these cases shall be embodied in the matter of a paper on the subject of "Spina Bifida" in the forthcoming volume (vol. ii) of the *Glasgow Hospital Reports*, till the issue of which their publication is deferred.

Digitized by Google

VII.—CASE OF DOUBLE CLUB FOOT WITH CLUB HAND, ILLUSTRATING THE REMEDIAL EFFECTS OF OPERATIVE TREATMENT.

BY DR. J. H. NICOLL.

B. A., æt. 15 months, sent to me at the Children's Hospital Dispensary in October, 1898, by Dr. J. Kennedy. Double

FIG. 1.

tenotomy was done on both feet. This resulted, after repeated manipulations under chloroform and fixation in plaster of Paris, in partial reduction only of the deformity. At the end of three months the condition of the feet was as

Digitized by Google

shown in Fig. 1 (p. 343), which shows also the club hands, of which the left is the more marked, and a congenital facial paresis.

At that date I performed a double cuneiform tarsectomy, removing a wedge of bone from each foot, which consisted

FIG. 2.

largely of cuboid and neck of astragalus. The result, three and a half months later, is as you see (Fig. 2).

I have presented the case for two reasons. First, on account of the interesting combination of club hand with club foot; second, as having been treated throughout as an out-patient. I am in the habit of treating nearly all cases of

Digitized by Google

tenotomy and tarsectomy in children as out-patients, and have done a number of these operations at the Children's Hospital out-patient department with uniformly good results, as regards aseptic healing. In the matter of the after-treatment, in such cases as require subsequent manipulation or application of talipes "boots" or plaster, these cases are in the same position as cases operated on as in-patients, which, ultimately, for the after-treatment, become out-patients.

VIII. — VESICAL CALCULI REMOVED BY LITHOTOMY FROM PROSTATIC PATIENTS, AGED 78, 80, AND 85 RESPECTIVELY.

By DR. J. H. NICOLL.

These three cases operated on within the past three months are remarkable in one respect only — that of age. They were all ordinary cases of prostatic retention, with regular use of catheter, in whom cystitis or hæmaturia had recently developed owing to, or aggravated by, the growth of phosphatic calculi.

Mr. R., æt. 78, I saw in Saltcoats on 14th January in consultation with Dr. D. Campbell. He was then a "catheter prostatic" of two years' standing, and had been suffering for three days with continuous serious hæmaturia. He was brought to the St. Elizabeth Nursing Home in Glasgow, and the following day I removed, by the suprapubic operation, this sharp phosphatic stone. He made an excellent recovery, and is now going about again free from hæmorrhage. Whether the operation is to have any effect in reducing the size of the enlarged prostate remains to be seen.

Mr. M., æt. 80, I saw in consultation with Dr. A. Tindal on 3rd January. He had been a "catheter prostatic" for four years, with recurrent attacks of hæmaturia, and had for several months suffered in addition from great vesical irritability and an exceedingly fœtid condition of urine, which Dr. Tindal had been able partially to relieve by washing out the bladder daily. He was removed to the Queen's Park Nursing Home, and I removed this phosphatic stone by the median perineal operation, inserting a large perineal tube for drainage. The patient died from exhaustion three weeks later.

Mr. A., æt. 85, I saw in consultation with Dr. Stark on 16th March. He was then a "catheter prostatic" of over six years, and had for some days suffered from constant straining and desire to pass water. He was taken to Miss Baker's Nursing Home, and I removed this phosphatic calculus by the

Digitized by Google

suprapubic operation. He is now going about again in much increased comfort, though, as in the case of Mr. R., it is too early as yet to tell what effect the operation is to have on the prostatic enlargement.

Cystitic irritation and hæmaturia are frequently developed in prostatic cases apart from calculus formation. Cystoscopic examination and sounding are of less use in such cases than in many other classes of vesical ailments. In many cases the cystoscope or sound cannot be passed into the bladder, while in others in which they pass the bulky prostatic mass carries the window and light, or the beak of the sound, so far up and forward into the interior of the viscus that examination of the important area, the post-prostatic pouch, is impossible. In a considerable number of such cases, therefore, exploratory cystotomy offers the only means of detecting the stone.

IX.—CASE OF EXOPHTHALMIC GOITRE IN WHICH THE THYROID WAS EXCISED UNDER COCAINE.

By Dr. J. H. Nicoll.

Mrs. H., æt. 45, seen in consultation with Dr. Wylie on 15th March, 1899, suffering from palpitation, throbbing in head, debility, and dyspnœa, becoming extreme on exertion. The patient was anæmic, the eyeballs slightly protruded, and the pulse ranged from 90 to 110. The carotid and temporal arteries exhibited markedly exaggerated pulsation. There was a moderate enlargement of the thyroid—both lobes and the isthmus.

The patient was admitted to the M'Alpin Home, where, with cocaine employed as a local anæsthetic by hypodermic injection, I removed what constitutes the specimen—viz., the whole of the enlarged right lobe and isthmus, with rather more than half of the enlarged left lobe.

The patient made a good recovery, and is already benefited to the extent that the dyspnœa on going upstairs is markedly less, and the pulse slower by from fifteen to twenty beats per minute.

The use of local anæsthetics alone in excision of the thyroid has lately been advocated by surgeons on the Continent. General anæsthetics in such cases frequently lead to dyspnœa of an alarming kind. This produces two evil results—(*a*) hæmorrhage, severe and troublesome; (*b*) such a degree of laryngeal spasmodic obstruction as to render tracheotomy necessary. Tracheotomy not infrequently leads to septic

Digitized by Google

infection—by way of the tube in the air-passage—of the large spaces left after removal of the thyroid lobes, with ultimate infection of the cellular planes of the neck, and death from pyæmia.

MEETING XIV.—12TH MAY, 1899.

The President, DR. G. S. MIDDLETON, *in the Chair.*

I.—THE OPERATIVE TREATMENT OF SQUINT.

BY DR. FREELAND FERGUS.

Dr. Fergus read a paper on the operative treatment of squint, and showed lantern specimens.

Dr. Rowan said that he was not inclined to go the length of giving up tenotomy altogether, although one came more and more to do advancements. He asked what result Dr. Fergus had had in cases where there had never been binocular vision. At what age could binocular vision be established in them; and if it could not, could the strabismus be cured?

Dr. Fergus replied that it was not uncommon to have difficulty in restoring binocular fixation, especially in tenotomies. If one eye were of much less visual power than the other, it was almost impossible to get good binocular vision. Systematic exercises with stereoscopic pictures were of great value.

II.—NOTES ON A CASE OF CARCINOMA CERVICIS: VAGINAL HYSTERECTOMY BY DOYEN'S CLAMP METHOD.

BY DR. BALFOUR MARSHALL.

Mrs. H., age 49, came to the Glasgow Royal Infirmary in August, 1898, complaining of irregular uterine hæmorrhage during the previous month.

History.—She has had eight children, all at full term, the last born twelve years ago.

Menstruation ceased twelve years ago, at the age of 37, since which time she had been healthy till the beginning of July, 1898, when she noticed a slight discharge of blood from the vagina. This hæmorrhage recurred at intervals during

Digitized by Google

July, and was marked by the presence of blood-clots and, later, by a bad odour. She had noticed no leucorrhœal discharge, and was quite free from any pain. Her appetite was good, and otherwise she felt perfectly well.

Examination showed an enlarged and slightly nodular cervix. The os was somewhat patulous, and admitted the finger-tip sufficiently to feel an irregular, rough, hard surface, which bled readily. The whole uterus was freely movable, and, so far as touch could tell, there was no affection of the neighbouring cellular tissue or glands.

Diagnosis.—Epithelioma of the cervical canal.

Operation.—On 29th August, 1898, a total vaginal hysterectomy was performed by Doyen's method. The carcinomatous surface was first thoroughly scraped and douched.

An incision through the mucous membrane was made on the anterior half of the cervix close to the junction of cervical and vaginal mucosæ. The pouch of Douglas was next opened by clipping through the posterior fornix with curved scissors. The bladder was then stripped upwards from the cervix, while the uterus was pulled well downwards. The next step consisted in splitting the uterus anteriorly as far as the isthmus, the utero-vesical pouch being opened at the same time. This splitting of the uterus greatly facilitates the pulling of the fundus into the vagina, while hæmorrhage is controlled by traction on the uterus. A Doyen's clamp was then fixed on each broad ligament, as far from the uterus as possible without risking any injury to the ureters. For further safety, a smaller pair was clamped close to the first pair on each side, the uterus being then cut away by scissors.

In an uncomplicated case such as this the operation is easy and rapidly performed, and much superior to the method by ligature. The total operation, exclusive of curetting, took twelve minutes.

After-history.—The clamps were removed in forty-eight hours, and the patient rose on the eleventh day. She was sent home on the twelfth day, and was able to resume household duties a week later.

Later history.—I examined the patient on 9th May, 1899, eight and a half months after operation. She has enjoyed good health, and has been quite free from pain. There is no inclination to vaginal prolapse. There is, however, just above the vaginal scar, a hard nodule of hazel-nut size, which I consider must be taken as evidence of early recurrence. This nodule must be watched, and, if necessary, a second operation undertaken for its removal should it prove to be a recurrence.

Digitized by Google

Remarks.—The statistics of the after-histories of vaginal hysterectomies for carcinoma are so contradictory as regards good or bad results that it is most important that all cases operated on should be carefully watched, where possible, for several years afterwards. I refer more especially to cases, such as the above, which are seen so early as fully to justify a hope that they are curable by hysterectomy.

In the above case the operation was performed seven weeks from the onset of the first symptom, which was one of hæmorrhage. The uterus was freely movable, and could be pulled down to near the ostium vaginæ, and the parametrium seemed unaffected, yet within nine months of operation there is evidence of recurrence.

Dr. Halliday Croom, in his presidential address[1] before the Edinburgh Obstetrical Society last November, gave a record of fifteen cases which makes painful reading. He says these fifteen cases "fulfilled all the conditions requisite to justify hysterectomy with expectation of success," yet "every one of them died within the year," and "with greater suffering than if they had been left alone." This is a terrible indictment against simple hysterectomy, as the lives of these patients were actually shortened by operation. Dr. Croom's ability and success as an operator are so well known that his statistics are worthy of careful note, and he is deserving of thanks for bringing such a record before us, dismal though it be. As he rightly points out, these are in marked contrast to what one reads of in German statistics, and he refers to the remarkable results of Leopold, who records that out of 76 cases, 72 were free from any recurrence in from one to five and a half years after operation.

In a recently published paper by Landau,[2] there is a record of 123 cases. He operates by means of clamps *per vaginam*, and removes not only the uterus, but the broad ligaments as well. In 48 of these cases the operation was performed over five years ago, and 13 are still well. That gives the satisfactory record of 27 per cent free from recurrence five years after operation. It may be that Landau's better results are due to a more extensive removal of the parametrium, this being only possible by the clamp method. The great importance of an extensive removal of the connective tissue round the uterus even in limited carcinoma is now well recognised, and this has led some of the American gynæcologists to abandon vaginal hysterectomy, and operate *per abdomen.*

[1] *British Medical Journal*, 19th November, 1898, p. 1557.
[2] *British Medical Journal*, 29th May, 1899, p. 1269.

Digitized by Google

Howard Kelly[1] states that for the last three years he has preferred removing the uterus from above, as it allows of a wide exsection of the connective tissue and glands.

Ries and Clark, in America, are now operating *per abdomen*, and make a most extensive removal of all the uterine ligaments as far as the pelvic wall, the ureters being first dissected out and turned aside. They record fifteen cases thus operated on, with three deaths, but sufficient time has not yet elapsed to tell whether even this extensive removal of tissue will prevent recurrence.

Landau, in his paper (mentioned above), recommends the systematic removal of recurrences in the scar after vaginal hysterectomy. He quotes a case of Rosenstein's, where the patient was well three years after the removal of the recurrent growth *per abdomen*. Landau has had one similar case, where the growth recurred about two and a half years after vaginal hysterectomy. He removed the recurrent growth successfully *per vaginam*, although the operation was a difficult one. He does not, however, mention if the patient is still well after an interval of over a year.

Carcinoma uteri is, unfortunately, so common that any improvement in the method or extent of operating is much to be desired, and it is a matter of much importance whether we should operate *per vaginam* or *per abdomen* with great removal of tissue, but this can only be decided by carefully recording the after-histories of all cases operated on.

The question of prophylaxis is also an important one. Carcinoma cervicis is most prone to occur in parous women who are the subjects of laceration of the cervix with ectropic endocervicitis and catarrhal patches (erosions). These conditions should have careful attention, especially in women over 35, and it is a question if it might not be well to remove the inflammatory tissue and repair the cervix in all such cases as a means of reducing the risk of malignant disease.

III.—TWO CASES OF MALDEVELOPMENT OF THE GENITAL TRACT IN MARRIED WOMEN—ONE DUE TO OCCLUSION OF THE LOWER THIRD OF VAGINA WITH RETAINED MENSES (CRYPTOMENORRHŒA), THE OTHER TO ABSENCE OF UPPER TWO-THIRDS OF VAGINA, UTERUS, AND ADNEXA.

BY DR. BALFOUR MARSHALL.

It has till recently been generally accepted that the whole of the vagina is developed from Müller's ducts, and that, when

[1] *Operative Gynecology*, 1898.

Digitized by Google

congenital, atresia of the lower third existed. This was due either to the non-extension of the ducts downwards, so as to open into the cloaca, or to some inflammatory condition leading to occlusion.

Berry Hart has published a research[1] which throws a different light on the etiology of cases of atresia in the genital tract, and makes them more easily understood. He has shown that the vagina in its upper two-thirds only is formed from the ducts of Müller, whereas the lower third is developed from the urino-genital sinus. The upper two-thirds or Müllerian part of the vagina is formed by fusion of the lower portions of the two ducts of Müller, and ends below at the eminence of Müller, which also marks the upper limit of the urino-genital sinus. A little below this eminence the Wolffian ducts open into the sinus, and at their ends two epithelial structures are formed called the Wolffian bulbs. These bulbs coalesce and give rise to the hymen, while they block that portion of the urino-genital sinus which lies above it and goes to form the lower third of the vagina. The epithelial cells of the coalesced bulbs also undergo proliferation, and pass up into the Müllerian portion of the vagina.

The vaginal canal is later rendered patent by the central cells breaking down, while the opening in the hymen is similarly formed, aided by involution from below.

The two cases of maldevelopment which I now bring before the Society show entirely opposite conditions. The first was a case of cryptomenorrhœa with hæmatokolpos and hæmatometra. The occlusion involved the lower third of the vagina, and therefore that portion developed from the upper part of the urino-genital sinus. The atresia was probably due to persistence of the Wolffian bulbs. All that portion of the genital tract—upper two-thirds, vagina, uterus, and tube—formed from the ducts of Müller was normal, so that, when the menstrual function was established, retention of the menses took place, leading to great distension of the vagina, and, to a slight extent, of the uterus as well.

In the second case the patient has a normal vulva and hymen, but her vagina is represented by a shallow canal only three-quarters of an inch deep, while the upper part of the vagina and uterus are absent. This is therefore a case of maldevelopment due to absence of these structures formed by Müller's ducts, whereas the lower third of the vagina and hymen, which arise from the upper part of the urino-genital

[1] *Journal of Anatomy and Physiology*, October, 1896; *Edinburgh Obstetrical Transactions*, vol. xxii, 1896-97.

Digitized by Google

sinus and Wolffian bulbs, are present. Menstruation is, of course, impossible in this case owing to the absence of the uterus.

The following gives the detailed histories of the two cases in question:—

1. *Case of cryptomenorrhœa—Hœmatokolpos—Hœmatometra.*—Mrs. F., age 23½, married three months, came to the Royal Infirmary on 19th January, 1897, complaining of entire absence of menstruation and dyspareunia.

History.—Patient is a tall well-nourished woman, and gave a history of having first noticed a swelling in her right inguinal region five years ago. At first it sometimes disappeared, but during the last three years she noticed it getting gradually larger; and it was often painful, especially on exertion. For four years past she has had pain in the back at intervals. The mammæ were sometimes tender and swollen. She has been troubled with constipation and occasional burning pain on micturition. Three months ago she was married, but all attempts at coitus caused much pain, and were followed by frequency of pain on micturition.

Examination of the abdomen showed an ovoid tumour corresponding in position and size to a 6½ months' pregnant uterus. It had a tense, elastic feel, and lay more to the right side, but could be moved from side to side. The corpus uteri could not be felt.

The vulva was normal, and the hymen could be readily distinguished. The lower part of the vagina was completely occluded by a thick septum, which bulged slightly. Recto-abdominal bimanual examination showed the pelvis almost completely filled by a rounded, tense, elastic tumour directly continuous with the abdominal tumour previously felt.

Diagnosis.—Hæmatokolpos due to occlusion of lower third of vagina.

The patient was sent to Ward 30, where on 20th January Dr. Kelly evacuated the contents of the tumour through a crucial incision, a very large quantity of thick, treacle-like, dark fluid escaping.

Patient was dismissed well on 24th February, three and a half weeks after operation.

On examination after operation I found the uterus had been distended sufficiently to admit two fingers, so that in this case there was hæmatometra as well.

After-history.—The patient has proved unusually fertile, as I examined her in April, 1899, little more than two years

Digitized by Google

after operation, and found her between two and three months pregnant for the third time. During the last two years she has been delivered of two full-term children.

Note.—This case is interesting from the comparative freedom of pain in spite of the great distension of the vagina. It was really the interference with marital relations that caused the patient's mother to bring her to hospital.

2. *Case of absence of upper two-thirds of vagina and uterus with adnexa.*—Mrs. C., age 23, married two years, came on 6th March, 1897, complaining of entire absence of menstruation and of dyspareunia. She was otherwise in good health, and free from pain. She was quite devoid of any sexual feeling. To external appearance she was well developed as regards mammæ and vulva. The vagina, however, formed a small pouch only three-quarters of an inch deep. Recto-abdominal bimanual examination could discover no evidence of a uterus and adnexa, nor of the upper two-thirds of the vagina; so that, if present, at all, they could only be mere fibrous cords. There was no tumour in the pelvis to suggest the presence of retained menstrual fluid. Of course, nothing could be done for this patient.

Dr. Carstairs Douglas agreed with Croom, in regard to the former paper, that patients died more rapidly, and in greater pain, than if left alone.

Digitized by Google

Digitized by Google

INDEX OF SUBJECTS.

—o—

ABDOMINAL disease, difficulties in diagnosis, 1.
— sections, 75.
Appendix, excision of, 27.
— perforation, 292.
Atrophy of deltoid, 32.
— progressive muscular, 188.

BLADDER, intra-peritoneal rupture, 77.
— tumour of, 83.
Brain, glioma, 63.
— tumour, recovery from, 160.
— tubercular tumours, 248.
Broad ligament, cysts, 118.
Bulbar paralysis, 188.
Bursitis, bilateral prepatellar, 322.

CEREBELLAR abscess, 206.
Cervical glands, excision, 133.
Choroiditis, tuberculous, 156.
Cirrhosis of liver, hypertrophic, 39,
Club foot, double, and club hand, 343.
Cœliotomy, vaginal, 274.
Colon, tumour and colo-enterostomy, 294.
Cretinism, modified, 319.
Cyanosis in pulmonary conditions, 175.
Cysts of broad ligament, 118.
Cyst, congenital mesenteric, 42.
— dermoid ovarian, 44, 109.
— ovarian, 109, 111.

DELTOID, atrophy of, 32.
Dermography, 191.
Dexiocardia, 156.
Disseminated sclerosis, 183, 190.

ENTERIC ulcer, perforation and successful laparotomy, 285.
Erythromelalgia, 199.
Exophthalmic goitre, eye-symptoms, 222.
— excision of thyroid, 346.

FEMUR, extra-capsular fracture, 288.
Finger-nail, hypertrophy, 253.
Frontal sinusitis, 299.

GASTRIC arteries, "pore-like erosion, 238.
— ulcer, perforated, 74.
— rupture and suture, 259.
Gastro-enterostomy, 293.
Gastrorrhaphy, 317.
Glioma of brain, 63.
Goitre, cystic, 213.
— endemic in Lanarkshire, 227.
— exophthalmic, 95.

HÆMOCYTOMETER, Oliver's, 73.
Hæmoglobinometer, Oliver's, 73.
Heart disease and Schott treatment, 166.
Heart in morbus cæruleus, 289.
— with single ventricle, 291.
Hemiplegia and diphtheritic paralysis, 192.
Hypertrophy of finger-nail, 253.
— left ventricle, 73.
Hysterectomy, abdominal, 266.
— vaginal, 347.

ILIAC artery, ligature, 77.
Intestinal obstruction, 337, 341.

Digitized by Google

Intussusception and nævoid tumour of intestine, 215.

JAUNDICE, toxæmic, 57.

KIDNEY, injury to, with hæmaturia, 297.
— malformations, 91.

LARYNX, mycosis of, 262.
Lateral ventricle, tapping, 78.
Lens, dislocation, 68.
Letter-blindness, 176.
Leukæmia, splenic, 73.
Ligature of cerebral artery, 23.
Lipoma of mediastinum, 213.
Lithotomy in the old, 345.
Liver, cirrhosis in a child, 250.
— hypertrophic cirrhosis, 39.
— primary carcinoma, 34.
— secondary carcinoma, 37.
— sarcoma of dog's, 292.
Lupus erythematodes and tubercle, 312.
Lymphangeioma, 78.

"MALADIE des tics," 45, 196.
Maldevelopment of genital tract, 350.
Mamma, fibro-adenoma, 126.
Median nerve, resection of, 25.
Meningo-encephalocele, 19, 214.
Mesenteric cyst, congenital, 42.
Morbus cæruleus, heart in, 289.
Mycosis of larynx, 262.
Myopathy, progressive, 51.
Myxœdema, 126, 188.

OSSEOUS defects, congenital, 156.
Ovary, carcinoma, 112.
— cyst, 109, 111.
— dermoid cyst, 44, 109.

PAIN in back, relief of, 224.
Paralysis agitans, 189.
Paraplegia, spastic, 51.
Peritonitis after perforation, 254.
— tubercular, 116.
Pernicious anæmia, 316.
Pharynx, sarcoma, 295.
Polypus, nasal, 289.
Pseudohypertrophic paralysis, 284.
Psoriasis rupioides, 282.
Pylorus, excision, 146.
— stricture and gastro-enterostomy, 293.
Pyosalpinx, 114, 115, 266.

SARCOMA, multiple, 155.
— of pharynx, 295.
— recurrent, 33.
Schott treatment, 166.
Sigmoid sinus, thrombosis, 325.
Sinusitis, frontal, 299.
Sixth nerve, nuclear lesion, 58.
Spina bifida, 144, 145.
— open operation in, 20.
Stethoscope, combination, 33.
Strabismus, treatment of, 95.
Synchysis scintillans, 320.

TABES and Charcot's joint, 283.
— and diabetes, 283.
Thrombosis of sigmoid sinus, treatment, 325.
Tonsil, carcinoma, 221.
Tubal pregnancy, rupture, 265.
Tuberculin treatment, 310.

URTICARIA, factitious, 191.

VARIOLA-LIKE disease in Lascars, 202.
Ventricle, great hypertrophy of left, 73.

WHITE blood corpuscles, 133.
Word-blindness, 62, 225.
Wrist, excision of, 178.

Digitized by Google

INDEX OF CONTRIBUTORS.

ADAMS, J., 214.
ADAMS, J. A., 146.
ADAMSON; R. O., 74.
ANDERSON, T. M'CALL, 282, 310.

BARR, T., 206.
BEATSON, G. T., 126, 133, 213.

CARSLAW, J., 199.
CLARK, CAMPBELL, 321.
CLARK, H. E., 321.
CONNAL, J. G., 126, 221, 289.

DALZIEL, T. K., 33, 42, 181, 285.
DOWNIE, W., 299.

EDGAR, J., 109, 265, 274.
EDINGTON, G. H., 156, 178, 253.

FERGUS, F., 95, 347.

GIBSON, E. A., 44.
GLEN, D., 289.
GRAY, A. A., 262.

HARRIS, D. F., 73.
HINSHELWOOD, J. H., 62, 95, 222, 226, 320.
HUNTER, W. K., 133, 192, 250.

JACK, W. R., 45.
JONES, H. E., 33.

KAY, T., 341.
KELLY, J. K., 109, 266.
KENNEDY, R., 32.
KERR, J. M. M., 118.
KIRK, R., 319.

LOVE, J., 176, 283.

MARSHALL, BALFOUR, 347.
MAYLARD, A. E., 317.
MIDDLETON, G. S., 1, 156, 183.
MONRO, T. K., 58, 160.
M'CALL, J. M., 292.
MACGREGOR, A. N., 144, 155.
M'KENZIE, D., 227.

NESS, R. B., 175.
NEWMAN, D., 83, 293.
NICOLL, J. H., 19, 78, 145, 206, 214, 292, 342.

PARRY, R. H., 288.

RENTON, J. C., 75.
ROBERTSON, A. R., 166.
ROWAN, J., 68.
RUTHERFURD, H., 77, 259.

SOMERVILLE, W. F., 225.
STEVEN, J. L., 51, 63, 73, 238, 254.

THOMSON, RITCHIE, 337.
THOMSON, R. S., 202.

WORKMAN, C., 34, 250.

YOUNG, A., 322.

Digitized by Google

Digitized by Google

Digitized by Google

Digitized by Google

Digitized by Google

Digitized by Google

UNIVERSITY OF MICHIGAN
3 9015 07049 2577

UNIVERSITY
JAN 14 1911
OF MICHIGAN

Digitized by Google

Digitized by Google